

Hypoperfusion volume immediately after recanalization: an accurate early predictor of clinical outcome in acute ischemic stroke patients with large vessel occlusion treated with endovascular treatment

A. Garcia-Tornel¹, M. Ribo¹, N. Rodriguez¹, D. Rodriguez-Luna¹, J. Pagola¹, J. Juega¹, S. Boned¹, M. Muchada¹, D. Anguizola², M. Requena¹, M. Olivé-Gadea¹, A. Tomasello³, D. Hernandez³, C.A. Molina¹, M. Rubiera¹.

¹Hospital Universitari Vall d'Hebron, Stroke Unit, Barcelona, Spain.

²Hospital Galdakao-Usansolo, Neurology Department, Bilbao, Spain.

³Hospital Universitari Vall d'Hebron, Neuroradiology department, Barcelona, Spain.

AS10-051

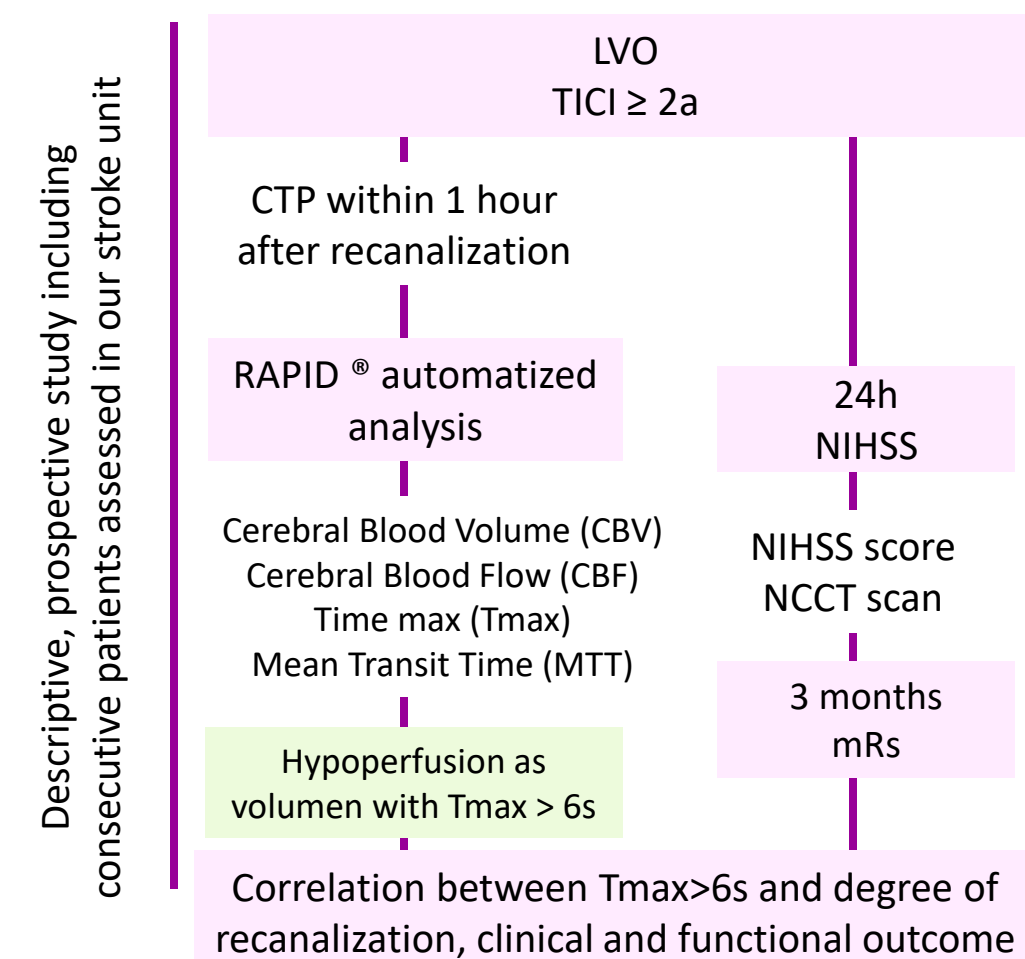
INTRODUCTION

A proportion of patients with acute ischemic stroke anterior circulation large vessel occlusion (LVO) who achieve successful recanalization after endovascular treatment (EVT) do not experience good clinical evolution. Cranial computed tomography perfusion (CTP) immediately after EVT may constitute an accurate predictor after recanalization.

OBJECTIVE

We aimed to evaluate the correlation between CTP parameters after recanalization, recanalization degree, dramatical clinical recovery (DCR, decrease of ≥ 8 points from baseline NIHSS or 24h-NIHSS 0-2) and good functional outcome (modified Rankin score (mRs) of 2 or less) at 3 months

METHODS



CONCLUSION

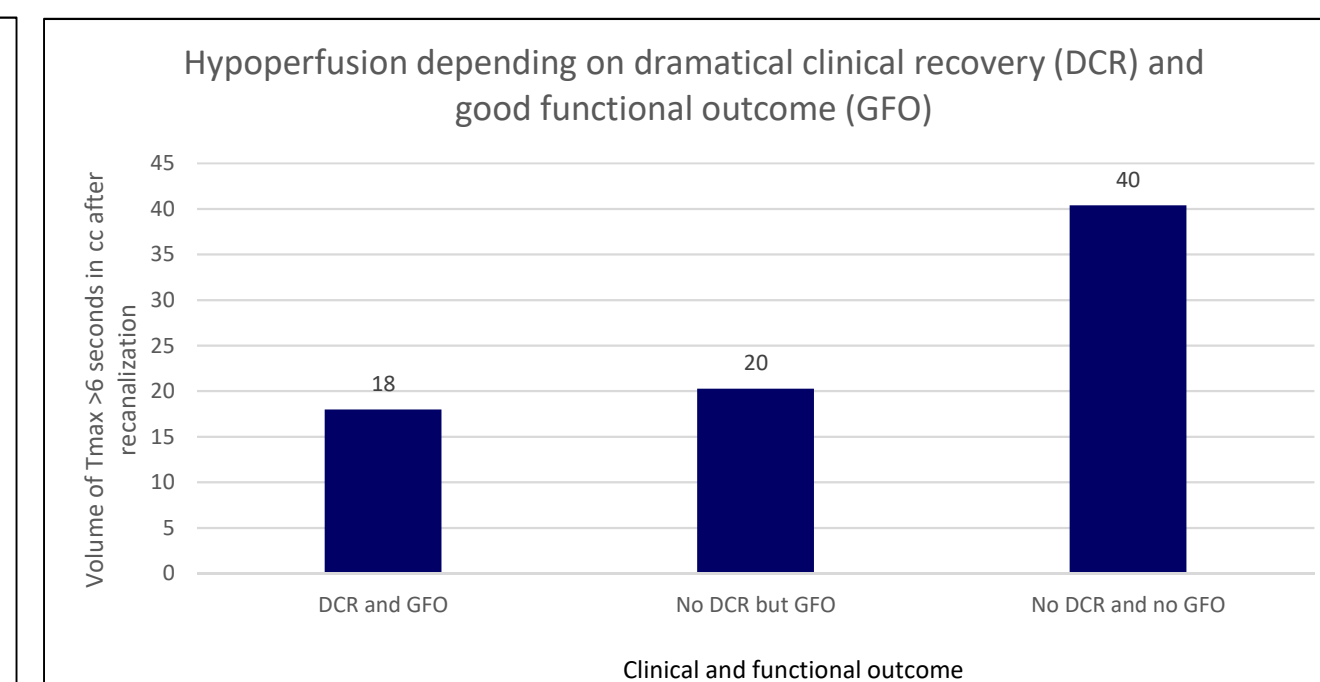
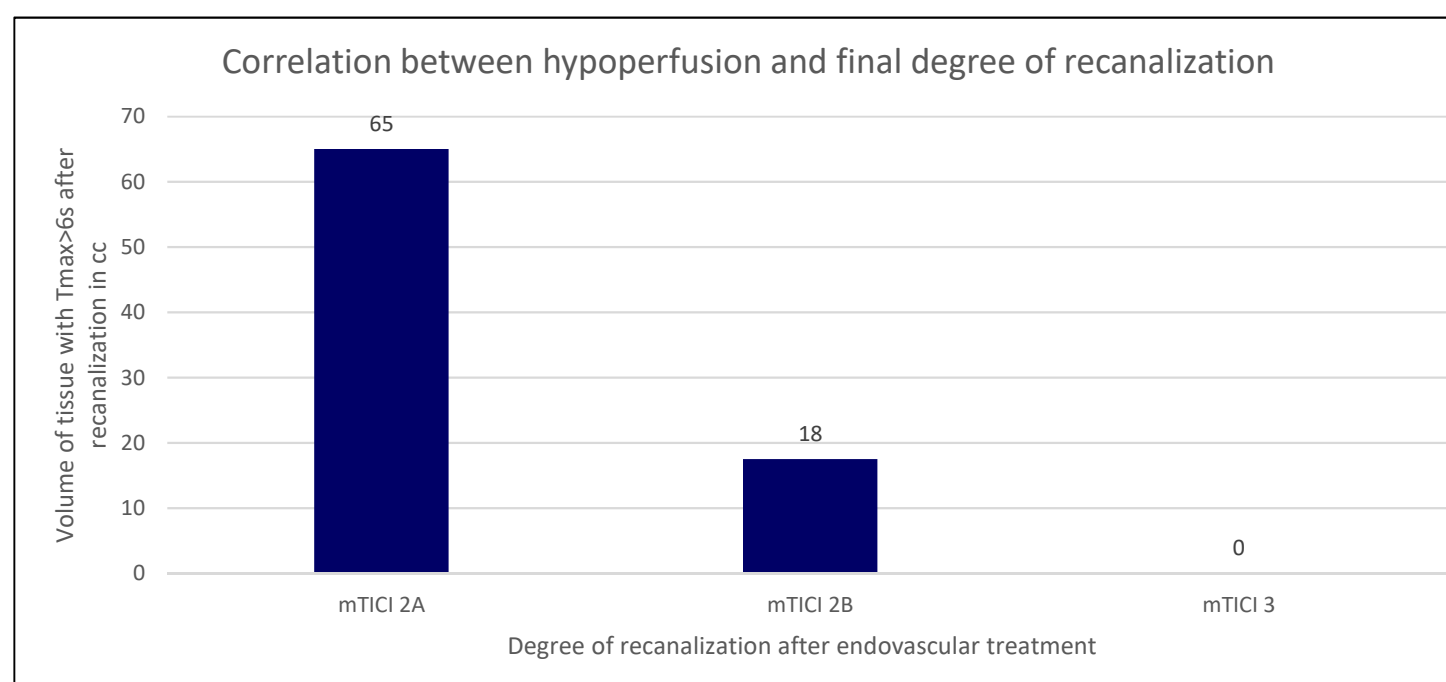
Hypoperfused volume on Tmax>6s after EVT correlated with mTICI degree of recanalization and predicted good functional outcome even in patients without early DCR

RESULTS

Baseline characteristics

Age, years, median (IQR)	74 (63-82)
Sex, women, n (%)	37 (48%)
Hypertension, n (%)	54 (70%)
Dyslipidemia, n (%)	40 (51%)
Atrial fibrillation, n (%)	25 (32%)
Extracranial carotid occlusion, n (%)	16 (21%)
ASPECTS, median (IQR)	9 (8-10)
Vessel occlusion, n (%)	TICA 19 (25%)
	M1-MCA 40 (52%)
	M2-MCA 18 (23%)
Final mTICI, n (%)	2A 7 (9%)
	2B 32 (42%)
	3 38 (49%)
Number of passes, median, IQR	2 (1-3)
Volume of Tmax >6s after EVT, cc, median (IQR)	5 (0-28)
NIHSS, median (IQR)	18 (12-21)
NIHSS at 24 hours, median (IQR)	5 (12-15)
Dramatical clinical recovery, n (%)	45 (58%)
mRs ≤ 2 at 3 month, n (%)	45 (58%)

Outcome analysis



- 77 patients included.
- 45 (58%) patients experienced dramatical clinical recovery (DCR) at 24 hours
- 45 (58%) patients achieved good functional outcome at 3 months
- The hypoperfused volume measured by Tmax delay >6 seconds was the only CTP parameter correlated with degree of recanalization: mTICI 2a, median of Tmax>6s 65; mTICI 2b, median 18cc and mTICI 3, median 0cc, p<0.005.
- 11 patients (14%) that didn't experience dramatical clinical recovery achieved good functional outcome
- Patients without dramatical clinical recovery and good functional outcome (n=12, 14%) had similar volume of Tmax > 6seconds than patients with DCR and good clinical outcome (n=33, 43%) and lower than those patients without DCR and bad functional outcome (n=20, 26%) (18cc vs 20cc vs 40cc, respectively, p<0.01)

References

1. Bang OY, Liebeskind DS, Saver JL, Kim GM, Chung CS, Lee KH, et al. Stunned brain syndrome: serial diffusion perfusion MRI of delayed recovery following revascularisation for acute ischaemic stroke. *Journal of neurology, neurosurgery, and psychiatry*. 2011;82(1):27-32.
2. Gupta R, Sun CJ, Rochestie D, Owada K, Khaldi A, Johnson AK, et al. Presence of the hyperintense acute reperfusion marker on MRI after mechanical thrombectomy for large vessel occlusion is associated with worse early neurological recovery. *Journal of neurointerventional surgery*. 2017;9(7):641-3.
3. Khatri R, McKinney AM, Swenson B, Janardhan V. Blood-brain barrier, reperfusion injury, and hemorrhagic transformation in acute ischemic stroke. *Neurology*. 2012;79(13 Suppl 1):S52-7.
4. Cho TH, Nighoghossian N, Mikkelsen IK, Derex L, Hermier M, Pedraza S, et al. Reperfusion within 6 hours outperforms recanalization in predicting penumbra salvage, lesion growth, final infarct, and clinical outcome. *Stroke*. 2015;46(6):1582-9.