

## Chapter

# Endometrial Histology and Safety on Non-Oral Routes of Hormone Therapy for Perimenopausal/Early Menopausal Women: Transdermal Estrogens and Vaginal Micronized Progesterone

*Manuela Cristina Russu*

## Abstract

The Women's Health Initiative issues, confusions, and misunderstandings regarding women's and medical staff's fears about coronary heart disease; stroke; venous thromboembolism; breast cancer; metabolic, cognitive and mood disorders; and general mortality have driven many attempts to promote other safe regimens for perimenopause/early menopause and midlife health. Perimenopause/early menopause climacteric syndrome may be safely treated with sequential transdermal/percutaneous estrogens and progestogens/vaginal progesterone or continuous transdermal estrogen plus intrauterine system medicated with progestogen/progesterone or with continuous combined transdermal estrogen-vaginal progesterone regimen, when menopause since 3 years. Endometrial safety is assessed in terms of endometrial hyperplasia and carcinoma prevention. Transvaginal sonography, hysteroscopy, and endometrial biopsy at 6/12 months ensure about secretory and atrophy/inactive endometrial aspects as markers for endometrial safety. The majority of endometrial carcinomas depicted after MHT are high grade, not estrogen dependent, developed on an atrophic endometrium. The histologic, genomic, and transcriptomic assessments with immunohistochemistry are diagnoses adjunct for cell proliferation/mitosis and apoptosis presence. Proteins, growth factors, cytokines as PAX2, PTEN and its genetic aberrations, microRNA-binding protein family (IMP, IGF-BP, progesterone dependent), bcl 2, Ki-67, K-ras, p53, p16, and steroid (estrogen and progesterone) receptors are markers for differentiation between benign hyperplasia/endometrial intraepithelial neoplasia, type 1/type 2 endometrial carcinomas, and long-term outcome.

**Keywords:** non-oral routes, hormone therapy, perimenopause, menopause, endometrial hyperplasia, endometrial carcinoma

### 1. Introduction: update on the importance of the hormone treatment in perimenopausal women—non-oral routes of hormone therapy

The menopausal transition is associated with profound dynamic and critical changes of the reproductive tract, and in the hypothalamic-pituitary-ovarian axis, which have been well chronicled and matched with concomitant symptoms regarding the characteristics of menstrual cycle—the most important parameter in the new criteria of STRAW +10 (2012), which starts with the irregularities from stage-3b/-3a in the late reproductive age [1, 2], and of all other organs and tissues of the women’s body, biology and psychology through this time of life. There are ethnic differences in symptoms and hormones that may reflect either basic biologic variations in hormone receptors and actions or the different social milieus that women in different ethnic groups experience [3]. The highly prevalent menopausal symptoms are sufficiently bothersome to drive almost 90% of women to seek out their healthcare provider for advice on how to cope with it. Current medical management of perimenopause should include screening for general health maintenance, avoidance of weight gain—a very important parameter for endometrial health—and a holistic approach to symptoms (Figure 1).

Menopausal hormone therapy (MHT) is indicated for the treatment of vasomotor symptoms and menopausal genitourinary syndrome caused by hypoestrogenism. MHT helps in the prevention of osteoporosis, colorectal cancer, type 2 diabetes mellitus, and possibly coronary heart disease (CHD), and Alzheimer’s disease if started early in the perimenopause or early postmenopause—+1a/+1b (STRAW +10) in the “window of opportunity,” with a positive effect on quality of life and reduction of global mortality.

The initial and quick publication of the results of Women’s Health Initiative (WHI) (2002) led to confusion and fear regarding medical recommendations and women’s use of MHT in conjunction with CHD, stroke, and venous thromboembolism, metabolic disorders, breast cancer, cognitive and mood disorders, and general

Stage	-5	-4	-3b	-3a	-2	-1	+1 a	+1b	+1c	+2
Terminology	REPRODUCTIVE				MENOPAUSAL TRANSITION			POSTMENOPAUSE		
	Early	Peak	Late		Early	Late	Early			Late
Duration	variable				variable	1-3 years	2 years (1+1)		3-6 years	Remaining lifespan
<b>PRINCIPAL CRITERIA</b>										
Menstrual Cycle	Variable to regular	Regular	Regular	Subtle changes in Flow/ Length	Variable Length Persistent ≥7- day difference in length of consecutive cycles	Interval of amenorrhea of ≥=60 days				
<b>SUPPORTIVE CRITERIA</b>										
Endocrine			Low	Variable* Low	↑ Variable* Low	↑ >25 IU/L** Low	↑ Variable Low	Low	Stabilizes	
FSH			Low	Variable*	↑ Variable*	↑ >25 IU/L**	↑ Variable	Low	Very Low	
AMH			Low	Low	Low	Low	Low	Very Low	Very Low	
Inhibin B			Low	Low	Low	Low	Very Low	Very Low	Very Low	
Antral Follicle Count			Low	Low	Low	Low	Very Low	Very Low	Very Low	
<b>DESCRIPTIVE CHARACTERISTICS</b>										
Symptoms						Vasomotor symptoms Likely	Vasomotor symptoms Most Likely			Increasing symptoms of urogenital atrophy

\* Blood draw on cycle days 2-5 ↑ = elevated  
 \*\*Approximate expected level based on assays using current international pituitary standard<sup>67-69</sup>

**Figure 1.** The stages of reproductive aging workshop +10 staging system for reproductive aging in women (adapted from Ref. [1]).

mortality [4]. The analyze of risks of endometrial and colon cancer proved their reduction by MHT in postmenopausal women, being proven by the reduction of colon cancer by HT in postmenopausal women.

Timing of therapy is time since menopause, being more important than women's age. When the benefits are higher than risks, as was proven by previous observational studies, animal models, and new RCT—as Kronos Early Estrogen Prevention Study, Early Versus Late Intervention Trial With Estradiol, Estrogen and Thromboembolism Risk, at near 10 years from the premature closure of both arms of WHI (2002, 2004), when on recorded the “end of an era”. The personalized recommendations of MHT, or tailoring the use of MHT to appropriate candidates, with the ultimate goal of developing a personalized risk/benefit prediction model must take into account clinical and genetic factors, “patient-centered” outcomes as sense of well-being, and/or quality of life.

### **1.1 Non-oral versus oral route for hormone therapy administration: advantages and disadvantages**

Oral HT was and still may be the most commonly used route of administration in the USA and all over the world. Evidence suggests that oral delivery may lead to some undesirable physiologic effects caused by significant gut and hepatic metabolism.

After closure of the estro-progestogen arm of the WHI (2002), some researchers admitted that not all estrogens and progestogens are alike, and alternative drugs, doses, and delivery systems may exhibit better safety profiles than CEE/MPA (with co-multiple and complex studies of the WHI), with no loss of efficacy [5, 6]. The next subchapters will present the transdermal/percutaneous route for estrogens, the vaginal route for micronized progesterone, and the intrauterine systems with levonorgestrel/progesterone for recommendation in menopause transition—early and late perimenopause and early postmenopause from the road of menopause [2]. The best regimen, formula, and dosage—the lowest efficient estrogen dose—will give the opportunity to medical staff to stratify the individual risks and to personalize the MHT indications [7].

#### *1.1.1 Transdermal/percutaneous and nasal routes for estrogens*

Transdermal/percutaneous drug delivery may mitigate some of the undesirable physiologic effects caused by significant gut and hepatic metabolism of oral HT, which still may be the most commonly used route of administration for MHT in the USA and many other countries. Active systems deliver therapeutics noninvasively across intact skin by means of an electric potential (electrotransport) [8], ensuring rapid onset and termination of action, self-administration, and attainment of therapeutic hormone levels with low daily doses, with the disadvantage of the variable intra- and interindividual percutaneous absorption and skin irritation in some patients, when women use patches.

The used estrogen is 17- $\beta$ -estradiol, and women from European countries (Austria, Belgium, France, Germany, Italy, Romania, Spain, Switzerland, the Netherland, and the UK), and Canada used it during the twentieth century's last decade. It is available in multiple formulations—matrix, patches (25, 50  $\mu\text{g}/\text{day}$ ), and non-patches, as topical gel (hydroalcoholic gel containing 0.06% or 0.1% 17 $\beta$ -E2), spray, emulsion, and lotion [9] and recently in the technology of micellar nanoparticles with their unique physical and chemical properties which enable transport of substances directly into the skin [10, 11].

The pharmacokinetic and pharmacodynamic differences between oral and non-oral routes of administration give to medical staff new therapeutic

perspectives for fewer health risks than oral therapy with estrogen, because only systemic therapy controls the moderate and severe climacteric syndrome, and associated to these data on must remember the large interindividual variability in the pharmacokinetics of estrogens. A dose-dependent effect explains why higher dose, longer duration, and residual endogenous estrogens are known risk factors to develop endometrial lesions and uterine bleeding with estrogens, and according to this pharmacokinetic condition, and to ovarian aging and continuous synthesis of endogenous estrogens, the actual recommendation is to use the lowest estrogen dose. The oral estrogens are converted to estrone (E1), and its conjugates, with less estrogenic activity than estradiol (E2), and the extensive metabolism of oral estrogens is inducing a higher ratio of E1 to E2 in the blood stream, which is opposite to the physiological levels in premenopausal women [12], and the formation of other metabolites from conjugated equine estrogens (CEE) used in the WHI was demonstrated to be antiestrogenic or may have unrecognized pharmacologic activity in the human body [13].

The transdermal/percutaneous and nasal administration of  $17\beta$  E2 avoid the first-pass liver metabolism and the significant hepatic stimulation, without supra-physiologic concentrations in the liver. E2 is delivered directly, unmetabolized in the systemic circulation, and the estrogen doses are reduced in comparison to the oral formulation, maintaining a similar E2/E1 *ratio* to that of premenopausal women, by avoidance of gut and liver metabolism. Another peculiarity of transdermal/percutaneous route is the constant blood level of estrogens, without the peaks and troughs inherent to oral estrogens [14]. This quality is providing a more consistent blood level for the control of vasomotor symptoms and sleep disorders in perimenopause [15]. The lowest effective dose which covers treatment goals was considered to be 0.014–0.0375 mg transdermal/percutaneous  $17\beta$  E2 patch, and 50  $\mu\text{g}/\text{day}$  was the assessed dose in the majority of studies for sequential/cyclic regimens and 25  $\mu\text{g}/\text{day}$  for continuous combined regimens.

The newest application method is the estradiol metered-dose transdermal spray (EMDTS) [16], which was proven to ensure a precise dosing, with the maximum of E2 concentration at 18–20 h after application (1 or 2 or 3 puffs), and a stable level of estradiol, estrone, and estrone sulfate on the 7th–8th day of application.

Lower HT doses generally have fewer side effects, as breast tenderness and uterine bleeding, and may have a more favorable benefit-risk *ratio* than standard doses [17]. The UK General Practice Research Database for a nested case-control study showed that the risk of stroke did not increased with low-dose transdermal estrogen ( $\leq 0.05$  mg/day), but increased with oral therapies and higher transdermal doses [18]. The systemic benefits of transdermal estrogens are connected to their bioavailability and metabolic peculiarities—less pronounced effects on hepatic protein synthesis, such as markers of inflammation, coagulation, and fibrinolysis, to lower or no risk of deep vein thrombosis [19], stroke [20], and myocardial infarction, even in thrombophilic patients [21], and lower or no effects on steroid-binding proteins, but more favorable effects on triglycerides [22].

One recent, large observational cohort study of postmenopausal women (45, 112 cases hormone treated, with a mean duration of 5.5 years of HT use) made a multiple statistic comparison of clinical outcomes among users of oral and transdermal estrogen (CEE or E2) therapy, with or without progestogen, in the Women's Health Initiative Observational Study on Menopause [23], and confirmed all the benefits of non-oral estrogens and their beneficial effect on the global index events (GIE) (defined as the time to the earliest of CHD, invasive breast cancer, stroke, pulmonary embolism, colorectal cancer, endometrial cancer, hip fracture, and death from any cause) and stratified the results by duration of HT usage (mean 5.5 years),

age at time of HT initiation (<60 years, 60–69 years, and  $\geq 70$  years), years since menopause, body mass index (BMI), and ethnicity.

The fear of breast cancer is counterbalanced by transdermal estrogens and vaginal micronized progesterone, a fact demonstrated by the figures of the large observational French study E3N Cohort, which showed a small increase in the risk of breast cancer (HR: 1.31; 95% CI: 1.15–1.48), after 5 years of use, but the risk was no longer statistically significant following discontinuation of MHT (HR: 1.15; 95% CI: 0.93–1.42) [24].

### *1.1.2 Low-dose vaginal estrogens*

Low-dose vaginal estrogen preparations as cream, suppositories, and pessaries are recommended for long-term use in symptomatic women as required, and all topical estrogen preparations have been shown to be effective in this context. There is no requirement to combine them with systemic progestogen treatment for endometrial protection, as low-dose or ultralow-dose (10  $\mu\text{g}$  vaginal 17 $\beta$ -estradiol tablets) [25, 26] estrogen preparations do not result in significant systemic absorption, and the risk of endometrial hyperplasia and cancer is low. After 52 weeks of such treatment, a case with hyperplasia without atypia and a case with endometrial adenocarcinoma was discovered, which was considered to be previous to the 17 $\beta$ -E2 vaginal treatment [25]. When the estrogen is estriol—a weak estrogen, with low potency to the estrogen nuclear receptor—the endometrial and breasts' risks are null [27].

The British Menopause Society considers that it is safe to recommend only 1-year use of vaginal estrogens, and the clinicians are advised to use the lowest effective dose for symptoms' control and to counsel women regarding this [28, 29]. A vaginal ring that delivers a large dose of estrogen to the whole body may be an option for HT in hysterectomized women; vaginal rings more often deliver low doses and are considered topical therapy.

### *1.1.3 Vaginal versus oral route for progesterone*

The addition of a progestin (progesterone/progestogen) has only one indication: endometrial protection and endometrial safety during MHT—the prevention of hyperplasia and cancer. Progesterone, the native hormone produced by the corpus luteum during the luteal phase of the menstrual cycle, is the unique option when one seeks “physiological” hormone replacement therapy. The pure progesterone was synthesized in large amount from the plant diosgenin by the chemist Russell Marker in 1940 [30]. Depending on its chemical structure, a progestogen can either enhance (e.g. hot flushes, gonadotropin release, breast epithelial proliferation, and bone mineral density) or antagonize (e.g. endometrium, arterial wall, lipid metabolism, hepatic protein synthesis, and mood) the effects of the estrogen component [31]. Progesterone/progestogens have gene effects on estrogen receptors' synthesis downregulation and metabolic effects on rising levels of the enzyme 17-hydroxysteroid dehydrogenase, which transforms E2 to E1—sulfate, a weak estrogen—and these effects mean the arrest of endometrial glandular cell proliferation, cell differentiation, and secretory activity, and stroma decidualization. Actually, it is very well known that progestins protect the endometrium by inducing secretory transformation within the endometrial glands and stroma decidualization, and their capacity to restore to the normal endometrium without signs of differentiation or secretion is assessed after minimum 6 days and daily administration for 3–6 months in the conditions of hyperplasia [32]. These facts were assessed regarding oral compounds such as MPA, levonorgestrel, and norethisterone during the last two decades of the twentieth century, and less with vaginal/transdermal route of administration. Hyperplasia was reverted by the administration

of MPA continuously for 6 weeks or cyclically for 3 months (2 weeks per month), these being the two regimens most widely used during the years 1990–2000 [33].

Available progestins—progesterone/progestogens—differ largely in their hormonal pattern, and, in addition to their progestogenic and antiestrogenic actions on the endometrium, they can exert androgenic, antiandrogenic, glucocorticoid, and/or anti-mineralocorticoid effects.

Oral progesterone (P4) formulations exist but with a very low bioavailability (<10%) because of rapid intestinal and liver metabolism. After oral administration of P4, low circulating concentrations of P4 contrast with the high concentrations of its metabolites, notably 5 $\alpha$ -reduced metabolites which are known sources of neuropsychological effects [34], reconsidered actually for neuroprotection. The micronization of the P4 molecule provides an optimal bioavailability, which depends both on the size of the P4 particles in suspension and on the nature of the oily excipient [35]. The vaginal route for micronized P4 was proposed since many years ago [36], but the new hypothesis regarding the higher endometrial P4 levels than that obtained after intravenous administration was presented by [37], being considered an opportunity for MHT. This phenomenon of preferential uterine distribution after vaginal administration was named “first uterine pass effect” [38], or “uterine specificity of vaginal progesterone” [39]. Although the serum P4 concentration is often low or “up-physiological”, the endometrium shows clear and complete secretory changes, in the majority of treated cases.

The proposed mechanisms for explanation were done after many experimental and clinical studies: direct diffusion through tissue, intracervical aspiration, absorption into the portal venous system, or lymphatic circulatory system, and countercurrent vascular exchange with diffusion from utero-vaginal veins/lymph vessels to the arteries—all these mechanisms to concur in various extents to the “uterine specificity of vaginal progesterone.” Nasal administration of P4 is inducing comparative serum levels, but the endometrial secretory transformation is incomplete [40].

Previous studies showed that P4 absorption from the vagina is dependent on the formulation used and on the estrogen treatment [41]. The micronization of P4 is very important, and the oral micronized progesterone capsules were re-directed to be used vaginally [42]. Micronized P4 has a more selective effect on PRs and results in less interaction with androgenic and mineral-corticoid receptors compared with other progestogens. The previous administration of estrogens to vaginal micronized P4—100 mg/200 mg—is sustaining endometrial secretory effect compared with many other more potent progestogens. Recent evidence suggests that MHT regimens containing micronized P4 can minimize the metabolic impact and reduce the risk of thromboembolism and side effects associated with progestogens [29].

There are considerable debates about whether and at which dosage micronized P4 provides effective endometrial protection if applied orally, vaginally, or

Recommended doses of micronized progesterone for endometrial protection in MHT		
Route	Dose	Safe use/month and total duration of use
Oral	200 mg/day	12–14 days/month up to 5 years
Transdermal	—	Does not provide endometrial protection
Vaginal	Sequential 45 mg/day or continuous combined 100 mg/day	10 days/month or every other day for up to 3–5 years (off-label use)

*Adapted from Ref. [44].*

**Table 1.** Comparison of oral and vaginal route, and dosages of P4 administration for endometrial safety.

transdermally [43]. Stute P et al. [44] are presenting the international expert panel recommendations on MHT containing micronized P4, based on their systematic review of the actions of micronized P4 on the endometrium. **Table 1** presents the comparison of daily dose, number of days imposed for endometrial protection, and time duration of safety use.

#### *1.1.4 Medicated intrauterine systems*

The medicated intrauterine systems with levonorgestrel or with P4, actually accepted by many menopause societies, are minimizing systemic progestogenic side effects by direct release of progestogen/progesterone into the endometrial cavity and directly opposing the estrogens—natural or from HT. It is presented an endometrial protection which is equivalent to that provided by systemic continuous progestogen administration, and superior to sequential progestogen regimen [45].

## **2. Endometrial safety on MHT: history, regimens, endometrial assessment, and endometrial histology during MHT**

### **2.1 History**

The review of climacteric symptom alleviation in the medical literature shows that the attempts are approximately 100 years old, starting with ovarian extracts, but in time it was demonstrated the ovarian responsibility for endometrial growth up to adenocarcinomas, as in ovarian transplantation [46] or in estrogen secreting ovarian tumors [47–49], cited by Van Gorp and Neven [50]. Long time it was a minimal knowledge on the real estrogen dose per day to correct the menopausal estrogen insufficiency, and on the imposed dose of progesterone to balance endometrial estrogen induced proliferation [51], for prevention of endometrial hyperplasia and cancer [52, 53]. After observational, cohort, and animal studies were designed large prospective RCTs, as it was WHI with 2 arms, closed early than it was intended initially. After a proper WHI patient reanalysis, new perspectives were discovered for the medical communities of medical staff and women.

The post-WHI analysis [54] discovered a high incidence of endometrial cancer [55], specially an increase over time in women aged 50–74 years (with an annual percentage change, in 2004–2009: 2.8%; in 2005–2009: 3.3%; and 2006–2009: 4.2%) [56], parallel to the decrease in the use of FDA-approved estrogen plus progestogen HT and parallel to the increase of endometrial hyperplasia [57], and after the increasing usage of compounded bioidentical HT (CBHT) instead of pharmacological products [58, 59], even if CBHT are not approved by the FDA, because both hormone compounds lack of standard [type (estrogen: is E2 or E3), dosage, (under dosage), and underpotency (for progesterone)] [60].

The number of cases with hyperplasia/endometrial cancer analyzed in different studies was small, fact that gives us contradictory results on endometrial safety on MHT, and there are few analyses on non-oral MHT. The largest prospective study to date on over 700,000 women, Million Women Study [61], which had done information on HT, reported a 30% reduction in risk associated with continuous regimens (based on 73 cases), but other observational studies have shown either no association or increased risks with use of continuous regimens, and some studies showing evidence of a dose-response relation with increasing duration of use ( $\geq 10$  years) or increasing progestin dose. Compared with never users of HT, the risk was: reduced with last use of continuous combined preparations [RR = 0.71 (95% CI 0.56–0.90); P = 0.005].

The “European Prospective Investigation Into Cancer and Nutrition” [62] analyzed the association of various types of HT with the risk of endometrial cancer among 115,474 postmenopausal women, during 1992–2000, and after a mean follow-up period of 9 years, 601 incident cases of endometrial cancer were identified. In comparison with never users of HT, risk of endometrial cancer was increased among current users of E-only HT, with (HR = 2.52, 95% CI: 1.77–3.57), and, to a lesser extent, E + P use (HR = 1.41, 95% CI: 1.08–1.83), although risks differed according to regimen, and type of progestin constituent. The finding of a strong increased risk of endometrial cancer with estrogen-only HT, and a weaker association with combined HT supports the hypothesis that progesterone/progestogens have an attenuating effect on endometrial cancer risk.

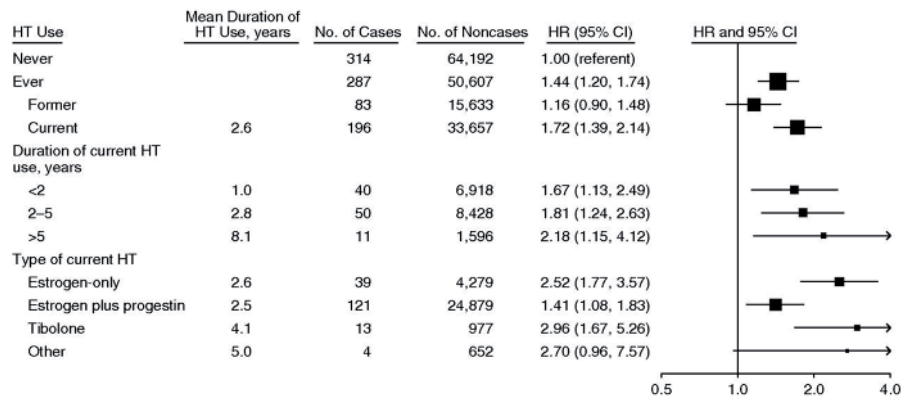
The North American large prospective “Diet and Health” Study of National Institutes of Health-AARP (NIH-AARP) [63] among 19,131 North American postmenopausal women reporting exclusive E plus progestogen use, between whom 176 cases developed endometrial cancer (RR = 0.88; 95% CI: 0.74–1.06), and the HRs for different regimens HT showed a little increase in comparison to the previous European Study. Long-duration ( $\geq 10$  years) sequential E+ P (<15 days P/month) use was positively associated with risk (RR = 1.88; 95% CI: 1.36–2.60), whereas continuous E + P use (>25 days P/month) was associated with a decreased risk (RR = 0.64; 95% CI: 0.49–0.83). The American authors’ opinion is that findings support the fact that specific used categories of E+P increase the endometrial cancer risk: specifically long durations of sequential progestogens, whereas decreased endometrial cancer risk was observed for users of short-duration continuous progestogens add to estrogen.

The National Institutes of Health-AARP Diet and Health Study cohort, which did the follow-up for endometrial cancer risk after WHI’s premature closure, [64] did confirm a statistical reduction of endometrial cancer risk after continuous combined oral MHT for 5.6 years (RR = 0.85; 95% CI, 0.53–1.36), with normal endometrium at entry, and including women in the highest BMI groups; this review was done because the data were not clear after immediate publication of WHI (2002, 2004).

Parallel to these data, the “European Prospective Investigation Into Cancer and Nutrition” shows a strong association of risk among women who were older, leaner, or had ever smoked cigarettes [62], and the North American studies show an increased risk for sequential E + P only among thin-to-normal weight women (BMI < 25 kg/m<sup>2</sup>; RR = 2.53) [63]. California Teachers Study [65] reports that continuous-combined MHT was confined to thinner women (BMI < 25 kg/m<sup>2</sup>) (P for interaction: 0.03), and among heavier women (BMI  $\geq$  25 kg/m<sup>2</sup>), use of continuous-combined EPT was associated with a statistically nonsignificant reduction in risk, fact that is different from what was assumed in normal weight women. The association between endometrial cancer risk in continuous-combined MHT users to patients’ BMI is correlated to women’s lower endogenous estrogen levels, suggesting that menopausal hormones and obesity increase endometrial cancer through common etiologic pathways, as was recently considered that a BMI  $\geq$  25 kg/m<sup>2</sup> is increasing the rate of recurrence in patients hormonally treated for complex hyperplasia/carcinoma (P = 0.0004, OR 0.4; 95% CI: 0.3–0.6), or early stage carcinoma (P = 0.0000, OR 0.3; 95% CI: 0.2–0.6) [66] (**Figure 2**).

Healthy lifestyle index including diet, alcohol consumption, physical activity, body mass index, cigarette smoking, is recently correlated to endometrial cancer risk in Canada [67] and USA [68], and higher scores reflecting a healthier behavior of postmenopausal women are associated to reduction of endometrial cancer risk of various intensity according to the degree of type 1 cancer differentiation. Each unit increase in the HLI score was associated with 3% and 5% reductions in risk of postmenopausal endometrial cancer risk (HR 0.95; 95% CI: 0.90–0.99). The American





**Figure 2.** Hazard ratios (HRs) for risk of endometrial carcinoma (black squares) according to use of menopausal hormone therapy (HT), by recruitment center and age, European Prospective Investigation into Cancer and Nutrition, 1992–2006. The size of each square is inversely proportional to the variance of the logarithm of the relative risk. HRs were adjusted for body mass index, parity, age at menopause, and oral contraceptive use. Bars, 95% confidence interval (CI). Adapted from Ref. [62]. Permission of Oxford Publishers.

HLI showed that after a median follow-up of 17.9 years there were 1435 endometrial cancer cases, and women in the highest quintile of the HLI score had a lower risk of overall, type I, well-differentiated, moderately differentiated, poorly differentiated, and localized endometrial cancer than those in the lowest quintile [for quintile 5 vs. quintile 1, HR = 0.61 (95% CI: 0.51, 0.72), HR = 0.60 (95% CI: 0.49, 0.72), HR = 0.66 (95% CI: 0.46, 0.96), HR = 0.69 (95% CI: 0.52, 0.90), HR = 0.49 (95% CI: 0.34, 0.72), and HR = 0.61 (95% CI: 0.50, 0.74), respectively].

## 2.2 Regimens of MHT: uterine bleeding on perimenopausal/menopausal hormone therapy

The chapter will discuss MHT with non-oral administered natural estrogens which are available for perimenopausal and postmenopausal women, in comparison to oral available drugs, including contraceptive pills, among which there are some with natural estrogens, as are the estrogens in MHT. The history of MHT describes three types of MHT systemic regimens with estrogens and progesterone/progestogens for women with intact uterus, and only one systemic regimen with natural estrogens in hysterectomized women. Exogenous hormones are influencing endometrial cycle, and may also influence uterine volume, fibroid growth, polyps, endometriosis, and the development of cervical adenocarcinomas [50]. Progesterone/progestogens are mandatory for endometrial protection, as it is known since long time. Regarding endometrial safety one must discuss the characteristic of uterine bleed which appears in conjunction to the type of regimen, and the medical staff must counsel patients.

### 2.2.1 Sequential combined estrogen-progesterone/progestogen therapy

The sequential/cyclic administration of HT has minimum 10 days of progesterone/progestogen, more safe is 12–14 days. In this regimen both hormones are oral or non-oral administered, or only one is on a non-oral route. If the last menstrual period occurred less than 1 year prior to starting MHT, a sequential combined regimen should be started, i.e. continuous estrogen with progesterone/progestogen for 12–14 days per month [29]. Thereby reducing the risk of endometrial hyperplasia. The patients will have a monthly withdrawal bleed with this regimen, which usually starts from the 11th day of progesterone/progestogen when this administration is for 10 days [69], and the endometrial thickness at transvaginal sonography

(during the progestin administration) is higher than 4 mm at least in the first year of use [70]. Prescription of cyclic transdermal/percutaneous E2, and the sequential addition of natural progesterone or a synthetic progestogen induces artificial cycles with regular withdrawal bleeding.

### *2.2.2 Continuous combined estrogen-progesterone/progestogen therapy*

Both hormones are administered oral or non-oral, or only one is non-oral. These regimens are increasingly used early in postmenopausal women, and the large long term Medical Research Council randomized controlled trial on HT, the Women's International Study of Long Duration Estrogen after the Menopause, and the WHI study in the USA are based on this type of oral treatment, being accepted also for women with endometrial hyperplasia without atypia. This type of regimen is discussed after a minimum 6 [69] to 12 months of sequential MHT [29] or 1 year after the last menstrual period (2 years in women with premature ovarian insufficiency). Women who wish to avoid a monthly withdrawal bleed may attempt a switch to a continuous combined regimen, which aims to give bleed-free MHT. This will minimize also the risk of endometrial hyperplasia, as it was previously discussed. There may be some erratic bleeding to begin with, but on persistence with continuous combined regimens 90% of women become bleed free.

British Menopause Society [20] has some recommendation for some special situations with uterine bleeding on continuous combined HT, as follows:

- If breakthrough bleeding occurs following the switch to continuous combined HRT and does not settle after 3–6 months, then the woman can be switched back to a sequential regimen for at least another year.
- If bleeding is heavy or erratic on a sequential regimen, the dose of progestogen can be doubled or duration increased to 21 days.
- Persistent bleeding problems beyond 6 months warrant investigation with ultrasound scan, and endometrial biopsy if clinically indicated.

### *2.2.3 Cyclic hormone replacement therapy using quarterly progestogen during 1 year or long cycle hormone replacement therapy*

By the year 1994, Ettinger B (USA) proposed a cyclic hormone regimen with quarterly progestogen instead of monthly, aiming endometrial protection from hyperplasia and cancer, fact that was accomplished by 10 mg/day of MPA for 14 days at every 3 months [71], and with gestodene 50 µg for the last 12 days of 84 days with continuously 17β E2 in different doses—1 or 2 mg/day, with 1 year duration in the Netherlands [72]. These studies reported less bleeding episodes, with longer duration, and similar high number of hyperplasia compared to baseline assessment. In the Nordic countries this type of MHT regimen is popular, and the Scandinavian study [73] with a duration of 4 years reported partially similar results, but they used norethindrone acetate at a dose of 1 mg/day, for 10 days associated to 17β E2 2 mg per day, reduced to 1 mg day during the last 6 days of each cycle of 12 weeks. They reported a higher rate of drop-out due to bleeding vs. monthly progestogen ( $P < 0.01$ ), and hyperplasia incidence of 5.6% vs. 1% in the monthly group ( $P = 0.003$ ), with 1 case of atypical hyperplasia, and 1 case of endometrial adenocarcinoma. The popularity of this regimen is correlated to the 2-fold elevation of endometrial cancer risk in Finland population, and the risk reduction after cessation of the regimen [74].

Hormone	Preparation
Transdermal estrogen	17 $\beta$ -estradiol patch 17 $\beta$ -estradiol gel 17 $\beta$ -estradiol emulsion 17 $\beta$ -estradiol spray
Vaginal estrogen	17 $\beta$ -estradiol cream Conjugated equine estrogen cream 17 $\beta$ -estradiol ring 17 $\beta$ -estradiol tablet Estriol cream Estriol soft capsules
Vaginal progesterone	Micronized progesterone—soft capsules, gel
Transdermal progesterone/progestogens	Norethindrone acetate Levonorgoestrel
Progestin: intrauterine system	Levonorgestrel Progesterone

**Table 2.**  
*Available non-oral estrogens and progesterone/progestogens for MHT.*

Besides these analyses, there is no proper study on non-oral administrated hormones, neither estrogens or progesterone/progestogen, because the Spanish study [75] assessing endometrial stability by the rate of amenorrhea and endometrial stimulation is monitoring the intermittent administration of 100 mg vaginal micronized progesterone to a patch delivering low-dose estradiol (25  $\mu$ g/day). According to the Scandinavian data on hyperplasia and cancer risk [76, 77] in long cycle progesterone/progestogen regimen the bleeding pattern is not sufficient for endometrial safety, being mandatory endometrial monitoring with ultrasound and biopsies (**Table 2**).

#### 2.2.4 Uterine bleeding on hormone therapy: is it predictive for uterine histology?

Women who start MHT from early stages of STRAW (–3 stage) may benefit from therapy with progesterone/progestogens, which balances their hormonal milieu, but starting replacement after 1 year amenorrhoea may induce the major disadvantage—the unpredictable bleeding and/or spotting, which are common in the early months of use, no matter what regimen is used. The unpredictability and persistence (in the short term) of bleeding and/or spotting is a common cause for discontinuation.

At the beginning of this century the Australian researchers [78] have presented 2 patterns for bleeding when on MHT: scheduled “withdrawal” bleeding, or unscheduled “breakthrough bleeding”, usually for sequential, respectively for continuous combined regimen. Depending on the regimen, the endometrium may be proliferative, secretory, near atrophic or a mixed picture, and bleeding may occur from either an estrogen-dominated or a progestogen-dominated endometrium. When recommending continuous-combined regimen after a long duration of amenorrhea, the incidence of breakthrough bleeding is high in the first 3–6 months.

Since many years it is considered that the bleeding pattern cannot be a good predictor for endometrial histology, and safety, but it is an exception with progesterone/progestogen withdrawal bleeding in the sequential regimens, after 3 to 6 cycles of therapy, and when it is a complete secretory transformation, the bleeding may be cyclic in the last 5 days of progesterone/progestogen, or in the first 6 days of the next cycle [79]. Hyperplasia is not predicted by regular bleeding on HT, as a multicenter study suggests [80].

The variations of endometrial answers to transdermal estrogen and vaginal micronized progesterone are reduced in comparison to HT oral route, according to more stable transdermal/percutaneous estrogen serum levels, and progesterone uterine first pass. When the bleeding pattern is observed comparative to endometrial histology, the patients with proliferative histologic pattern are bleeding early than the patients with secretory transformation [81].

An Italian prospective study [82] evaluated and compared uterine bleeding in 100 early postmenopausal women (12–36 months after last menses) on a sequential regimen with both hormones administered non-oral, *versus* the same regimen with oral natural progesterone (NP). All groups were treated with transdermal 17 $\beta$ -E2 50  $\mu$ g/day, and the NP was 100 mg or 200 mg per day from the 14th day to the 25th day of each 28-day cycle. After 12 cycles of treatment, no significant differences were observed in endometrial thickness between groups, suggesting that all treatments are effective in balancing the estradiol effects on endometrium. Regarding bleeding control, patients in the group with sequential vaginal NP showed a higher number of episodes of regular bleeding than patients in groups with oral NP, and fewer episodes of spotting. Authors' conclusion was that transdermal estrogen combined with vaginal 100 mg micronized NP from the 14th day to the 25th day of each 28-days cycle leads to a good cycle control, and provides excellent patient satisfaction without serious side-effects. The better control of bleeding was associated with a higher treatment compliance in patients who received vaginal NP, with a larger percentage of women completing the study. The authors recommend to start treatment with the lower dose of NP (100 mg/day) to avoid the risk of amenorrhea with 200 mg/day.

An Italian study which is considered with the longest duration—3 years, has prospectively evaluated the bleeding/amenorrhea in 30 postmenopausal women treated with continuous transdermal E2 gel and every-other-day vaginal micronized progesterone in capsules [42]. They report that 4 (13%) of 30 patients withdrew from the study because of bleeding (3 for heavy bleeding and 1 for repeated spotting), and an higher incidence of amenorrhea (82%) than commonly reported (70%) with oral compounds [83].

### **2.3 Endometrial safety: endometrial assessment on MHT and endometrial histology on non-oral regimens of MHT**

#### *2.3.1 Endometrial safety*

Endometrial safety is a grill for challenge menopausal and postmenopausal HTs, because the bleeding and the risks of hyperplasia and cancer are discussed in the 70 years of MHT history, years with many waves of increased and decreased enthusiasm on the benefits and risks of MTH. The aim of replacement and restoration of ovarian functions in postmenopausal women with estrogens and progesterone is only a modest attempt for women's health, because there are missing other molecules as testosterone, activin, inhibin, anti-Müllerian hormone (AMH) and insulin-like growth factor 1 (IGF-1), and many other connected to these, which have an immense significance on a woman's physiology, and all of them may influence endometrial actions of MHT [84].

The endometrial safety means the protection from non-invasive proliferative lesions—hyperplasia, and invasive—carcinoma.

- If the analysis of histological data is done after the criteria of the years 80' the endometrium must be with secretory changes in the sequential regimens, and atrophy, or inactive after the continuous—combined regimens.

- If the analysis of histological data is done after the criteria of the years 90' endometrial safety means to reduce the risk of hyperplasia and carcinoma development, in fact to down-regulate estrogen induced proliferation, with disappearance of mitosis from the endometrial glands, and stroma, or  $\leq 2$  mitoses at 1000 cells, the so-called proliferation index, or mitotic index [44].

The impact of vaginal progesterone on the endometrial safety is very important, being considered that the duration is more important than the dose [85]. After the results of the Scandinavian study regarding long cycle progestogen association to estrogen—at 3 months interval [86], which was updated in *Cochrane Database Systematic Review* [87, 88], today it is considered that it is important to combine a progesterone/progestogen with the estrogen in the beginning of the treatment, to control early endometrial growth. If one considers these Scandinavian studies, one may accept a non-opposed estrogen administration as Van Gorp and Neven recommend [50]. Minimum 10 days/month of vaginal administration provides protection in sequential regimens, in a dose of 45 mg/day at 4% in cream, or every other day in a dose of 100 mg/day for up to 3–5 years (off-label use) [44], but this aim is not accomplished with transdermal micronized progesterone [89, 90]. The daily balance of non-oral estrogen by non-oral progesterone/progestogen in continuous combined regimens is more stable than the balance of oral administration, and endometrial carcinoma risk is also reduced, as since long time ago it was reported after 8 years of use [91]. If oral and non-oral routes of progesterone/progestogen administration are proved to be less effective in treatment of atypical endometrial hyperplasia, and unable to stop most early invasive cancers, the intrauterine system with levonorgestrel 20  $\mu\text{g}$  /day associated to transdermal estrogens was demonstrated to achieve these aims after 3 years administration. From 20 Belgian women, only one asymptomatic women with atypical hyperplasia at baseline at 3 years was discovered with focal residual non-atypical hyperplasia, in the presence of a thin (<4 mm) endometrium [92].

In 2002, Van Gorp and Neven [50] have published in “Maturitas” the Journal of the European Menopause and Andropause Society a review of endometrial safety on MHT. They presented a Finish study [93] on the endometrial safety after short term HT (12 months) regarding percutaneous estradiol-gel delivering E2 1.0 mg/day, or patch (delivering E2 50 pg/day) in a sequential regimen with oral dydrogesterone 10 mg/day for first 12 days of the cycle. The endometrial biopsies—collected during the 9th to 12th days of the progestogen days in both groups did not revealed any hyperplasia, or any estrogenic effect.

### 2.3.2 *Endometrial assessment on menopausal hormone therapy*

MHT must be assessed when women start therapy, with an annual follow-up or when there is a minimal suspicion of endometrial abnormality regarding bleeding, or when it is an abnormality at transvaginal scan by endometrial biopsy, with Pipelle Cornier suction curette, Kevorkian or Vabra curette, or by fractional curettage—endometrium and endocervix, or by out-patient hysteroscopy. Hysteroscopy permits to avoid the loss of an isolated focus of endometrial cancer, atypical hyperplasia or polyp which easily can be missed by blind sampling procedures [70]. On another hand hysteroscopy is prone to depict the changes of endometrial surface, vessels, which are very much discussed by the Australian gynecologists and pathologist in connection to bleeding pattern on MRT [78].

Besides some inconvenients which will be discussed in the next subchapter, the endometrial sample obtained with Pipelle Cornier suction curette has been shown to be as accurate as conventional dilation and curettage in the diagnosis of endometrial pathology in premenopausal and postmenopausal women [94]. The amount

of endometrial tissue is very little, sometimes much less than that demanded by pathologists unused to such biopsies, but when the microscopy is corroborated to ultrasound, the medical staff can be reassured of safety [94].

Double layer endometrial thickness is usually measured at the thickest part in the longitudinal plane, by scanning from cornua to cornua. The poorly echogenic layer surrounding the highly echogenic endometrium is not included in the measurement. Endometrial thickness is evaluated to determine the mean of three measurements and excluding the possible endometrial fluid from the measurement. One must take into account in elder patients with atrophic endometrium after MHT that the fluid may be blood, even the patients do not bleed. In oral and non-oral MHT the endometrial thickness has an initial increase—more important after sequential regimens, with a consistent decrease at 36 months when on continuous combined regimens, so the endometrium becomes significantly thinner than at baseline. These data are controverted by the previously presented prospective Italian study, which after 12 cycles of non-oral sequential treatment discovered no significant differences in endometrial thickness between groups, suggesting that all treatments are effective in balancing the effects of percutaneous E2 on endometrium [82].

The prospective Italian study on continuous-combined non-oral MHT [42] revealed a smaller increase of the endometrial thickness comparative to that reported by a similar North American oral regimen; the baseline-to-endpoint increases in endometrial thickness were  $7.8 \pm 3.8$  mm, and  $1.8 \pm 3.2$  mm, respectively [95] versus the Italian data, where the mean endometrial thickness increase was only 0.7 mm, after 6 months treatment, and endometrial atrophy was registered after 3 years (end of study), in all cases that completed the study [twenty-three (76.7%) women from 30 healthy cases in natural menopause]. The British study [96] revealed a continuous increase of endometrial thickness from baseline [3.3 (1.7)] mm to the mean of 5.3 (3.3) mm by 24 weeks ( $P < 0.001$ ), and of 5.5 (2.8) mm after 48 weeks, with continuous combined transdermal E2 1.1 mg/day plus 4 mg/day NP cream, ( $P < 0.001$ ), being a non-significant increase from 24th to 48th weeks, but the increase was more important when it was inadequate endometrial opposition (4.7 mm vs. 7.6 mm respectively,  $P < 0.001$ ). These results and the histological aspects of proliferative endometrium with inadequate progesterone opposition after 48 weeks HT—which will be analyzed in next subchapter, sustain the actual recommendation to avoid transdermal natural progesterone.

### *2.3.3 Endometrial histology with non-oral MHT*

Endometrial histological assessment is a very important part of the continuing follow up of women taking MHT. There are few studies on endometrial histology after MHT with both hormones administered non-orally in comparison to oral route.

**Table 3** is listing such studies, which were published after WHI, with some North American studies before the year 2000; the studied estrogens and progestogens were transdermal administered, and the soft capsules of micronized progesterone were vaginally administered. Because it is the rule of baseline endometrial assessment, the studies are comparing the histology at pre, and post-treatment, or in some of them to oral MHT. The endometrial biopsy is done before treatment, and between 9th and 14th days of treatment cycle, to evaluate the progesterone/progestogen effect (similar to cases on oral MHT), in the sequential regimens. The endometrial specimen is collected after 6 months, no matter which day, in continuous-combined MHT regimens.

Endometrial safety is assessed in terms of prevention of estrogen-induced hyperplasia. Progesterone supplementation may cover the objective of endometrial protection from benign hyperplasia from the STRAW—3 stage (2012), or when it is

Authors/study group, year Duration of use	Type and dose of estrogen	Type and dose of progestegen/ progesterone	Hyperplasia, type 1/2 cancer P value (authors conclusions/ comments)
Archer DF, Furst K, et al., 1999 [97] 3, 6, 9, and 12 months after initiation of treatment	Continuous combined estradiol 50 µg/day	Norethindrone acetate 140, 250, or 400 µg/day	0.8% (1 of 123), 1% (1 of 98), 1.1% (1 of 89) (P < 0.001)
Ylikorkala O, Rozenberg S, 2000 [98] 12 months	Continuous combined or sequential E2 50 µg/day	Continuous combined Trd NETA: 170 µg/day or sequential Trd NETA: 350 µg/day, or sequential oral NETA 1 mg/day or sequential DYD 20 mg/day	2 cases of simple hyperplasia were reported (1 in each low-dose progestogen group)
Shulman LP, Yankov V, Uhl K, 2002 [99] 12 months	Continuous combined, once a week patch E2 0.045 mg/day	LNG mg/day of 0.015; 0.030; and 0.040	No hyperplasia
Sturdee DW, van de Weijer P, von Holst T, 2002 [100] 12 months	Sequential: 3 groups 1. patches of 15 cm <sup>2</sup> (50 µg/day E2 for 2 wks, followed 50 µg/day E2–10 µg/day LNGI for 2 wks) 2. 22.5 cm <sup>2</sup> (75 µg/dy E2 for 2 weeks followed by 75 µg/day E2–15 µg/day LNG for 2 wks) 3. 30 cm <sup>2</sup> (100 µg/day E2 for 2 wks followed by 100 µg/day E2–20 µg/day LNG for 2 wks)		Endometrial protection for all groups
Dando TM, Perry CM (2004) [101] 17 beta-E2/LNG transdermal system 12 months, RCT	Continuous combined, 2 groups with once a week Patch 17 β estradiol:+ LNG 4.4/1.39 or 4.4/2.74/day or 4.5/3.75 mg/day		No hyperplasia
Cicinelli E, de Ziegler D, Colafiglio G, et al., 2005 [42] 3 years monitoring	Continuous combined 17 β estradiol gel, 1.5 mg/day	Micronized progesterone, soft capsules 100 mg every-other-day (or at 48 h) (vaginal)	No hyperplasia Atrophy: 100%
Vashisht A, Wadsworth F, Carey A, Carey B, Studd J, 2005 [96] 48 weeks (54 cases, only 41 completed the study)	Continuous combined oestradiol 1 mg/day transdermal daily	Natural progesterone cream 40 mg/day (transdermal)	10 (27%) endometrial proliferation, 2 (5%) complex hyperplasia, 1 with (mild) atypia, and 1 without atypia
Samsioe G, Dvorak V, Genazzani AR, et al., Estalis 25/125 Study Group, 2007 [102] 96 weeks	Continuous combined estradiol matrix 25 µg/day	NETA 125 µg/day	No hyperplasia No cancer
Russu M, Terzea D, Hudiță D, 2009 [103] 24 months monitoring	Sequential HT 1. Group oral: 2 mg/d E2 valerate (E2V) 21 days, E2V plus CYP 10 days 2. Group oral: 2 mg/d -mcr E2 14 days, 2 mg/d mcrE2 plus DYD 14 days 3. Group mixed: 17β E2 patch (25 µg/d 21 days) plus oral MPA (10 mg/5 mg/day) last 12 days 4. Group fully non-oral: 1 g/d 17β E2 gel 28 days plus 200 mg/d vaginal micronized VMP last 12 days		1 case with simple hyperplasia without atypia after 24 months, on transdermal estrogen +5 mg MPA (incidence 1/43 cases) is inside the oncological safety (2 cases/100 women year) No carcinoma

Authors/study group, year Duration of use	Type and dose of estrogen	Type and dose of progestegen/ progesterone	Hyperplasia, type 1/2 cancer P value (authors conclusions/ comments)
Fernandez-Munga L, Hermenegildo C, Tarin JJ, Garcia-Perez M-A, Cano A, 2012 [75] 12 months	Intermittent (twice a week) Estradiol patch 25 µg/day	Intermittent (twice a week) 100 mg micronized progesterone (vaginal)	No apparent endometrial stimulation

*E2, estradiol; LNG, levonorgestrel; NETA, norethisteron enanthate; E2V, estradiol valerate; CYP, cyproterone acetate; DYD, dydrogesterone; VMP, vaginal micronized progesterone.*

**Table 3.**  
*Studies on endometrial histology and safety after non-oral routes of MHT.*

the onset of menstrual cycle irregularities, which may have hyperplasia as histologic substrate.

The effects of hormones are appreciated on the architecture and cytological aspects of the epithelium, glands, stroma, and vessels. Mitoses are considered for estrogens proliferative effect, and subnuclear glycogen accumulation, and intraluminal secretions for high grade progesterone effects, or the cytoplasmic vacuolisation, for low grade progesterone secretory change [104, 105]. When progesterone regulation effect is not possible to be assessed with accuracy, the degree of proliferation suppression—mild, moderate, strong is a surrogate for evaluation, as it was done in the Romanian analysis [103].

There are many pathologists involved in endometrial assessment on/after MHT in Europe, USA, Canada, South Africa. **Table 4** presents an adaption of endometrial changes on MHT according to International Society of Gynecological Pathologists (2019) [112, 113], WHO (2014) cited by [123], British Society for Gynecological Endoscopy (2014) [120], FIGO (2009, 2012) cited by [119]. Deligdish [104], Feeley and Wells [94] present very understandable the endometrial effects of MHT, including a wide spectrum of morphologic features, known since long time on oral MHT, and less on non-oral routes, which are. Recently discussed by Owings and Quick [105]. For simplicity of understanding, **Table 4** contains the classification of endometrial histology changes, with special attention to the hyperplasia [WHO, 1994, with 4 types updated by WHO, 2014, cited by [123], which was recommended for use by the Royal College of Obstetricians and Gynecologists (RCOG), and the British Society for Gynecological Endoscopy (BSGE) [120], with only 2 categories, as it is mentioned in the table, and it was discussed at the beginning of the subchapter].

The first three types (unassessable, inactive, atrophic) may impose some problems to the pathologist, because there is a small amount of tissue—obtained with Pipelle suction curette, and the British pathologists Feeley and Wells [94] appreciate that this condition can be associated to thin, regular endometrium at hysteroscopy, or with an endometrial thickness not exceeding 7 mm, at sonography [108], and though the pathologist can therefore be reassured that where the endometrial cavity has been entered and little or no endometrial tissue is obtained, there is very little likelihood of important endometrial pathology to be present. The assessment of secretory endometrium may be confused by artifacts of fragments disruption, which may induce focal changes of glandular tortuosity and crowding. The diagnosis of low grade cytological atypia is very difficult to be appreciated [94]. In a progesterone/progestogen rich environment, nuclei of premalignant glands tend to diminish in size, and acquire a rather bland chromatin pattern, which makes them



---

**Unassessable**

- No tissue identified
- Tissue insufficient for diagnosis
- No endometrium identified
- Endometrial tissue insufficient for diagnosis

**Inactive**

- Narrow tubular glands lined with cuboidal epithelium

**Atrophic**

- Cystically dilated glands lined by single layer of inactive, flattened epithelial cells

**Proliferative**

- Presence of epithelial mitoses

**Secretory**

- Epithelial cytoplasmic vacuolation—subnuclear or supranuclear
- Glandular luminal secretion in mid-phase and late phase

**Pseudo-decidual change**

- Typical stromal decidual change associated with inactive or weakly secretory glands, induced by progestogen

*Benign hyperplasia* (BH), Mutter [106] or endometrial hyperplasia without atypia (WHO, 2014), which covers formerly named simple and complex hyperplasia without atypia (WHO, 1994)

- Simple hyperplasia without atypia:
- Dilated glands with increased nuclear stratification of lining epithelium and increased stromal mitoses.
- No risk of malignancy
- Complex hyperplasia without atypia
- Crowded and irregular branched glands
- Low risk of malignancy

*Atypical endometrial hyperplasia* (WHO, 2000), or endometrial intraepithelial neoplasia (EIN)—[106, 107]

- Atypical epithelial cells; high risk of malignancy

**Carcinoma** (endometrioid type, non-endometrioid type)

---

*Adapted from WHO (2014) which updated WHO (1994); [106, 107, 121].*

---

**Table 4.**

*Classification and associated features of histological examination of the Pipelle endometrial biopsy.*

appear less “atypical”. Paradoxically, the nuclei of normal glands become enlarged and rounded—features associated with atypia [109].

The endometrium aspect depends on the regimen; it may be proliferative, secretory, near atrophic, inactive, or a mixed picture—mixed proliferative and secretory endometrium including crowded and hyperplastic glands, alternating with an edematous, hyperplastic, or decidualized stroma, sometimes with thickened or thrombosed blood vessels.

Most endometrial biopsies from women on sequential MHT show weak secretory features. Approximately 15% show proliferative activity, although this figure may be less if more than 9 days of progesterone/progestogen is given per cycle. A small proportion are revealing an inactive or atrophic endometrium. Up to 50% of biopsies in cases on continuous combined HT contain minimal tissue for pathological analysis: this correlates well with an atrophic endometrium with no appreciable pathology. Of the 50% with more substantial material, approximately one half presents endometrial atrophy, and one half are showing weak secretory features [94]. The Romanian analysis shows that after complete non-oral route of HT, the proliferative rate and secretory changes were more frequent in the first year, and

atrophy was after oral HT. The analysis regarding endometrial stroma has revealed two important aspects to be discussed:

- the increase of stroma the fibroblast-fibrocytic proliferation, and the reduction of fibrosis in all treated cases, indirectly the maintenance of the stroma volume (an important criteria when on discuss about EIN, with volume percentage of stroma <55%). This change makes the difference between normal cycling endometrium and the iatrogenic one.
- the increase of the granulocyte inflammatory reaction, which is like a pseudo-decidualisation, not a sign of endometritis, which need to discover the presence of periglandular plasma cells, and leukocytes. In the natural menstrual cycle the presence in endometrial stroma of the leukocytes infiltration is normal in the premenstrual phase, when starts the decline of estrogen and progesterone, aspect which is rarely discovered, but it is discussed also by Deligdish [104] in sequential regimens, as a probable result of the iatrogenic hormones withdrawal.

### **3. Endometrial hyperplasia and endometrial cancer risks in MHT: immunohistochemistry for biomarkers of endometrial transcriptome in MHT**

#### **3.1 Endometrial hyperplasia and cancer**

Endometrial cancer is the fourth cancer in women from developed countries [110], and actually there are 2 types of endometrial cancer, with different natural history, carcinogenesis and evolution.

According to the molecular mechanisms, to the dualistic model of endometrial cancer development, first time described by Bokhman [111], the last classification at the Endometrial Cancer Workshop sponsored by the International Society of Gynecological Pathologists in 2016 [112], and the most recent discussion of the International Society of Gynecological Pathologists in 2019 [113] describes low grade and high grade endometrial cancers, both types being discussed to have MHT in perimenopause and late postmenopausal stages of women's life.

- low grade or type 1 or endometrioid endometrial or the “indolent” cancer, which is estrogen dependent, has “atypical endometrial hyperplasia”, as precursor (23% cases progress to endometrioid adenocarcinoma), a monoclonal lesion, with microsatellite instability, and *ras* and *PTEN* mutations [106, 107, 109, 114, 115], and *PTEN* gene loss in up to 65% cases with EIN and in 85% cases with endometrioid carcinoma [116], with estrogen and progesterone receptors at immunohistochemistry analysis [110] discovered more frequent in white, Caucasian women.
- high grade endometrial carcinomas or type 2 are represented by previous FIGO grade 3 endometrioid carcinoma, serous endometrial carcinoma, clear cells endometrial carcinoma, undifferentiated/dedifferentiated carcinoma, and carcinosarcoma. They are non-estrogen dependent, more aggressive, with atrophy or with a polyp rather than hyperplasia as precursor, and they are non-responsive to progestins [32]. They contain *p53* mutations and abnormal accumulation of *p53* protein, and absence of ERs, PRs [117, 118]. In cases with serous endometrial carcinoma the estrogen level is low, but SHBG is high, women are 6 years elder, with lower BMI than the cases with type 1.

The FIGO grading 1, 2 and 3 of endometrioid endometrial adenocarcinomas are actually nominated only in two grades, as follows: former grade 1 and 2 are the actual “low” grade endometrioid endometrial carcinomas, and former grade 3 is the actual “high grade” [119], although FIGO, the ACOG, and the College of American Pathologists are considering this grading as standard.

Hyperplasia and endometrioid endometrial cancer risk is associated to excess levels of estrogen, or to non-balanced/non-opposed estrogens by progesterone/progestogens—proved by PEPI trial (1996) [122], after the well-known paper of Kurman et al. [32], and recently reconfirmed by the “European Prospective Investigation Into Cancer and Nutrition” [62]. Mutter [106, 109] is describing benign hyperplasia—with low risk for malignancy, type that was discovered in the studies listed in **Table 3** and “Endometrial Intraepithelial Neoplasia” (EIN) the precursor for the endometrioid endometrial/type 1 cancer.

The terminology of “Endometrial Intraepithelial Neoplasia” (EIN) [109, 116] was previously termed in the World Health Organization system (1994) as atypical endometrial hyperplasia — simple, and complex. There is no direct concordance of WHO to EIN categories because the two strategies employ different criteria that are often nonequivalent [123]. One must remember that approximately 50% of women diagnosed with atypical hyperplasia have concurrent carcinoma [124].

The WHO (1994) system largely relies on relatively fixed notions of how atypical endometrial cells appear, whereas an EIN criterion combines crowded architecture and a relative change in cytology in the high-risk category.

“Endometrial Intraepithelial Carcinoma” (EIC) [125] is considered as precursor for high grade/type 2 endometrial cancer, and it represents malignant transformation of atrophic surface endometrium, discovered in 89% of cases. “Endometrial intraepithelial neoplasia” should never be confused with “endometrial intraepithelial carcinoma”, which refers clearly to type 2 endometrial cancer, usually named as serous carcinoma, and is driven by a p53 mutation. Awareness of these 2 entities and their histologic features is critical for avoiding misclassification [109, 118].

The data regarding endometrial hyperplasia/cancer on or after non-oral route of MHT are few, but generally they may be comparable to those on oral drugs. The Finnish Cancer Registry [74], which evaluated cancer risk from 1995 to 2007 recorded 1364 type 1 and 38 type 2 endometrial cancers by the end of 2006, and the study analyzed duration and type of regimen, route and type of progestogen: oral/non oral sequential (10–14 days once a month—“monthly sequential” or every three months—“long-cycle”), or continuous combined (E2 patch or gel plus NETA or LNG), or E2 transdermal + LNG-releasing intrauterine device system (LNG-IUS).

- For use of <5 years, the OR for sequential EPT was 0.67 (95% CI: 0.52–0.86), for continuous E2+ P was 0.45 (CI: 0.27–0.73), and for E2 plus LNG-IUS = 0.39, CI: (0.17–0.88).
- A decreased risk persisted for the use of continuous E2+ P and E2 plus LNG-IUS of up to 10 years.

The conclusion of the Finnish study was that the use of a continuous rather than a sequential E2-progestogen regimen decreases the risk of endometrial cancer, whereas the route of administration or type of progestin does not differ in terms of endometrial cancer risk.

A recent North American study [126] revealed that compared with non-MHT users, cases who reported using E+ P Therapy had lowered all-cause (HR = 0.65, 95% CI = 0.43–0.99) and endometrial cancer-specific mortality (HR = 0.51, 95% CI = 0.26–0.98), study which can be added to a previous study from Sweden [127],

which investigated tumor grade and depth of myometrial invasion, and 5-year relative survival in postmenopausal endometrial cancer patients. In this analysis, ever use of any MHT entailed lower risks of having moderately and poorly differentiated tumors. The lowest OD for poorly differentiated tumors were seen for ever users of cyclically combined estrogen-progestin [OR = 0.23 (95% CI: 0.07–0.73)]. Ever users of any form of MHT, particularly medium potency MHT users, had significantly lower risks for tumors with deep myometrial invasion, and adjusted estimated relative excess HRs revealed significantly improved survival for ever users of any form of MHT [RER = 0.40 (95% CI: 0.16–0.97)]; in particular ever users of any form of oestrogens [RER = 0.38 (95% CI: 0.15–0.99)]. The authors' conclusions were that MHT ever used induces a more favorable tumor characteristics, less aggressive and with better patients' survival.

### 3.2 Immunohistochemistry for hyperplasia and endometrial cancer risk on MHT: endometrial transcriptome and biomarkers

Endometrium is a tissue with strong capacities of renewal/remodeling for cell proliferation/new tissue formation, differentiation, apoptosis, angiogenesis which are highly regulated by ovarian steroids, and various locally expressed gene products, and with the presence of regenerative endometrial stem cells with their special capacities, which are maintained in menopause. The role and qualities of endometrial stroma in EIN, and cancer progression are very important, and the mechanisms of E and P4 in promoting proliferation on one side, secretory activity and differentiation on the other side are connected to the steroid receptors presence, and to the transformation of endometrial transcriptome, because of gene or epigenetic changes by hypermethylation of DNA and histones, with overexpression or under-expression of genes that encodes the proteins necessary for successful proliferation, apoptosis, angiogenesis, and fight against endometrial epithelial glands and stroma atypia. The reported “hyperplasia” and no endometrial cancer from **Table 3** is not sufficient for the outcome prediction for long time. Molecular genetic researches related to hereditary predisposition (as Lynch syndrome, and Cowden syndrome) and to epigenetic changes are now used for uterine structures too, and endometrial transcriptome is more and more understood.

There are histological biomarkers for endometrial transcriptome assessment: estrogen (ER), progesterone (PR) receptors, membrane estrogen and progesterone receptors, and their polymorphism; enzymes involved in E2 metabolism to E1, and other molecules as bcl-2, p53, PAX-2, PTEN, VEGF, and microRNA (miRNA) can help to make the differences in the outcome of each patient. The proliferative activity induced by estrogen increases the risk for errors in transcription (microsatellite instability, K-ras mutation, PTEN gene mutations), which are essential for carcinogenesis [128]. Microsatellite instability (MSI) is a condition manifested by damaged DNA because of defects in normal DNA repair process; it induces progression of hyperplasia with atypia to endometrioid endometrial carcinoma—reported to be 20–45% in such cases, and 0–11% in type 2 endometrial carcinoma.

Estrogen may operate through “classical” genomic pathways (*via* nuclear ERs) or non-genomic pathways (ERs in plasma membrane/cytoplasm or other receptors/adaptors). Approximately 10% of the patients with type 1 endometrial cancer show gene defects promoting carcinogenesis; one representative example is hereditary non-polyposis colon cancer (HNPCC), known as Lynch syndrome [129] when the lifetime risk for endometrial cancer is 40–60% [130].

miRNAs are short (19–25 nucleotides) naturally-occurring, non-coding RNA molecules that base-pair with the 3' untranslated region of target mRNAs. miRNAs have emerged as key regulators of gene expression, a single miRNA can target

and potentially silence several hundred genes, and their involvement in aging by modulating the presence of steroid receptors, and other molecules in endometrial disorders, as are EIN, and both types of endometrial cancer. Recent studies have identified miRNAs regulated by estrogens in human endometrial stromal cells [131], fact discussed because E2 levels decline in postmenopause, and are various age-associated disorders.

Endometrial transcriptome analysis using techniques of immunohistochemistry may reveal women's risk to progesterone/progestin resistance and progression to EIN by measuring PRA and PRB; high expression of PRA and PRB suggesting decreased risk of persistence/progression to EIN, and the decrease of PRB is strongly associated to progression to EIN. No association was found with PTEN, and PTEN mutations, Pax-2, and Bcl-2, insulin like-growth factor II, with complex hyperplasia [132].

#### **4. Conclusions: future perspectives for middle aged women treated for perimenopausal symptoms**

The discussed non-oral routes of MHT, meaning the transdermal/percutaneous route for estrogens, the vaginal route for micronized progesterone, and intrauterine system for progesterone/progestogen are an update safe option for women with intact uterus, when the recommendation for MHT is during the "window of opportunity". The technology of obtaining these drugs/system will help medical staff and middle aged women to have a better quality of life, and less morbidity and mortality. The risk of endometrial proliferative lesions as hyperplasia and carcinoma is reduced in comparison to non-user women, and their prognosis is better comparative to non-users regarding tumor aggression and women's survival. Endometrial transcriptome and new biomarkers highlight priority areas for future research, such as increasing the diagnostic reproductibility of endometrial hyperplasia-benign, and EIN and to improve the discrimination between EIN and carcinoma, and identifying new biomarkers to stratify risks or serve as indicators of response to clinical treatment.

#### **Conflict of interest**

Nothing to disclaim.

#### **Thanks**

I thank Romanian patients who trust on my recommendations regarding non oral routes for MHT, when the majority used the oral route.

## **Author details**

Manuela Cristina Russu

“Dr. I. Cantacuzino” Discipline of Obstetrics and Gynecology, “Carol Davila”  
University of Medicine and Pharmacy, Bucharest, Romania

\*Address all correspondence to: manuela\_russu@yahoo.com

## **IntechOpen**

---

© 2019 The Author(s). Licensee IntechOpen. This chapter is distributed under the terms of the Creative Commons Attribution License (<http://creativecommons.org/licenses/by/3.0>), which permits unrestricted use, distribution, and reproduction in any medium, provided the original work is properly cited. 

## References

- [1] Harlow DS, Gass M, Hall EJ, Lobo R, Maki P, Rebar WR, et al. For the STRAW +10. Executive summary of the stages of reproductive aging workshop +10. Addressing the unfinished agenda of staging reproductive aging. *The Journal of Clinical Endocrinology & Metabolism*. 2012;**97**(2):1159-1168. DOI: 10.1210/jc.2011-3362
- [2] Santoro N. Perimenopause: From research to practice. *Journal of Women's Health*. 2016;**25**(4):332-339. DOI: 10.1089/jwh.2015.5556
- [3] Santoro N, Chervenak JL. The menopause transition. *Endocrinology and Metabolism Clinics of North America*. 2004;**33**(4):627-636
- [4] Lobo AR. Where are we 10 years after the Women's Health Initiative? *The Journal of Clinical Endocrinology & Metabolism*. 2013;**98**(5):1771-1780
- [5] Nelson HD. Commonly used types of postmenopausal estrogen for treatment of hot flashes: Scientific review. *JAMA*. 2004;**291**(13):1610-1620
- [6] Carroll N. A review of transdermal nonpatch estrogen therapy for the management of menopausal symptoms. *Journal of Women's Health*. 2010;**19**(1):47-55. DOI: 10.1089/jwh.2008.120
- [7] Manson JE. The role of personalized medicine in identifying appropriate candidates for menopausal estrogen therapy. *Metabolism*. 2013;**62**(Suppl 1):S15-S19. DOI: 10.1016/j.metabol.2012.08.015
- [8] Henzi MR. Optimizing delivery of therapeutics: Percutaneous technologies. *Bratislavské Lekárske Listy*. 2002;**103**(4-5):144-151
- [9] Egras AM, Umland EM. The role of transdermal estrogen sprays and estradiol topical emulsion in the management of menopause-associated vasomotor symptoms. *International Journal of General Medicine*. 2010;**3**:147-151
- [10] Simon JA, ESTRASORB Study Group. Estradiol in micellar nanoparticles: The efficacy and safety of a novel transdermal drug-delivery technology in the management of moderate to severe vasomotor symptoms. *Menopause*. 2006;**13**(2):222-231
- [11] Valenzuela P, Simon JA. Nanoparticle delivery for transdermal HRT. *Nanomedicine*. 2012;**8**(Suppl 1):S83-S89. DOI: 10.1016/j.nano.2012.05.008
- [12] Gleason CE, Carlsson CM, Johnson S, Atwood C, Asthana S. Clinical pharmacology and differential cognitive efficacy of estrogen preparation. *Annals of the New York Academy of Sciences*. 2005;**1052**:93-115
- [13] Campagnoli C, Ambroggio S, Biglia N, Sismondi P. Conjugated estrogens and breast cancer risk. *Gynecological Endocrinology*. 1999;**13**(Suppl 6):13-19
- [14] Kopper WN, Gudman J, Thompson JD. Transdermal hormone therapy in postmenopausal women: A review of metabolic effects and drug delivery technologies. *Drug Design, Development and Therapy*. 2008;**2**:193-202
- [15] Cintron D, Lipford M, Larrea-Mantilla L, Spencer-Bonilla G, Lloyd R, Gionfriddo MR, et al. Efficacy of menopausal hormone therapy on sleep quality: Systematic review and meta-analysis. *Endocrine*. 2017;**55**(3):702-711
- [16] Fait T, Fialova A, Pastor Z. The use of estradiol metered-dose transdermal spray in clinical practice. *Climacteric*. 2018 Dec;**21**(6):549-553. DOI: 10.1080/13697137.2018.1504916

- [17] The North American Menopause Society. The 2012 hormone therapy position statement of the North American menopause society. *Menopause*. 2012;**19**(3):257-271. DOI: 10.1097/gme.0b013e31824b970a
- [18] Renoux C, Dell’aniello S, Garbe E, Suissa S. Transdermal and oral hormone replacement therapy and the risk of stroke: A nested case control study. *BMJ*. 2010;**340**:c2519
- [19] Scarabin PY, Oger E, Plu-Bureau G, on behalf of the Estrogen and Thrombo Embolism Risk (ESTHER) Study Group. Differential association of oral and transdermal oestrogen-replacement therapy with venous thromboembolism risk. *Lancet*. 2003;**362**:428-432
- [20] Canonico M, Carcaillon L, Plu-Bureau G, Oger E, Singh-Manoux A, Tubert-Bitter P, et al. Postmenopausal hormone therapy and risk of stroke impact of the route of estrogen administration and type of progestogen. *Stroke*. 2016;**47**:1734-1741. DOI: 10.1161/STROKEAHA.116.01.3052
- [21] Canonico M, Plu-Bureau G, Lowe GD, Scarabin PY. Hormone replacement therapy and risk of venous thromboembolism in postmenopausal women: Systematic review and meta-analysis. *BMJ*. 2008;**336**:1227-1231
- [22] Goodman PM. Are all estrogens created equal? A review of oral vs. transdermal therapy. *Journal of Women’s Health*. 2012;**21**(2):161-169. DOI: 10.1089/jwh.2011.2839
- [23] Crandal JC, Hovey MK, Andrews C, Cantly AJ, Stefanick M, Shufelt C, et al. Comparison of clinical outcomes among users of oral and transdermal estrogen therapy in the women’s health initiative observational study. *Menopause*. 2017;**24**(10):1145-1153. DOI: 10.1097/GME:0000000000000899
- [24] Fournier A, Mesrine S, Dossus L, Boutron-Ruault MC, Clavel-Chapelon F, Chabbert-Buffet N. Risk of breast cancer after stopping menopausal hormone therapy in the E3N cohort. *Breast Cancer Research and Treatment*. 2014;**145**:535-543. DOI: 10.1007/s10549-014-2934-6
- [25] Simon J, Nachtigall L, Ulrich LG, Eugster-Hausmann M, Gut R. Endometrial safety of ultra-low-dose estradiol vaginal tablets. *Obstetrics and Gynecology*. 2010;**116**(4):876-883. DOI: 10.1097/AOG.0b013e3181f386bb
- [26] Ulrich L, Naessen T, Elia D, Goldstein JA, Eugster-Hausmann M. Vag-1748 trial investigation-endometrial safety of ultra-low-dose Vagifem 10 microg in postmenopausal women with vaginal atrophy. *Climacteric*. 2010;**13**(3):228-237. DOI: 10.3109/13697137.2010.481058
- [27] Russu M, Mubarak N, Marin JA, Hudiță D. Quality of life improvement after vaginal treatment of urogenital atrophy symptoms in postmenopause. “Securing a healthy future to day”. In: *Proceedings of the 8th European Congress on Menopause (EMAS)*, London, UK, May, 16-20, 2009
- [28] Panay N, Hamoda H, Arya R, Savvas M, on behalf of The British Menopause Society and Women’s Health Concern—The. *British Menopause Society & Women’s Health Concern recommendations on hormone replacement therapy. The Menopause International*. 2013;**19**(2):59, 2013-68. DOI: 10.1177/1754045313489645
- [29] Hamoda H, Panay N, Arya R, Savvas M. The British Menopause Society & Women’s Health Concern 2016 recommendations on hormone replacement therapy in menopausal women. *PostReproductive Health*. 2016;**22**(4):165-183. DOI: 10.1177/2053369116680501



- [30] Loose DS, Stancel GM. Estrogens and progestins. In: Brunton LL, editor. *Godman & Gilman's the Pharmacological Basis of Therapeutics*. 11th ed. New York, NY: McGraw-Hill; 2006. pp. 1541-1571
- [31] Wiegratz I, Kuhl H. Progestogen therapies: Differences in clinical effects? *Trends in Endocrinology and Metabolism*. 2004;**15**(6):277-285. DOI: 10.1016/j.tem.2004.06.006
- [32] Kurman RJ, Kaminski PF, Norris HJ. The behavior of endometrial hyperplasia. A long-term study of untreated hyperplasia in 170 patients. *Cancer*. 1985;**56**:403-412
- [33] Figueroa Casas PR, Ettiger B, Delgado E, Jaykin A, Vieder C. Reversal by medical treatment of endometrial hyperplasia caused by estrogen replacement therapy. *Menopause*. 2001;**8**(6):420-423
- [34] Nahoul K, Dehennin L, Scholler R. Radioimmunoassay of plasma progesterone after oral administration of micronized progesterone. *Journal of Steroid Biochemistry*. 1987;**26**:241-249
- [35] Hargrove JT, Maxson WS, Wentz AC. Absorption of oral progesterone is influenced by vehicle and particle size. *American Journal of Obstetrics and Gynecology*. 1989;**161**:948-951
- [36] Price JH, Ismail H, Gorwill RH, Sarda IR. Effect of the suppository base on progesterone delivery from the vagina. *Fertility and Sterility*. 1983;**39**:490-493
- [37] Cicinelli E, de Ziegler D. New hypotheses transvaginal progesterone: Evidence for a new functional 'portal system' flowing from the vagina to the uterus. *Human Reproduction Update*. 1999;**5**(4):365-372
- [38] de Ziegler D. Hormonal control of endometrial receptivity. *Human Reproduction*. 1995;**10**:4-7
- [39] Cicinelli E, Schonauer LM, Galantino P, Matteo MG, Cassetta R, Pinto V. Mechanisms of uterine specificity of vaginal progesterone. *Human Reproduction*. 2000;**15**(Suppl. 1):159-165
- [40] Cicinelli E, Cignarelli M, Resta L, Scordia P, Petruzzi D, Santoro G. Effects of the repetitive administration of progesterone by nasal spray in postmenopausal women. *Fertility and Sterility*. 1993;**60**:1020-1024
- [41] Villanueva B, Casper RF, SCC Y. Intravaginal administration of progesterone: Enhanced absorption after estrogentreatment. *Fertility and Sterility*. 1981;**35**:433-437
- [42] Cicinelli E, de Ziegler D, Alfonso R, Nicoletti R, Bellavia M, Colafiglio G. Endometrial effects, bleeding control, and compliance with a new postmenopausal hormone therapy regimen based on transdermal estradiol gel, and every-other-day vaginal progesterone in capsules: A 3-year pilot study. *Fertility and Sterility*. 2005;**83**:1859-1863
- [43] Ruan X, Mueck AO. Systemic progesterone therapy—Oral, vaginal, injections and even transdermal? *Maturitas*. 2014;**79**:248-255
- [44] Stute P, Neulen J, Wildt L. The impact of micronized progesterone on the endometrium: A systematic review. *Climacteric*. 2016;**7137**:1-13
- [45] Somboonporn W, Panna S, Temtanakitpaisan T, Kaewrudee S, Soontrapa S. Effects of the levonorgestrel releasing intrauterine system plus estrogen therapy in perimenopausal and postmenopausal women. Systematic review and meta-analysis. *Menopause*. 2011;**18**(10):1060-1066
- [46] Knauer E. Die ovarien transplantation. *Experimentelle Studie*

- Arch Gynaek. 1900;**60**:322, cited by Van Gorp T, 2002 [49]
- [47] Murray WS. Ovarian secretion and tumor incidence. *Science*. 1927;**66**: 600-601, cited by Van Gorp T, 2002
- [48] Dockerty MB, Massey E. Malignant lesions of the uterus associated with estrogen-producing ovarian tumors. *American Journal of Obstetrics and Gynecology*. 1951;**61**:147-150, cited by Van Gorp T, 2002
- [49] Lilienfield AM, Johnson EA. The age distribution in female breast and genital cancers. *Cancer*. 1955;**8**:875-881
- [50] Van Gorp T, Neven P. Endometrial safety of hormone replacement therapy: Review of literature. *Maturitas*. 2002;**42**:93-104
- [51] Kelly RM, Baker WH. Progesterone for endometrial cancer. *New England Journal of Medicine*. 1961;**246**:216-220
- [52] Gusberg SB. Precursors of corpus carcinoma-estrogens and adenomatous hyperplasia. *American Journal of Obstetrics and Gynecology*. 1947;**54**:905-907
- [53] Jensen EI, Oestergaard E. Clinical studies concerning the relationship of estrogens to the development of cancer of the corpus uteri. *American Journal of Obstetrics and Gynecology*. 1954;**67**:1094-1102
- [54] Constantine GD, Kessler G, Graham S, Goldstein SR. Increased incidence of endometrial cancer following the WHI: An assessment of risk factors. *Journal of Women's Health*. 2019;**28**(2):237-243. DOI: 10.1089/jwh.2018.6956
- [55] American Cancer Society. Endometrial cancer causes, risk factors, and prevention. Available at: <https://www.cancer.org/content/dam/CRC/PDF/Public/8610.00.pdf>. [Accessed: 27 November 2017]
- [56] Wartko P, Sherman ME, Yang HP, Felix AS, Brinton LA, Trabert B. Recent changes in endometrial cancer trends among menopausal-age U.S. women. *Cancer Epidemiology*. 2013;**37**:374-377
- [57] Dezman VL, Gersak MZ, Gersak K. Two case of atypical endometrial hyperplasia associated with "bioidentical" hormone replacement therapy: IGCS-0084 Uterine Cancer, including Sarcoma. *International Journal of Gynecological Cancer*. 2015;**25**(Suppl 1):71
- [58] Eden JA, Hacker NF, Fortune M. Three cases of endometrial cancer associated with "bioidentical" hormone replacement therapy. *The Medical Journal of Australia*. 2007;**187**:244-245
- [59] Gass ML, Stuenkel CA, Utian WH, LaCroix A, Liu JH, Shifren JL. Use of compounded hormone therapy in the United States: Report of the North American Menopause Society survey. *Menopause*. 2015;**22**:1276-1284
- [60] American College of Obstetricians and Gynecologists Committee on Gynecologic Practice, American Society for Reproductive Medicine Practice Committee. Compounded bioidentical menopausal hormone therapy. *Fertility and Sterility*. 2012;**98**:308-312
- [61] Beral V, Bull D, Reeves G. Million women study C. Endometrial cancer and hormone-replacement therapy in the million women study. *Lancet*. 2005;**365**(9470):1543-1551
- [62] Allen NE, Tsilidis KK, Key TJ, Dossus L, Kaaks T, Riboli E, et al. Menopausal hormone therapy and risk of endometrial carcinoma among postmenopausal women in the European Prospective Investigation Into Cancer and Nutrition. *American Journal of Epidemiology*. 2010;**172**(12): 1394-1403. DOI: 10.1093/aje/kwq300
- [63] Trabert B, Wentzensen N, Yang HP, Sherman ME, Hollenbeck AR,

- Park Y, et al. Is estrogen plus progestin menopausal hormone therapy safe with respect to endometrial cancer risk? *International Journal of Cancer*. 2013;**132**(2):417-426. DOI: 10.1002/ijc.27623
- [64] Chlebowski RT, Anderson GL, Sarto GE, Aragaki AK, Haque R, Runowicz CD. Continuous combined estrogen plus progestin and endometrial cancer: The women's health initiative randomized trial. *Journal of the National Cancer Institute*. 2016;**108**(3):1-10
- [65] Razavi P, Pike CM, Horn-Ross P, Templeman C, Bernstein L, Ursin G. Long-term postmenopausal hormone therapy and endometrial cancer. *Cancer Epidemiology, Biomarkers & Prevention*. 2010;**19**(2):475. DOI: 10.1158/1055-9965.EPI-09-0712
- [66] Li M, Guo T, Cui R, Feng Y, Bai H, Zhang Z. Weight control is vital for patients with early-stage endometrial cancer or complex atypical hyperplasia who have received progestin therapy to spare fertility: A systematic review and meta-analysis. *Cancer Management and Research*. 2019;**11**:4005-4021. DOI: 10.2147/CMAR.S194607
- [67] Arthur R, Kirsh VA, Kreiger N, Rohan T. A healthy lifestyle index and its association with risk of breast, endometrial, and ovarian cancer among Canadian women. *Cancer Causes & Control*. 2018;**29**(6):485-493. DOI: 10.1007/s10552-018-1032-1
- [68] Arthur R, Brasky TM, Crane TE, Felix AS, Kaunitz AM, Shadvab AH, et al. Associations of a healthy lifestyle index with the risks of endometrial and ovarian cancer among women in the women's health initiative study. *American Journal of Epidemiology*. 2019;**188**(2):261-273. DOI: 10.1093/aje/kwy249
- [69] Sturdee DW, Barlow HD, Ulrich L, Gydesen H, Wells M, Campbell JM, et al. Is the timing of withdrawal bleeding a guide to endometrial safety during sequential oestrogen-progestogen replacement therapy? *The Lancet*. 1994;**344**:979-982. DOI: 10.1016/S0140-6736(94)91640-3
- [70] Stovall TG, Solomon SK, Ling FW. Endometrial sampling prior to hysterectomy. *Obstetrics & Gynecology*. 1989;**73**(3, Part 1):405-409
- [71] Ettinger B, Selby J, Citron JT, Vangessel A, Ettinger VM, Hendrickson MR. Cyclic hormone replacement therapy using quarterly progestin. *Obstetrics and Gynecology*. 1994;**83**:693-700
- [72] Boerrigter PJ, van de Weiner PH, Baak JP, Fox H, Haspels AA, Kenemabs P. Endometrial response in estrogen replacement therapy quarterly combined with a progestogen. *Maturitas*. 1996;**24**(1-2):63-71
- [73] Bjarnason K, Certin A, Lindgren R, Weber T. Adverse endometrial effects during long cycle hormone replacement therapy. *Scandinavian Long Cycle Study Group. Maturitas*. 1999;**32**(3):161-170
- [74] Jaakkola S, Lyytinen H, Dyba T, Ylikorkala O, Pukkala E. Endometrial cancer associated with various forms of postmenopausal hormone therapy: A case control study. *International Journal of Cancer*. 2011;**128**(7):1644-1651. DOI: 10.1002/ijc.25762
- [75] Fernandez-Munga L, Hermenegildo C, Tarin JJ, Garcia-Perez M-A, Cano A. Endometrial response to concurrent treatment with vaginal progesterone and transdermal estradiol. *Climacteric*. 2012;**15**(5):455-459
- [76] Pukkala E, Tulenheimo-Silfvast A, Leminen A. Incidence of cancer among women using long versus monthly cycle hormonal replacement therapy, Finland

- 1994-1997. *Cancer Causes & Control*. 2001;**12**:111-115
- [77] Pukkala E, Rautalahti M. *Cancer in Finland*. Cancer Society of Finland; 2013. ISBN: 978-952-5815-16-0
- [78] Thomas MA, Hickeys M, Fraser SI. Disturbances of endometrial bleeding with hormone replacement therapy. *Human Reproduction*. 2000; **15**(Suppl. 3):7-17
- [79] Padwick ML, Pryse-Davies J, Whitehead MI. A simple method for determining the optimal dose of progestin in postmenopausal women receiving estrogens. *New England Journal of Medicine*. 1989;**1**:163-164
- [80] Sturdee DW, Ulrich L, Barlow HD, Campbell JM, Vessey PM, Nielsen B, et al. The endometrial response to sequential and continuous combined oestrogen-progestogen replacement therapy. *BMJ*. 2005;**107**(11):1392-1400. DOI: 10.1111/j.1471-0528.2000.tb11654.x
- [81] Whitehead MI, Hillard TC, Crook D. The role and use of progestogens. *Obstetrics & Gynecology*. 1990;**75**(4 (suppl)):59S-79S
- [82] Di Carlo C, Tommaselli GA, Gargano V, Savoia F, Bifulco G, Nappi C. Transdermal estradiol and oral or vaginal natural progesterone: Bleeding patterns. *Climacteric*. 2010;**13**(5): 442-446. DOI: 10.3109/13697137.2010.490605
- [83] Archer DF, Pickar JH, Bottiglioni F. Bleeding patterns in postmenopausal women taking continuous combined or sequential regimens of conjugated estrogens with medroxyprogesterone acetate. *Obstetrics and Gynecology*. 1994;**83**:686-692
- [84] Agarwal S, Alzahrani FA, Ahmed A. Hormone replacement therapy: Would it be possible to replicate a functional ovary? *International Journal of Molecular Sciences*. 2018;**19**(10), pii: E3160. DOI: 10.3390/ijms19103160
- [85] Archer D. The effect of the duration of progestin use on the occurrence of endometrial cancer in postmenopausal women. *Menopause*. 2001;**8**(4):245-251
- [86] Cerin A, Heldaas K, Moeller B. Adverse endometrial effects of long-cycle estrogen and progestogen replacement therapy. The Scandinavian Long-Cycle Study Group. *New England Journal of Medicine*. 1996;**334**:668-669
- [87] Furness S, Roberts H, Marjoribanks J, Lethaby A, Hickey M, Farquar C. Hormone therapy in postmenopausal women and risk of endometrial hyperplasia. *Cochrane Database of Systematic Reviews*. 2009;**15**(2):CD000402. DOI: 10.1002/14651858.CD000402.pub3
- [88] Furness S, Roberts H, Marjoribanks J, Lethaby A. Hormone therapy in postmenopausal women and risk of endometrial hyperplasia. *Cochrane Database of Systematic Reviews*. 2012;**15**(8):CD000402. DOI: 10.1002/14651858.CD000402.pub4
- [89] Leonetti HB, Landes J, Steinberg D, Anasti JN. Transdermal progesterone cream as an alternative progestin in hormone therapy. *Alternative Therapies in Health and Medicine*. 2005;**11**:36-38
- [90] Wren BG. Transdermal progesterone creams for postmenopausal women: More hype than hope. *Medical Journal of Australia*. 2005;**182**(5):237-239
- [91] Leather AT, Savvas M, Studd JW. Endometrial histology and bleeding patterns after 8 years of continuous combined estrogen and progestogen therapy in postmenopausal women. *Obstetrics and Gynecology*. 1991;**78**:1008-1010

- [92] Widemeersch D, Janssens D, Pyllyer K, De Wever N, Verbeek G, Dhont M, et al. Management of patients with non-atypical and atypical endometrial hyperplasia with a levonorgestrel-releasing intrauterine system: Long-term follow-up. *Maturitas*. 2007;57(2):210-213. DOI: 10.1016/j.maturitas.2006.12.004
- [93] Hirvonen E, Cacciatore B, Wahlström TT, Rita H, Wilén-Rosenqvist G. Effects of transdermal oestrogen therapy in postmenopausal women: A comparative study of an E2 gel and an E2 delivering patch. *British Journal of Obstetrics and Gynaecology*. 1997;104(S16):21-31
- [94] Feeley KM, Wells M. Hormone replacement therapy and the endometrium. *BMJ*. 2001;54(6):435-440. DOI: 10.1136/jcp.54.6.435
- [95] Davies GC, Huster WJ, Shen W, Mitlak B, Plouffe L Jr, Cohen FJ, et al. Endometrial response to raloxifene compared with placebo, cyclical hormone replacement therapy, and unopposed estrogen in postmenopausal women. *Menopause*. 1999;6:188-195
- [96] Vashisht A, Wadsworth F, Carey A, Carey B, Studd J. Bleeding profiles and effects on the endometrium for women using a novel combination of transdermal oestradiol and natural progesterone cream as part of a continuous combined hormone replacement regime. *BJOG*. 2005;112:1402-1406
- [97] Archer DF, Furst K, Tipping D, Dain MP, Vandepol C. A randomized comparison of continuous combined transdermal delivery of estradiol-norethindrone acetate and estradiol alone for menopause. *CombiPatch Study Group. Obstetrics & Gynecology*. 1999;94:498-503
- [98] Ylikorkala O, Rozenberg S. Efficacy and tolerability of fully transdermal hormone replacement in sequential or continuous therapy at two doses of progestogen in postmenopausal women. *Maturitas*. 2000;37(2):83-93
- [99] Shulman LP, Yankov V, Uhl K. Safety and efficacy of a continuous once-a-week 17beta-estradiol/levonorgestrel transdermal system and its effects on vasomotor symptoms and endometrial safety in postmenopausal women: The results of two multicenter, double-blind, randomized, controlled trials. *Menopause*. 2002;9(3):195-207
- [100] Sturdee DW, van de Weijer P, von Holst T. Endometrial safety of a transdermal sequential estradiol-levonorgestrel combination. *Climacteric*. 2002;5(2):170-177
- [101] Dando TM, Perry CM. 17 beta-estradiol/levonorgestrel transdermal system. *Treatments in Endocrinology*. 2004;3(5):319-324
- [102] Samsioe G, Dvorak V, Genazzani AR, Mueck AO, Arguinzoniz M, et al. One-year endometrial safety evaluation of a continuous combined transdermal matrix patch delivering low-dose estradiol-norethisterone acetate in postmenopausal women. *Maturitas*. 2007;57(2):171-181
- [103] Russu M, Terzea D, Hudiță D. Endometrial histology and safety after a novel regimen with transdermal estrogen and vaginal micronized progesterone. Two years of monitoring. *Maturitas*. 2009;63(Supplement 1) Abstracts Book ISSN 0378-5122., "Securing a healthy future to day" to The 8th European Congress on Menopause (EMAS), London, UK, 16-20 May 2009
- [104] Deligdish L. Hormonal pathology of the endometrium. *Modern Pathology*. 2000;13:285-294
- [105] Owings RA, Quick CM. Endometrial intraepithelial neoplasia.

Archives of Pathology & Laboratory Medicine. 2014;**138**:484-491

[106] Mutter GL. Endometrial intraepithelial neoplasia (EIN): Will it bring order to chaos? The Endometrial Collaborative Group. *Gynecologic Oncology*. 2000;**76**:287-290

[107] Dietel M. The histological diagnosis of endometrial hyperplasia. Is there a need to simplify? *Virchows Archiv*. 2001;**439**(5):604-608

[108] Piegsa K, Calder A, Davis JA, McKay-Hart D, Wells M, Bryden F. Endometrial status in post-menopausal women on long-term continuous combined hormone replacement therapy (Kliofem). A comparative study of endometrial biopsy, outpatient hysteroscopy and transvaginal ultrasound. *European Journal of Obstetrics, Gynecology, and Reproductive Biology*. 1997;**72**:175-180

[109] Mutter GL. Diagnosis of premalignant endometrial disease. *Journal of Clinical Pathology*. 2002;**55**(5):326-331

[110] Silverberg GS, Kurman RJ, Nogales F, Mutter GL, Kubik-Huck A, Tavassoli AF. Epithelial tumors and related lesions, Pathology and Genetics of Tumors of the Breast and Female Organs, Devilee P, Tavassoli AF, IARC Press, Lyon, France, 2003

[111] Bokhman JV. Two pathogenetic types of endometrial carcinoma. *Gynecologic Oncology*. 1983;**15**:10-17

[112] Murali R, Davidson B, Fadare O, Carlson JA, Crum CP, Gilks CB, et al. High-grade endometrial carcinomas: Morphologic and immunohistochemical features, diagnostic challenges and recommendations. *International Journal of Gynecologic Pathology*. 2019;**38**(Suppl 1):S40-S63. DOI: 10.1097/PGP.0000000000000491

[113] Rabban JT, Gilks CB, Malpica A, Matias-Guiu X, Mittal K, Mutter GL, et al. Issues in the differential diagnosis of uterine low-grade endometrioid carcinoma, including mixed endometrial carcinomas: Recommendations from the international society of gynecological pathologists. *International Journal of Gynecologic Pathology*. 2019;**38**(Suppl 1):S25-S39. DOI: 10.1097/PGP.0000000000000512

[114] Levine RL, Cargile CB, Blazes MS, van Rees B, Kurman RJ, Ellenson LH. *PTEN* mutations and microsatellite instability in complex atypical hyperplasia, a precursor lesion to uterine endometrioid carcinoma. *Cancer Research*. 1998;**58**:3524-3528

[115] Mutter GL. PTEN, a protean tumor suppressor. *The American Journal of Pathology*. 2001;**158**:1895-1898

[116] Mutter GL, Zaino RJ, Robboy SJ, et al. Benign endometrial hyperplasia sequence and endometrial intraepithelial neoplasia. *International Journal of Gynecological Pathology*. 2007;**26**(2):103-114

[117] Zheng W, Khurana R, Felix JC, et al. p53 immunostaining as a significant adjunct diagnostic method for uterine surface carcinoma. *The American Journal of Surgical Pathology*. 1998;**22**:163-173

[118] Sherman ME. Theories of endometrial carcinogenesis: A multidisciplinary approach. *Modern Pathology*. 2000;**13**:295-308

[119] Soslow RA, Tornos C, Park KJ, Malpica A, Matias-Guiu X, Oliva E, et al. Endometrial carcinoma diagnosis: Use of FIGO grading and genomic subcategories in clinical practice: Recommendations of the International Society of Gynecological Pathologists. *International Journal of Gynecologic Pathology*.

2019;**38**(Suppl 1):S64-S74. DOI: 10.1097/PGP.0000000000000518

[120] Royal College of Obstetricians and Gynecologists, British Society for Gynecological Endoscopy—Management of Endometrial Hyperplasia, Green-Top Guideline No 67. 2016

[121] Wells M, Sturdee DW, Barlow DH, Ulrich LG, O'Brien K, Campbell MJ, et al. Effect on endometrium of long term treatment with continuous combined oestrogen-progestogen replacement therapy: Follow up study. *British Medical Journal*. 2002;**325**(7358):239

[122] The Writing Group for the PEPI Trial. Effects of hormone replacement therapy on endometrial histology in postmenopausal women. The Postmenopausal Estrogen/Progestin Interventions (PEPI) Trial. The Writing Group for the PEPI Trial. *JAMA*. 1996;**275**(5):370-375

[123] Salman MC, Usubutun A, Boynukalin K, Yuce K. Comparison of WHO and endometrial intraepithelial neoplasia classifications in predicting the presence of coexistent malignancy in endometrial hyperplasia. *Journal of Gynecologic Oncology*. 2010;**21**(2):97-101

[124] Lacey JV Jr, Chia VM. Endometrial hyperplasia and the risk of progression to carcinoma. *Maturitas*. 2009;**63**(1):39-44. DOI: 10.1016/j.maturitas.2009.02.005

[125] Ambros RA, Sherman ME, Zahn CM, Bitterman P, Kurman RJ. Endometrial intraepithelial carcinoma: A distinctive lesion specifically associated with tumors displaying serous differentiation. *Human Pathology*. 1995;**26**:1260-1267

[126] Felix SA, Arem H, Trabert B, Gierach LG, Park Y, Pfeiffer MR, et al. Menopausal hormone therapy and

mortality among endometrial cancer patients in the NIH-AARP Diet and Health Study. *Cancer Causes Control*. 2015;**26**(8):1055-1061. DOI: 10.1007/s10552-0598-0

[127] Orgéas CC, Hall P, Wedrén S, Dickman PW, Czene K. The influence of menopausal hormone therapy on tumour characteristics and survival in endometrial cancer patients. *European Journal of Cancer*. 2009;**45**(17):3064-3073. DOI: 10.1016/j.ejca.2009.05.012

[128] Samarnthai N, Hall K, Yeh T. Molecular profiling of endometrial malignancies. *Obstetrics and Gynecology International*. 2010, Article ID 162363, 16 pages. DOI: 10.1155/2010/162363

[129] Chen LM, Yang KY, Little SE, Cheung MK, Caughey AB. Gynecologic cancer prevention in Lynch syndrome/ hereditary nonpolyposis colorectal cancer families. *Obstetrics and Gynecology*. 2007;**110**:18-25

[130] Tinelli A, Vergara D, Martignago R, Leo G, Tinelli R. Hormonal carcinogenesis and socio-biological development factors in endometrial cancer: A clinical review. *Acta Obstetrica et Gynecologica*. 2008;**87**:11011113

[131] Klinge CM. Estrogen regulation of microRNA expression. *Current Genomics*. 2009;**10**(3):169-183

[132] Upson K, Allison K, Reed S, Jordan C, Newton K, Swisher E, et al. Biomarkers of progestin therapy resistance and endometrial hyperplasia progression. *American Journal of Obstetrics and Gynecology*. 2012;**207**(1):36e1-36e8