
Differentiated Thyroid Carcinoma with Elevated Thyroglobulin and Negative Radioiodine Whole-Body Scan Metastases

Chao Ma

Additional information is available at the end of the chapter

<http://dx.doi.org/10.5772/64356>

Abstract

Serum thyroglobulin (Tg) and Tg antibody (TgAb) levels, together with neck ultrasonography and ^{131}I whole-body scintigraphy (WBS), are diagnostic tools for postoperative follow-up of patients with differentiated thyroid carcinoma (DTC). Generally, good correlation is seen between Tg and WBS in follow-up studies for DTC after thyroid remnant ablation. Undetectable serum Tg with negative WBS results suggests complete remission, whereas detectable, or elevated, serum Tg is associated with radioiodine uptake in local or distant metastases. Patients with thyroid cancer cells lacking radioiodine uptake despite an elevated serum Tg level have been referred to as WBS-negative, Tg-positive patients, who represent 10–15% of cases. ^{18}F -FDG PET (FDG-PET) scanning should be considered in high-risk DTC patients with negative WBS and positive Tg. The preferred therapeutic hierarchy for Tg-positive and WBS-negative metastases is surgical excision of loco-regional disease, ^{131}I therapy for radioiodine-responsive disease, external beam radiation, TSH suppression, and systemic therapy with kinase inhibitors. If FDG-PET diagnostic results are negative, one course of ^{131}I treatment may be considered in high-risk patients and individualized. No further ^{131}I therapy is indicated for patients with a negative post-therapy WBS.

Keywords: differentiated thyroid carcinoma, thyroglobulin, whole-body scan, radioiodine

1. Introduction

Serum thyroglobulin (Tg) is a tissue-specific 660 kDa protein that serves as a precursor in thyroid hormone biosynthesis [1]. It is synthesized by both thyroid follicular cells and

differentiated cancer cells. Monitoring of serum Tg and Tg antibody (TgAb) levels, together with neck ultrasonography and ^{131}I whole-body scintigraphy (WBS), is used as a diagnostic tool in postoperative follow-up for patients with differentiated thyroid carcinoma (DTC) [2]. Generally, good correlation is seen between Tg and WBS in follow-up studies for DTC after thyroid remnant ablation [3]. Undetectable serum Tg with negative WBS results suggests complete remission, whereas detectable, or elevated, serum Tg is associated with radioiodine uptake in local or distant metastases. Patients with thyroid cancer cells lacking radioiodine uptake despite their elevated serum Tg level have been referred to as WBS-negative, Tg-positive patients [3]. The possible explanations and management for the discordant finding are discussed in this chapter.

2. Description of DTC with elevated Tg level and negative WBS

Tg is a thyroid tissue-specific antigen produced by thyroid follicular cells. Its measurement is the best sign of detecting thyroid tissue, including metastasis of DTC. After a total thyroidectomy and radioiodine ablation, any detectable Tg is interpreted as recurrent disease. Although it is a highly sensitive and specific marker of recurrence, Tg measurement cannot locate the recurrent DTC [4, 5]. Imaging technologies, including WBS, ultrasonography, computed tomography (CT), and magnetic resonance imaging (MRI), play great role in locating the DTC metastases. Tg is a very sensitive marker for thyroid malignancy, and it is not uncommon to encounter patients who show at initial follow-up, detectable Tg levels with negative imaging studies [6]. Patients with thyroid cancer cells lacking radioiodine uptake on WBS despite their elevated serum Tg level have been referred to as WBS-negative, Tg-positive patients; they represent 10–15% of patients with DTC at follow-up. Due to its inferior sensitivity, the routine WBS has been supplanted by serum Tg and neck ultrasonography, CT and/or MRI. The reasons for raised Tg and negative scan results have been summarized previously [7]. The elevated Tg level and negative WBS are classified into “true-negative WBS with false-positive Tg” and “false-negative WBS and true-positive Tg.” Because of the low sensitivity of WBS, cervical ultrasonography plays more important role in the follow-up of DTC patients. Therefore, a new challenging scenario has emerged: the ultrasonography-negative, Tg-positive patient [8].

2.1. True-iodine negative and false-positive Tg

(1) Tg assays interference

The possibility of a false-positive serum Tg because of assay interference is rare but should be considered. And serum Tg has a lower false-negative rate than WBS after stimulation of thyroid stimulating hormone (TSH) either by thyroid hormone withdrawal or by recombinant human thyroid stimulating hormone (rhTSH) [9–13]. Optimal follow-up requires remnant ablation, and TSH-stimulated Tg testing [4]. The sensitivities and specificities of various Tg assays vary widely between laboratories, even with the use of an international standard (CRM 457) [14, 15], which have potential to disrupt serial monitoring and prompt inappropriate clinical decisions [9]. Additionally, undetectable

serum Tg became detectable in a significant percentage of DTC patients by changing assays [16–18]. Therefore, Tg should be dynamically monitored using the same assay performed in the same laboratory. If possible, patient's serum is frozen and saved for recovery test to assess the reliability of Tg when there is a change in Tg assay [19]. As the sensitivity of commercially available Tg assays improves, TSH-stimulated Tg may not be necessary in patients with low and intermediate risk of recurrence [9].

(2) Circulating TgAb and HAb interferences

A major problem that hampers accurate Tg measurement is the interference by TgAb and HAb resulting in either an under- or overestimation of the serum Tg concentration [19–21]. Depending on the population studied and the assay used, up to 25–30% of patients with DTC have a positive test for TgAb at the time of initial diagnosis [22, 23]. In addition, a small to moderate percentage of patients (in the literature ranging from <1 to >10%) show HAb interference in Tg measurement, an integral tool in the management of DTC patients. These antibodies typically falsely lower the Tg value in immuno-chemiluminometric assays and immuno-radiometric assays, while raising the value in radio-immunoassay.

Therefore, TgAb should be measured in the same serum sample taken for Tg assay [15, 24]. Although for clinical purposes the measurement of Tg and TgAb before thyroidectomy for a suspected or proven DTC is not recommended, a pre-thyroidectomy Tg and TgAb measurement might be used as an “in vivo” recovery test in order to assess the reliability of Tg for use as a postoperative tumor marker [19, 25]. In DTC patients, the limit of quantitation (LoQ) of a given TgAb assay should be regarded as the upper normal limit for the presence of TgAb [25]. Thyroid laboratories should report two reference ranges for TgAb: one based on the presence of TgAb in a population free of thyroid disease, which should be used for the diagnosis of autoimmune thyroid disorders, and the LoQ which should be used as the upper normal limit in DTC patients. A proposed algorithm for follow-up in TgAb-positive patients with DTC was listed in **Figure 1** from Verburg et al. [25].

Persistence of Tg-Ab for more than 1 year after thyroidectomy and ¹³¹I ablation probably indicates the presence of residual thyroid tissue and possibly and/or DTC recurrence [22, 24, 26]. A recent study also showed that TSH receptor mRNA accurately predicted disease status in 68% of DTC patients [27].

(3) Benign sources of Tg secretion

Apart from their ability to interfere with Tg assays, benign lesions (possibly with foci of thyroiditis) in persistent residual thyroid tissue or non-thyroidal tissue producing Tg may also result in false-positive Tg in DTC patients. However, residual occult disease is usually the source of post-operative Tg elevations [28–30]. Rarely, TSH-stimulated thymus may produce Tg [6].

Rarely, ectopic thyroid tissue may persist at the base of the tongue or, more often, at any other position along the thyroglossal tract, with the potential to elevate serum Tg levels. The thyroglossal tract is the most common location for ectopic thyroid tissue. This tissue retains

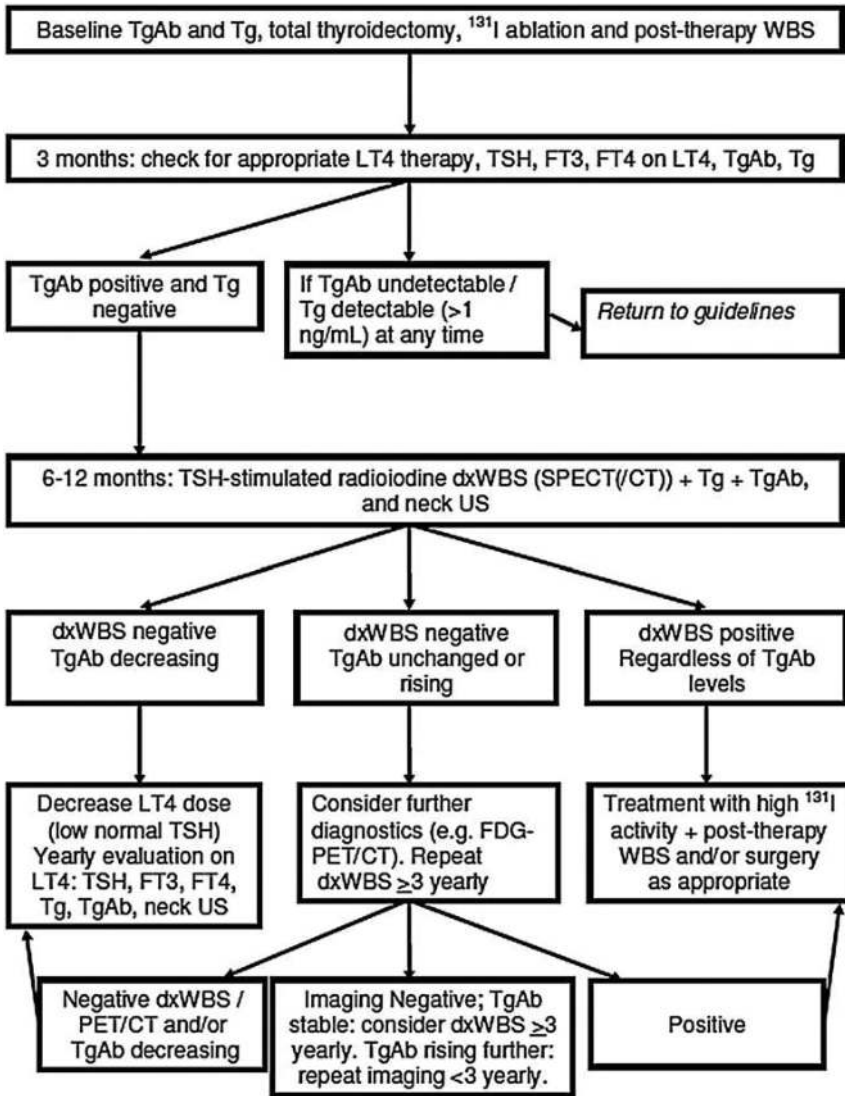


Figure 1. The algorithm for treatment and follow-up in Tb-Ab positive differentiated thyroid cancer patients from Verburg et al. [25].

not only the ability to concentrate iodine, but also to produce Tg and release it into the bloodstream [28, 31, 32]. The iodine metabolism-related proteins such as human sodium/iodide symporter (hNIS) [33], TSH receptor at both mRNA and protein level [6] are present in non-thyroidal tissues, including the thymus. Usually, these functions are dormant, but they

may be activated by TSH stimulation [34]. Interestingly, these extra-thyroidal foci may be resistant to multiple ^{131}I treatments [28, 31, 32]. In a series of 548 consecutive diagnostic WBS, ectopic thyroid tissue in the tongue or in the upper part of the thyroglossal duct was visualized in five patients (0.9%) [28]. However, in another study of 60 patients, 19/60 (31.7%) had a linear or focal radioactivity at the superior midline of the neck, suggesting thyroglossal duct remnant [29]. The absence of metastases in the thymus despite high Tg levels was confirmed in five cases [33, 35]. Rare cases of thyroid tissue ectopy has been summarized in some locations such as struma ovarii, the heart (struma cordis), the submandibular, parotid and salivary glands, the duodenum, the adrenal glands, the liver and gallbladder, the pancreas, the axilla, and iris of the eye [6].

In summary, interference with Tg assays by TgAb and HAb, benign lesions (possibly containing thyroiditis) in persistent residual thyroid tissue or nonthyroidal tissue producing Tg may also result in false-positive Tg in DTC patients.

2.2. False-negative WBS and true-positive Tg

The possible causes of false-negative WBS are mentioned below.

(1) Defect of iodine-trapping mechanism such as acquired inactivation mutation of NIS, TPO gene, pendrin, and TSHR

Thyroid hormone synthesis starts with the active uptake of iodine from the circulation via NIS. This process, known as iodine trapping, is stimulated directly by TSH and more circuitously by iodine deficiency. Other proteins, including TPO, TSHR, and pendrin, also play an important role in the thyroid metabolism of iodine. Any defect in NIS, TPO, Tg, and TSHR will contribute to false-negative WBS [7].

(2) De-differentiation of tumor such that it can still produce Tg but has lost its iodine-trapping ability

Various molecular changes within papillary thyroid cancer cells, such as RET/PTC rearrangements, RAS and BRAF mutations [36], β -catenin mutations, PAX8/PPAR α , histone acetylation factors involved in angiogenesis including overexpression of vascular endothelial growth factor (VEGF) and EGF receptor (EGFR) underlie the loss of iodide uptake ability [37]. The dedifferentiated DTC cells lost the ability to concentrate iodine but may retain Tg synthesizing capability [3, 7], which underlines the phenomenon of Tg-positive and WBS-negative lesions.

(3) Dispersed microscopic metastases, which are too small to be visualized

(4) Improper patient preparation before WBS

When it is determined that an elevation of Tg is real, if WBS is negative, false-negative scan such as stable iodine contamination and inadequate TSH elevation should be considered [7]. TSH levels should be elevated to at least 30 mIU/L before concluding that a negative WBS is meaningful. This can be achieved either by withdrawal of thyroxine or by rhTSH administration. rhTSH is as effective as thyroid hormone withdrawal on ^{131}I thyroid remnant ablation for

DTC patients with significant benefits in decreased whole-body radiation exposure and health-related quality of life [38, 39]. A summary of appropriate patient preparation for WBS in the hypothyroid state is presented in **Table 1** from Ma et al. [7].

Withdrawal of L-T4 for 4–6 weeks or of triiodothyronine for 2 weeks.

A strict low-iodine diet (50 g iodine per day) followed for 7–14 days before WBS and continuing throughout period of imaging.

Avoidance of iodine-containing medications (e.g., iodinated contrast medium, amiodarone, betadine), iodine-rich foods (e.g., kelp), and possible additives of iodine in vitamin and electrolyte supplements.

TSH > 30 mIU/L.

A mild laxative sometimes administered on the evening before WBS to simplify image interpretation.

Information relating to patient's compliance with low-iodine diet, TSH level, history of thyroid hormone withdrawal, measurement of Tg, history of prior administration of contrast medium or iodine-containing drugs (e.g., amiodarone), menstrual history/pregnancy test, nursing/lactation history, etc.

Measurement of urinary iodine in doubtful cases to rule out iodine contamination; repeated WBS 4–6 weeks after iodine depletion regimen such as diuretic program.

Rule out women with pregnancy and breast feeding.

Table 1. A summary of appropriate patient preparation for WBS from reference by Ma et al.

3. Management of DTC patients with positive Tg and negative WBS

3.1. Other diagnostic modalities for DTC in this setting

In the clinical setting, the precise location of WBS-negative recurrent DTC is mandatory because surgery is the only curative treatment option and metastases that are unable to concentrate ^{131}I are associated with more aggressive clinical behavior [40]. Cervical ultrasonography, CT and MRI, ^{124}I PET/CT have limited roles in the diagnosis of DTC metastases with positive Tg and negative WBS. Non-iodine imaging agents—such as ^{201}Tl , $^{99\text{m}}\text{Tc}$ -sestamibi, $^{99\text{m}}\text{Tc}$ -tetrofosmin, somatostatin receptor (SRS) scan have reasonable accuracy [41]. However, they have been replaced by ^{18}F -FDG in the follow-up algorithm of DTC patients with positive Tg and negative WBS.

(1) Cervical ultrasonography

Cervical ultrasonography has high sensitivity in detecting recurrence in the thyroid bed and nodal metastases of DTC in the neck [42, 43]. It has been used as first-line diagnostic imaging in DTC follow-up [44, 45]. However, neck ultrasonography has limitations: one is that it does not reveal DTC recurrences in other body sites. It is also difficult for cervical

ultrasonography to differentiate scar tissue and locally recurring fibrosis and between nonspecific nodal enlargements and nodal metastases [46]. Therefore, the other limitation of ultrasonography is the low specificity in DTC patients of altered anatomy after thyroid surgery.

(2) CT and MRI

In patients with elevated or rising Tg or TgAb and no evidence of disease on neck ultrasonography or WBS (if performed), CT imaging of the neck and chest should be considered [47]. Diagnostic CT scan may complement neck ultrasonography for the detection of macrometastases in the central compartment, in the mediastinum and behind the trachea [48–50], and is the most sensitive tool for the detection of micro-metastases in the lungs. MRI has also been advocated for imaging the neck and the mediastinum. It is performed without and with injection of gadolinium chelate as contrast medium and does not require any injection of iodine contrast medium. Brain and skeletal MRI and/or CT, or abdominal MRI may be performed in high-risk DTC patients with elevated Tg (generally >10 ng/mL) and negative WBS or ultrasonography, who have systemic symptoms related to those organs, or who will have ¹³¹I therapy and may be at risk for complications of tumor swelling [51]. MRI is less sensitive than CT scan for the detection of lung micronodules [47].

(3) ¹⁸F-FDG-PET/CT or PET/MRI

The iodine-negative DTC lesions were found to have increased expression of the glucose transporter-1, and often have FDG uptake [52]. Therefore, ¹⁸F-FDG-PET is particularly useful in the detection of recurrent or metastatic DTC in patients with positive Tg and negative WBS, allowing detection of metastases not detected by other imaging modalities [53]. In a recent meta-analysis, the combined sensitivity and specificity for FDG-PET/CT were 93 and 81%, respectively [54].

Factors influencing PET/CT sensitivity include tumor de-differentiation, larger tumor burden and to a lesser extent, TSH stimulation [47]. PET is more sensitive in patients with an aggressive histological subtype, including poorly differentiated, tall cell, and Hürthle cell thyroid cancer. The sensitivity of PET (ranging from less than 10–30%) is low in patients with a TSH-stimulated Tg < 10 ng/mL. It is therefore recommended to consider ¹⁸F-FDG-PET only in DTC patients with a stimulated Tg level ≥10 ng/mL [47]. A meta-analysis of seven prospective controlled clinical trials indicated that FDG-PET under TSH stimulation either by thyroid hormone withdrawal or by rhTSH had slightly improved diagnostic performance in detecting Tg-positive and WBS-negative DTC lesions. FDG-PET/CT is useful in staging, response assessment after chemotherapy, targeted therapies, or radiotherapy and prognostic assessment for patients with cancer [55]. Therefore, PET/CT imaging should be performed as first-line, with empiric ¹³¹I treatment being considered only for those patients with no detectable FDG uptake [51]. PET/CT can also identify lesions with high FDG uptake (SUV) that may be more aggressive and should have multi-targeted kinase inhibitors or close monitoring. A study observed that elevated Tg, but normal PET exists as a definitive entity in DTC. Positive Tg with negative PET was

regarded as a favorable prognostic indicator to predict symptom-free status during the follow-up period [56].

However, false positives occur with PET imaging with or without TSH stimulation [50]. The frequency of false-positive lesions varies among series from 0 to 39%, and this high number justifies a fine-needle aspiration (FNA) biopsy with cytology and Tg measurement in the aspirate fluid in cases where surgery is planned, based on PET results.

FDG-PET/CT is useful in staging, response assessment after chemotherapy, targeted therapies, or radiotherapy and prognostic assessment for patients with cancer [55]. PET/CT imaging is more sensitive and should be performed as first-line, with empiric ^{131}I treatment being considered only for those patients with no detectable FDG uptake [51]. PET/CT can also identify lesions with high FDG uptake (SUV) that may be more aggressive and should have multi-targeted kinase inhibitors or close monitoring. A study observed that elevated Tg, but normal PET exists as a definitive entity in DTC. Positive Tg with negative PET was regarded as a favorable prognostic indicator to predict symptom-free status during the follow-up period [56].

(4) ^{124}I PET/CT

^{124}I emits positrons, allowing PET/CT imaging in DTC patients. It is used as for dosimetry and also as a diagnostic tool to localize DTC metastases. ^{124}I PET/CT accurately measures the volume, uptake, and half-life of ^{124}I in each DTC lesion, therefore permitting a reliable individual dosimetric assessment for DTC metastases [47]. ^{124}I -PET has higher sensitivity in detecting the residual thyroid tissue and/or DTC metastases than that of WBS (99% vs. 66%) [57–61]. The combination of ^{124}I and FDG-PET/CT affords a valuable diagnostic method that can be used to make therapeutic decisions in patients with positive Tg and negative WBS [57, 61]. ^{124}I -PET/CT with thyroid hormone withdrawal was found to detect significantly more foci of metastases of DTC [59]. However, it is unclear whether and to what extent patient preparation with rhTSH rather than thyroid hormone withdrawal affects the diagnostic accuracy of ^{124}I PET/CT [57]. ^{124}I is not yet widely available for clinical use and is primarily a research tool at this time.

(5) Somatostatin receptor scan (SRS)

Thyroid tumors are known to express SRS, and therefore, ^{111}In -pentetreotide (somatostatin analog) can visualize non-iodine avid DTC metastases with high concentration of SRS. A case of negative WBS recurrent metastatic papillary thyroid carcinoma with positive ^{111}In -pentetreotide scan was reported [62]. Technetium-99m labeled somatostatin analog, $^{99\text{m}}\text{Tc}$ -Hynic-TOC scintigraphy had a sensitivity of 88.46% (23/26), specificity of 100% (2/2), and an accuracy of 89.2% (25/28) [41]. SRS scintigraphy may be useful both in the staging and monitoring of patients with WBS-negative DTC metastases. ^{68}Ga llium-somatostatin analogs PET/CT is currently a promising method to study well-differentiated neuroendocrine tumor which has a better sensitivity and therefore is superior to $^{99\text{m}}\text{Tc}$ or ^{111}In labeled SRS [63, 64]. SRS scan positive patients are potential candidates for SRS-targeted therapy.

In addition, ^{68}Ga -somatostatin analogs PET/CT is currently a promising method to study well-differentiated neuroendocrine tumor which has a better sensitivity and therefore is superior to $^{99\text{m}}\text{Tc}$ or ^{111}In labeled SRS [63, 64]. ^{18}F -FLT and ^{11}C -MET may also have a diagnostic roles in this clinical setting [65].

(6) Fine-needle aspiration (FNA)

FNA biopsy for cytology and Tg measurement in the aspirate fluid is performed for suspicious lymph nodes >8–10 mm in their smallest diameter. Non-suspicious and small nodes (<8–10 mm in the smallest diameter) can be monitored with neck ultrasonography [47]. Ultrasonography guidance aspiration may improve the results of FNA biopsy, in particular for small lymph nodes and those located deep in the neck. The measurement of Tg in the FNA biopsy washout fluid (FNAB-Tg) is the more accurate tool to detect DTC recurrences and metastases in the neck [66, 67]. However, the application of FNA biopsy Tg is currently hindered by the absence of methodological standardization, a lack of definite cutoff points, and the ongoing debate regarding its accuracy in nonthyroidectomized patients, those with elevated serum Tg, and those with circulating TgAb [66, 67]. A Tg concentration in the aspirate fluid between 1 and 10 ng/mL is moderately suspicious for malignancy [47]; above 10 ng/mL are highly suspicious of DTC metastases [68–70].

In summary, in patients with elevated or rising Tg (>10 ng/mL) or TgAb and no evidence of disease on neck ultrasonography or WBS (if performed), CT imaging of the neck and chest, MRI of the neck and abdomen may be considered. ^{18}F -FDG-PET/CT also plays an important role in the detecting DTC metastases with positive Tg (>10 ng/mL) and negative WBS, and negative conventional imaging. The result of ^{18}F -FDG-PET/CT is helpful in guiding the treatment strategy. FNA biopsy and Tg measurement in washout fluid are helpful in the confirmation of foci detected by ^{18}F -FDG-PET/CT.

3.2. Treatments for Tg-positive and WBS-negative DTC metastases

3.2.1. Empiric ^{131}I treatment

Thyroid hormone withdrawal induces substantial short- and long-term morbidity, decreased quality of life due to associated hypothyroidism. ^{131}I therapy may cause early and late sialoadenitis in up to 30% which can lead to xerostomia, dental caries, and stomatitis [71, 72], with a majority of patients suffering from significant changes in physical, psychological, and social well-being [73, 74]. Therefore, the pros and cons of empiric ^{131}I treatment should be well-balanced justified.

The management of elevated serum Tg and radioiodine-negative scans was outlined by Ma et al. [3]. Of 438 patients from 16 studies who were treated empirically with ^{131}I for iodine-negative and Tg-positive DTC disease, 267 (62%) displayed pathological uptakes in the thyroid bed, lungs, bone, mediastinum and lymph nodes. In studies in which data were available for serum Tg levels during TSH suppression therapy or TSH withdrawal, 56% (188/337) patients showed decreased Tg. Of 242 patients from 5 studies who received no specific treatment for iodine-negative and Tg-positive DTC disease, 44% (106/242) showed spontaneous normalization and

a significant decrease in serum Tg. Thus, high doses of ^{131}I have therapeutic effects if the Tg level is considered an index of tumor burden, at least in the short term, and could also localize previously undiagnosed recurrences. Therefore, empiric ^{131}I treatment may be justified in high-risk patients with serum Tg > 10 ng/mL and a negative WBS and FDG-PET scan results [3, 75, 76]. Pulmonary metastases may be found only on post-therapy WBS [77]. In a study of 283 DTC patients treated with 100mCi (3.7 GBq) of ^{131}I , 6.4% had lung and bone metastases detected after treatment that had been suspected based on high serum Tg alone but had not been detected after 2mCi (74 MBq) ^{131}I WBS [78].

However, most studies in this area have limited reliability as they lacked control groups and an adequate follow-up period [3]. Still missing from our knowledge are long-term survival rates, changes in mass sizes on post-therapy imaging, and radiation-induced side-effects of ^{131}I therapy. Although the tumor burden may be diminished, most patients with negative WBS and positive Tg are not rendered disease free by ^{131}I therapy [79]. Nearly half of patients with Tg-positive and WBS-negative DTC show spontaneous normalization and significant reduction in serum Tg without any specific treatment, ^{131}I therapy should be individualized according to the clinical characteristics and imaging features. A five-year follow-up of 29 patients with elevated Tg (>2 ng/mL) and negative ^{131}I WBS found that 24/29 patients showed Tg decreasing trend without ^{131}I therapy, of whom only one patient recurred; the other 5/29 patients showed a rising trend and all recurred [5].

Therefore, additional diagnostic techniques are strongly recommended for patients with Tg-positive and WBS-negative metastases. If these diagnostic results are positive, treatment options such as surgery, external radiotherapy and tumor embolization can be considered. Empiric ^{131}I therapy is more commonly considered for those with distant metastases or inoperable local disease. If FDG-PET result is negative, one course of ^{131}I treatment may be considered in high-risk patients with. Repeated ^{131}I therapy may be given to patients who had persistent non-resectable DTC metastases and iodine uptake, and there are significant therapeutic benefits until the lesion has been eradicated or the lesion no longer responds to treatment. The risk of repeated therapeutic doses of RAI must be balanced against uncertain long-term benefits. In the case of negative post-therapy WBS, the patient should be considered to have radioiodine-refractory disease and no further ^{131}I therapy should be administered.

3.2.2. *Re-differentiation strategies*

(1) **Retinoic acids (RA) and lithium**

RA are active metabolites of vitamin A able to regulate growth and differentiation of many cell types by binding to specific nuclear receptors, the RA receptors, and the retinoid X receptors (RXR) [80]. Lithium increases the residence time of ^{131}I in the thyroid tissue [37, 81, 82]. RA and lithium [82] were used to redifferentiate metastatic DTC and render them responsive to ^{131}I therapy. However, they only yielded a limited clinical benefit.

(2) **Iodine-trapping-related gene transfection**

hNIS protein is a membrane glycoprotein that transports iodide ions into thyroid cells. This process, known as iodine trapping, is stimulated directly by TSH. Other proteins,

including thyroperoxidase (TPO) and pendrin, also play an important role in the thyroid metabolism of iodine [83]. Strategies of gene transfection focused on NIS; TPO has been studied to enhance tumor uptake iodine [84, 85]. Co-transfection of the hNIS and hTPO genes can lead to longer retention of radio iodine [85]. Targeted NIS gene transfer, by viral and non-viral vectors, followed by radionuclide ^{131}I , ^{188}Re , ^{211}At therapy, has been recently suggested for the treatment of advanced or WBS-negative DTC metastases. In thyroid cells, TSH stimulates NIS synthesis [86]. Therefore, hTSHR transfection was investigated in FTC-133 thyroid cells, which improved the expression of thyroid-specific molecules including TSHR, NIS, TPO, and Tg and radioiodide uptake [87, 88]. Iodine-trapping-related gene transfection has not been used clinically yet.

(3) MAPK kinase inhibitor

Mitogen-activated protein kinase (MAPK) signaling inhibits the expression of thyroid hormone biosynthesis genes, including the NIS and TPO, which facilitate iodine uptake and organification, respectively [89, 90]. Inhibition of the MAPK pathway may renew the therapeutic efficacy of ^{131}I by enhancing uptake in patients with thyroid cancer that is refractory to ^{131}I [82]. MAPK1-2 inhibitor selumetinib (AZD6244, ARRY-142886), orally administered at a dose of 75 mg twice daily increased the uptake of ^{124}I in 12 of 20 patients. Selumetinib enhanced ^{131}I uptake in eight patients with advanced DTC. After ^{131}I treatment, partial responses were achieved in 5, stable disease in 3. No severe adverse events were observed [82].

In summary, strategy of re-differentiation of iodine-negative DTC metastases by RA has limited clinical benefit. Iodine-trapping-related protein transfection remains experimental. MAPK kinase inhibitor needs to be confirmed in large population.

3.2.3. Multi-targeted kinase inhibitors

Both sorafenib (BAY 43-9006) and lenvatinib are multi-kinase inhibitors with potent activity against RAF, VEGF receptors, fibroblast growth factor receptors, PDGF receptor, c-KIT and RET kinases [37, 88, 91]. Sorafenib and lenvatinib are both FDA approved for iodine refractory DTC metastases [92]. They achieved clinical benefits in terms of partial response of 12.5–38%, progression-free survival from 9 to 24 months in radioiodine-refractory DTC metastases [37, 91]. The therapeutic effects of other tyrosine kinase inhibitors including sunitinib, imatinib, vandetanib were also summarized [37] and a dozen ongoing trials currently listed in the ClinicalTrials.gov database, evaluating 12 kinase-inhibiting drugs [93].

Adverse effects occurred in 98.6% patients receiving sorafenib: the most frequent were hand-foot skin reactions, diarrhea, alopecia, and rash or desquamation [94].

Selection of a targeted agent should depend on disease trajectory, side effect profile, and goals of therapy. Kinase inhibitor therapy should be considered in radioiodine-refractory DTC metastases, rapidly progressive, symptomatic and/or imminently threatening disease not otherwise amenable to local control using other approaches. Patients who are candidates for kinase inhibitor therapy should be thoroughly counseled on the potential risks and benefits of this therapy as well as alternative therapeutic approaches including best supportive care [47].

3.2.4. Other treatments

(1) TSH suppression

TSH suppression is considered essential in the treatment of patients with positive Tg and negative WBS, because TSH is a trophic hormone that can stimulate the growth of cells derived from thyroid follicular epithelium [45, 95, 96]. Therefore, the recommended TSH level is below 0.1 mU/L, or slightly below or slightly above the lower reference range [9].

(2) Surgery and stereotactic radiotherapy (SBRT)

Most recurrent DTCs respond well to surgery and SBRT [45, 97]. The isolated skeletal metastasis of DTC is recommended for surgery or SBRT [9]. Neurosurgery or SBRT is preferred treatments for solitary brain metastases of DTC [98, 99]. SBRT is considered for loco-regional recurrence that is not surgically resectable, or with extra-nodal extension or involvement of soft tissues, in particular in patients with no evidence of distant disease, but has no role in most patients with resectable lymph node metastases [47].

(3) Chemotherapy

Systematic chemotherapy can be considered for DTC lesions with positive Tg and negative WBS that are not surgically resectable, not responsive to ¹³¹I, not amenable to EBRT treatment, or not responsive to multi-targeted kinase inhibitors, and have clinically significant structural disease progression during the last 6–12 months. Two of 49 (3%) patients with DTC metastases had a response to five chemotherapy protocols [100]. In a review by Ahuja et al., 38% of patients with thyroid cancer had reduction in tumor mass to doxorubicin [101]. Combination chemotherapy does not show clear superiority to doxorubicin therapy alone [102]. Therefore, the traditional chemotherapy has limited effects on iodine refractory DTC metastases [9, 103].

(4) Other treatments

Other treatments include percutaneous ethanol injection (PEI), radiofrequency, or laser ablation.

PEI for patients with metastatic DTC in lymph node is promising as a nonsurgical-directed therapy [104, 105]. Most of the studies limited PEI to patients who had undergone previous neck dissections and ¹³¹I treatment, those who had FNA-proven DTC in the lymph node and those with no known distant metastases [106]. A general consensus from studies and reviews is that PEI could be considered in patients who are poor surgical candidates [47]. Radiofrequency ablation has been associated with a mean volume reduction that ranges between approximately 55–95% [107, 108], and 40–60% complete disappearance of the DTC metastases in the treatment of recurrent thyroid cancer [108, 109]. More recently, preliminary findings using ultrasonography-guided laser ablation for treatment of cervical lymph node metastases have been reported [110].

In summary, true-negative WBS with positive Tg may be due to benign thyroid remnants (possibly containing thyroiditis) or, rarely, nonthyroidal tissue producing Tg. False-negative WBS with positive Tg can be caused by a defective or acquired iodine-trapping inactivation;

dedifferentiation of tumor which can still produce Tg but has lost its iodine-trapping ability; small dispersed microscopic metastases. Other radioisotopes and additional diagnostic options play an important role in the ascertainment of patients with negative WBS and Tg-positive DTC metastases. FDG-PET/CT should be considered in high-risk DTC patients with negative WBS and positive Tg. If FDG-PET diagnostic results are negative, one course of ^{131}I treatment may be considered in high-risk patients and individualized. No further ^{131}I therapy is indicated for patients with a negative post-therapy WBS. The preferred hierarchy of treatment for Tg-positive and WBS-negative metastases is surgical excision of loco-regional disease in potentially curable patients, ^{131}I therapy for residual radioiodine-responsive disease, external beam radiation or other directed treatment modalities such as thermal ablation, TSH suppression for patients with stable or slowly progressive asymptomatic disease, and systemic therapy with multi-kinase inhibitors, especially for patients with significantly progressive macroscopic refractory disease.

Author details

Chao Ma

Address all correspondence to: mc_7419@hotmail.com

Nuclear Medicine, Affiliated Xinhua Hospital School of Medicine, Shanghai Jiaotong University, Shanghai, China

References

- [1] Ringel MD and Ladenson PW. Controversies in the follow-up and management of well-differentiated thyroid cancer. *Endocrine-Related Cancer*. 2004;11:97–116.
- [2] Shammass A, Degirmenci B, Mountz JM, McCook BM, Branstetter B, Bencherif B, Joyce JM, Carty SE, Kuffner HA and Avril N. 18F-FDG PET/CT in patients with suspected recurrent or metastatic well-differentiated thyroid cancer. *Journal of Nuclear Medicine: Official Publication, Society of Nuclear Medicine*. 2007;48:221–226.
- [3] Chao M. Management of differentiated thyroid cancer with rising thyroglobulin and negative diagnostic radioiodine whole body scan. *Clinical Oncology (Royal College of Radiologists (Great Britain))*. 2010;22:438–447.
- [4] Eustatia-Rutten CF, Smit JW, Romijn JA, van der Kleij-Corssmit EP, Pereira AM, Stokkel MP and Kievit J. Diagnostic value of serum thyroglobulin measurements in the follow-up of differentiated thyroid carcinoma, a structured meta-analysis. *Clinical Endocrinology*. 2004;61:61–74.

- [5] Gupta M, Choudhury PS, Nag S and Gupta P. Stimulated high serum thyroglobulin with negative whole body imaging do not warrant an aggressive diagnostic and therapeutic approach in differentiated thyroid cancer patients: a follow-up of 5 years or till recurrence. *Hellenic Journal of Nuclear Medicine*. 2015;18:207–214.
- [6] Zanotti-Fregonara P, Keller I, Calzada-Nocaudie M, Al-Nahhas A, Devaux JY, Grassetto G, Marzola MC, Rubello D and Hindie E. Increased serum thyroglobulin levels and negative imaging in thyroid cancer patients: are there sources of benign secretion? A speculative short review. *Nuclear Medicine Communications*. 2010;31:1054–1058.
- [7] Ma C, Kuang A, Xie J and Ma T. Possible explanations for patients with discordant findings of serum thyroglobulin and ¹³¹I whole-body scanning. *Journal of Nuclear Medicine: Official Publication, Society of Nuclear Medicine*. 2005;46:1473–1480.
- [8] Kloos RT. Approach to the patient with a positive serum thyroglobulin and a negative radioiodine scan after initial therapy for differentiated thyroid cancer. *The Journal of Clinical Endocrinology and Metabolism*. 2008;93:1519–1525.
- [9] Haddad RI, Lydiatt WM, Ball DW, Busaidy NL, Byrd D, Callender G, Dickson P, Duh QY, Ehya H, Haymart M, Hoh C, Hunt JP, Iagaru A, Kandeel F, Kopp P, Lamonica DM, McCaffrey JC, Moley JF, Parks L, Raeburn CD, Ridge JA, Ringel MD, Scheri RP, Shah JP, Smallridge RC, Sturgeon C, Wang TN, Wirth LJ, Hoffmann KG and Hughes M. Anaplastic thyroid carcinoma, version 2.2015. *Journal of the National Comprehensive Cancer Network: JNCCN*. 2015;13:1140–1150.
- [10] Pacini F, Lari R, Mazzeo S, Grasso L, Taddei D and Pinchera A. Diagnostic value of a single serum thyroglobulin determination on and off thyroid suppressive therapy in the follow-up of patients with differentiated thyroid cancer. *Clinical Endocrinology*. 1985;23:405–411.
- [11] Haugen BR, Pacini F, Reiners C, Schlumberger M, Ladenson PW, Sherman SI, Cooper DS, Graham KE, Braverman LE, Skarulis MC, Davies TF, DeGroot LJ, Mazzaferri EL, Daniels GH, Ross DS, Luster M, Samuels MH, Becker DV, Maxon HR, 3rd, Cavalieri RR, Spencer CA, McEllin K, Weintraub BD and Ridgway EC. A comparison of recombinant human thyrotropin and thyroid hormone withdrawal for the detection of thyroid remnant or cancer. *The Journal of Clinical Endocrinology and Metabolism*. 1999;84:3877–3885.
- [12] Kloos RT and Mazzaferri EL. A single recombinant human thyrotropin-stimulated serum thyroglobulin measurement predicts differentiated thyroid carcinoma metastases three to five years later. *The Journal of Clinical Endocrinology and Metabolism*. 2005;90:5047–5057.
- [13] Castagna MG, Brilli L, Pilli T, Montanaro A, Cipri C, Fioravanti C, Sestini F, Capezzone M and Pacini F. Limited value of repeat recombinant human thyrotropin (rhTSH)-stimulated thyroglobulin testing in differentiated thyroid carcinoma patients with

- previous negative rhTSH-stimulated thyroglobulin and undetectable basal serum thyroglobulin levels. *The Journal of Clinical Endocrinology and Metabolism*. 2008;93:76–81.
- [14] Spencer CA, Takeuchi M and Kazarosyan M. Current status and performance goals for serum thyroglobulin assays. *Clinical Chemistry*. 1996;42:164–173.
- [15] Spencer CA and Lopresti JS. Measuring thyroglobulin and thyroglobulin autoantibody in patients with differentiated thyroid cancer. *Nature Clinical Practice Endocrinology and Metabolism*. 2008;4:223–233.
- [16] Phan HT, Jager PL, Paans AM, Plukker JT, Sturkenboom MG, Sluiter WJ, Wolffenbuttel BH, Dierckx RA and Links TP. The diagnostic value of 124I-PET in patients with differentiated thyroid cancer. *European Journal of Nuclear Medicine and Molecular Imaging*. 2008;35:958–965.
- [17] Hufner M, Pfahl H, Bethausen H, Heilig B and Georgi P. Comparative plasma thyroglobulin measurements with three non-cross-reactive monoclonal antibodies in metastatic thyroid cancer patients. *Acta Endocrinologica*. 1988;118:528–532.
- [18] Schulz R, Bethausen H, Stempka L, Heilig B, Moll A and Hufner M. Evidence for immunological differences between circulating and thyroid tissue-derived thyroglobulin in men. *European Journal of Clinical Investigation*. 1989;19:459–463.
- [19] Giovanella L, Suriano S, Ceriani L and Verburg FA. Undetectable thyroglobulin in patients with differentiated thyroid carcinoma and residual radioiodine uptake on a postablation whole-body scan. *Clinical Nuclear Medicine*. 2011;36:109–112.
- [20] Giovanella L, Keller F, Ceriani L and Tozzoli R. Heterophile antibodies may falsely increase or decrease thyroglobulin measurement in patients with differentiated thyroid carcinoma. *Clinical Chemistry and Laboratory Medicine*. 2009;47:952–954.
- [21] Verburg FA, Waschle K, Reiners C, Giovanella L and Lentjes EG. Heterophile antibodies rarely influence the measurement of thyroglobulin and thyroglobulin antibodies in differentiated thyroid cancer patients. *Hormone and Metabolic Research = Hormon- und Stoffwechselforschung = Hormones et metabolisme*. 2010;42:736–739.
- [22] Chiovato L, Latrofa F, Braverman LE, Pacini F, Capezzone M, Masserini L, Grasso L and Pinchera A. Disappearance of humoral thyroid autoimmunity after complete removal of thyroid antigens. *Annals of Internal Medicine*. 2003;139:346–351.
- [23] Pacini F, Mariotti S, Formica N, Elisei R, Anelli S, Capotorti E and Pinchera A. Thyroid autoantibodies in thyroid cancer: incidence and relationship with tumour outcome. *Acta Endocrinologica*. 1988;119:373–380.
- [24] Spencer CA, Takeuchi M, Kazarosyan M, Wang CC, Guttler RB, Singer PA, Fatemi S, LoPresti JS and Nicoloff JT. Serum thyroglobulin autoantibodies: prevalence, influence on serum thyroglobulin measurement, and prognostic significance in patients with differentiated thyroid carcinoma. *The Journal of Clinical Endocrinology and Metabolism*. 1998;83:1121–1127.

- [25] Verburg FA, Luster M, Cupini C, Chiovato L, Duntas L, Elisei R, Feldt-Rasmussen U, Rimmele H, Seregni E, Smit JW, Theimer C and Giovanella L. Implications of thyroglobulin antibody positivity in patients with differentiated thyroid cancer: a clinical position statement. *Thyroid: Official Journal of the American Thyroid Association*. 2013;23:1211–1225.
- [26] Chung JK, Park YJ, Kim TY, So Y, Kim SK, Park DJ, Lee DS, Lee MC and Cho BY. Clinical significance of elevated level of serum antithyroglobulin antibody in patients with differentiated thyroid cancer after thyroid ablation. *Clinical Endocrinology*. 2002;57:215–221.
- [27] Aliyev A, Soundararajan S, Bucak E, Gupta M, Hatipoglu B, Nasr C, Siperstein A and Berber E. The utility of peripheral thyrotropin receptor mRNA in the management of differentiated thyroid cancer. *Surgery*. 2015;158:1089–1093; discussion 1093–1094.
- [28] Zanotti-Fregonara P, Hindie E, Keller I, Calzada-Nocaudie M and Devaux JY. Scintigraphic visualization of glossal thyroid tissue during the follow-up of thyroid cancer patients. *Clinical Nuclear Medicine*. 2007;32:911–914.
- [29] Mohamed Sayed MH, Saleh Farghaly HR and Fadl FA. Rate of thyroglossal duct remnant visualization after total thyroidectomy for differentiated thyroid carcinoma and its impact on clinical outcome of radioactive iodine (I-131) ablation. *Indian Journal of Nuclear Medicine: IJNM: The Official Journal of The Society of Nuclear Medicine, India*. 2015;30:116–121.
- [30] Lee M, Lee YK, Jeon TJ, Chang HS, Kim BW, Lee YS, Park CS and Ryu YH. Frequent visualization of thyroglossal duct remnant on post-ablation 131I-SPECT/CT and its clinical implications. *Clinical Radiology*. 2015;70:638–643.
- [31] Li D, Meng Z, Zhang G, Yu T, Tan J and Dong F. Visualization of thyroglossal duct cyst in differentiated thyroid cancer patient. *Clinical Nuclear Medicine*. 2010;35:499–504.
- [32] Basaria S, Westra WH and Cooper DS. Ectopic lingual thyroid masquerading as thyroid cancer metastases. *The Journal of Clinical Endocrinology and Metabolism*. 2001;86:392–395.
- [33] Abhyankar A and Basu S. Thymus uptake of 131I in patients with differentiated thyroid carcinoma: three different case scenarios and patterns of uptake and the importance of its recognition in thyroid cancer practice. *Journal of Cancer Research and Therapeutics*. 2015;11:648.
- [34] Sauk JJ, Jr. Ectopic lingual thyroid. *The Journal of Pathology*. 1970;102:239–243.
- [35] Arce MB, Molina TC, Hernandez TM, de la Cinta Calvo Moron M, Herrero CH, De La Riva Perez PA and Montano JC. Thymic uptake after high-dose I-131 treatment in patients with differentiated thyroid carcinoma: a brief review of possible causes and management. *Endocrinología y nutrición: organo de la Sociedad Espanola de Endocrinología y Nutrición*. 2015;62:19–23.

- [36] Antonelli A, Ferri C, Ferrari SM, Sebastiani M, Colaci M, Ruffilli I and Fallahi P. New targeted molecular therapies for dedifferentiated thyroid cancer. *Journal of Oncology*. 2010;2010:921682.
- [37] Fallahi P, Mazzi V, Vita R, Ferrari SM, Materazzi G, Galleri D, Benvenga S, Miccoli P and Antonelli A. New therapies for dedifferentiated papillary thyroid cancer. *International Journal of Molecular Sciences*. 2015;16:6153–6182.
- [38] Ma C, Tang L, Fu H, Li J and Wang H. rhTSH-aided low-activity versus high-activity regimens of radioiodine in residual ablation for differentiated thyroid cancer: a meta-analysis. *Nuclear Medicine Communications*. 2013;34:1150–1156.
- [39] Ma C, Xie J, Liu W, Wang G, Zuo S, Wang X and Wu F. Recombinant human thyrotropin (rhTSH) aided radioiodine treatment for residual or metastatic differentiated thyroid cancer. *The Cochrane Database of Systematic Reviews*. 2010;10:Cd008302.
- [40] Schlumberger MJ. Papillary and follicular thyroid carcinoma. *The New England Journal of Medicine*. 1998;338:297–306.
- [41] Shinto AS, Kamaleshwaran KK, Mallia M, Korde A, Samuel G, Banerjee S, Velayutham P, Damodharan S and Sairam M. Utility of (99m)Tc-Hynic-TOC in 131I whole-body scan negative thyroid cancer patients with elevated serum thyroglobulin levels. *World Journal of Nuclear Medicine*. 2015;14:101–108.
- [42] Alzahrani AS, Alsuhaibani H, Salam SA, Al Sifri SN, Mohamed G, Al Sobhi S, Sulaiman O and Akhtar M. Diagnostic accuracy of high-resolution neck ultrasonography in the follow-up of differentiated thyroid cancer: a prospective study. *Endocrine Practice: Official Journal of the American College of Endocrinology and the American Association of Clinical Endocrinologists*. 2005;11:165–171.
- [43] Torlontano M, Crocetti U, Augello G, D'Aloiso L, Bonfitto N, Varraso A, Dicembrino F, Modoni S, Frusciante V, Di Giorgio A, Bruno R, Filetti S and Trischitta V. Comparative evaluation of recombinant human thyrotropin-stimulated thyroglobulin levels, 131I whole-body scintigraphy, and neck ultrasonography in the follow-up of patients with papillary thyroid microcarcinoma who have not undergone radioiodine therapy. *The Journal of Clinical Endocrinology and Metabolism*. 2006;91:60–63.
- [44] Pacini F, Castagna MG, Brilli L and Pentheroudakis G. Thyroid cancer: ESMO Clinical Practice Guidelines for diagnosis, treatment and follow-up. *Annals of Oncology: Official Journal of the European Society for Medical Oncology/ESMO*. 2012;23(Suppl 7):vii110–vii109.
- [45] Cooper DS, Doherty GM, Haugen BR, Kloos RT, Lee SL, Mandel SJ, Mazzaferri EL, McIver B, Pacini F, Schlumberger M, Sherman SI, Steward DL and Tuttle RM. Revised American Thyroid Association management guidelines for patients with thyroid nodules and differentiated thyroid cancer. *Thyroid: Official Journal of the American Thyroid Association*. 2009;19:1167–1214.

- [46] Galloway RJ and Smallridge RC. Imaging in thyroid cancer. *Endocrinology and Metabolism Clinics of North America*. 1996;25:93–113.
- [47] Haugen BR, Alexander EK, Bible KC, Doherty GM, Mandel SJ, Nikiforov YE, Pacini F, Randolph GW, Sawka AM, Schlumberger M, Schuff KG, Sherman SI, Sosa JA, Steward DL, Tuttle RM and Wartofsky L. 2015 American Thyroid Association Management Guidelines for adult patients with thyroid nodules and differentiated thyroid cancer: The American Thyroid Association Guidelines Task Force on thyroid nodules and differentiated thyroid cancer. *Thyroid: Official Journal of the American Thyroid Association*. 2016;26:1–133.
- [48] Ahn JE, Lee JH, Yi JS, Shong YK, Hong SJ, Lee DH, Choi CG and Kim SJ. Diagnostic accuracy of CT and ultrasonography for evaluating metastatic cervical lymph nodes in patients with thyroid cancer. *World Journal of Surgery*. 2008;32:1552–1558.
- [49] Choi JS, Kim J, Kwak JY, Kim MJ, Chang HS and Kim EK. Preoperative staging of papillary thyroid carcinoma: comparison of ultrasonography imaging and CT. *AJR American Journal of Roentgenology*. 2009;193:871–878.
- [50] Leboulleux S, Schroeder PR, Busaidy NL, Auperin A, Corone C, Jacene HA, Ewertz ME, Bournaud C, Wahl RL, Sherman SI, Ladenson PW and Schlumberger M. Assessment of the incremental value of recombinant thyrotropin stimulation before 2-[18F]-Fluoro-2-deoxy-D-glucose positron emission tomography/computed tomography imaging to localize residual differentiated thyroid cancer. *The Journal of Clinical Endocrinology and Metabolism*. 2009;94:1310–1316.
- [51] Rosario PW, Mourao GF, dos Santos JB and Calsolari MR. Is empirical radioactive iodine therapy still a valid approach to patients with thyroid cancer and elevated thyroglobulin? *Thyroid: Official Journal of the American Thyroid Association*. 2014;24:533–536.
- [52] Grunwald F, Kalicke T, Feine U, Lietzenmayer R, Scheidhauer K, Dietlein M, Schober O, Lerch H, Brandt-Mainz K, Burchert W, Hiltermann G, Cremerius U and Biersack HJ. Fluorine-18 fluorodeoxyglucose positron emission tomography in thyroid cancer: results of a multicentre study. *European Journal of Nuclear Medicine*. 1999;26:1547–1552.
- [53] Altenvoerde G, Lerch H, Kuwert T, Matheja P, Schafers M and Schober O. Positron emission tomography with F-18-deoxyglucose in patients with differentiated thyroid carcinoma, elevated thyroglobulin levels, and negative iodine scans. *Langenbeck's Archives of Surgery/Deutsche Gesellschaft für Chirurgie*. 1998;383:160–163.
- [54] Caetano R, Bastos CR, de Oliveira IA, da Silva RM, Fortes CP, Pepe VL, Reis LG and Braga JU. Accuracy of positron emission tomography and positron emission tomography-CT in the detection of differentiated thyroid cancer recurrence with negative (131) I whole-body scan results: A meta-analysis. *Head and Neck*. 2016;38:316–327.
- [55] Grewal RK, Ho A and Schoder H. Novel Approaches to Thyroid Cancer Treatment and Response Assessment. *Seminars in Nuclear Medicine*. 2016;46:109–118.

- [56] Ranade R, Kand P and Basu S. Value of 18F-FDG PET negativity and Tg suppressibility as markers of prognosis in patients with elevated Tg and 131I-negative differentiated thyroid carcinoma (TENIS syndrome). *Nuclear Medicine Communications*. 2015;36:1014–1020.
- [57] Kist JW, de Keizer B, van der Vlies M, Brouwers AH, van der Zant FM, Hermsen R, Huysmans D, Stokkel MP, Hoekstra OS and Vogel WV. 124I PET/CT to predict the outcome of blind 131I treatment in patients with biochemical recurrence of differentiated thyroid cancer; results of a multicenter diagnostic cohort study (THYROPET). *Journal of Nuclear Medicine: Official Publication, Society of Nuclear Medicine*. 2015.
- [58] Phan HT, Jager PL, van der Wal JE, Sluiter WJ, Plukker JT, Dierckx RA, Wolffenbittel BH and Links TP. The follow-up of patients with differentiated thyroid cancer and undetectable thyroglobulin (Tg) and Tg antibodies during ablation. *European Journal of Endocrinology/European Federation of Endocrine Societies*. 2008;158:77–83.
- [59] Van Nostrand D, Khorjekar GR, O'Neil J, Moreau S, Atkins FB, Kharazi P, Mete M, Chennupati SP, Burman KD and Wartofsky L. Recombinant human thyroid-stimulating hormone versus thyroid hormone withdrawal in the identification of metastasis in differentiated thyroid cancer with 131I planar whole-body imaging and 124I PET. *Journal of Nuclear Medicine: Official Publication, Society of Nuclear Medicine*. 2012;53:359–362.
- [60] Khorjekar GR, Van Nostrand D, Garcia C, O'Neil J, Moreau S, Atkins FB, Mete M, Orquiza MH, Burman K and Wartofsky L. Do negative 124I pretherapy positron emission tomography scans in patients with elevated serum thyroglobulin levels predict negative 131I posttherapy scans? *Thyroid: Official Journal of the American Thyroid Association*. 2014;24:1394–1399.
- [61] Lee J, Nah KY, Kim RM, Oh YJ, An YS, Yoon JK, An GI, Choi TH, Cheon GJ, Soh EY and Chung WY. Effectiveness of [(124)I]-PET/CT and [(18)F]-FDG-PET/CT for localizing recurrence in patients with differentiated thyroid carcinoma. *Journal of Korean Medical Science*. 2012;27:1019–1026.
- [62] Usmani S, Esmail A, Marafi F, Al Deen S, Abu Huda F and Al Kandari F. 111In-pentetreotide scintigraphy and 18F FDG PET-CT in differentiated thyroid carcinoma metastases with negative whole body radioiodine scan. *The Gulf Journal of Oncology*. 2015;1:7–13.
- [63] Ambrosini V, Nanni C and Fanti S. The use of gallium-68 labeled somatostatin receptors in PET/CT imaging. *PET Clinics*. 2014;9:323–329.
- [64] Taieb D, Garrigue P, Bardies M, Abdullah AE and Pacak K. Application and Dosimetric Requirements for Gallium-68-labeled Somatostatin Analogues in Targeted Radionuclide Therapy for Gastroenteropancreatic Neuroendocrine Tumors. *PET Clinics*. 2015;10:477–486.
- [65] Lauri C, Di Traglia S, Galli F, Pizzichini P and Signore A. Current status of PET imaging of differentiated thyroid cancer with second generation radiopharmaceuticals. *The*

Quarterly Journal of Nuclear Medicine and Molecular Imaging: Official Publication of the Italian Association of Nuclear Medicine (AIMN) [and] the International Association of Radiopharmacology (IAR), [and] Section of the So. 2015;59:105–115.

- [66] Giovanella L, Bongiovanni M and Trimboli P. Diagnostic value of thyroglobulin assay in cervical lymph node fine-needle aspirations for metastatic differentiated thyroid cancer. *Current Opinion in Oncology*. 2013;25:6–13.
- [67] Torres MR, Nobrega Neto SH, Rosas RJ, Martins AL, Ramos AL and da Cruz TR. Thyroglobulin in the washout fluid of lymph-node biopsy: what is its role in the follow-up of differentiated thyroid carcinoma? *Thyroid: Official Journal of the American Thyroid Association*. 2014;24:7–18.
- [68] Boi F, Baghino G, Atzeni F, Lai ML, Faa G and Mariotti S. The diagnostic value for differentiated thyroid carcinoma metastases of thyroglobulin (Tg) measurement in washout fluid from fine-needle aspiration biopsy of neck lymph nodes is maintained in the presence of circulating anti-Tg antibodies. *The Journal of Clinical Endocrinology and Metabolism*. 2006;91:1364–1369.
- [69] Snozek CL, Chambers EP, Reading CC, Sebo TJ, Sistrunk JW, Singh RJ and Grebe SK. Serum thyroglobulin, high-resolution ultrasonography, and lymph node thyroglobulin in diagnosis of differentiated thyroid carcinoma nodal metastases. *The Journal of Clinical Endocrinology and Metabolism*. 2007;92:4278–4281.
- [70] Grani G and Fumarola A. Thyroglobulin in lymph node fine-needle aspiration wash-out: a systematic review and meta-analysis of diagnostic accuracy. *The Journal of Clinical Endocrinology and Metabolism*. 2014;99:1970–1982.
- [71] Van Nostrand D. Sialoadenitis secondary to (1)(3)(1)I therapy for well-differentiated thyroid cancer. *Oral Diseases*. 2011;17:154–161.
- [72] Fard-Esfahani A, Emami-Ardekani A, Fallahi B, Fard-Esfahani P, Beiki D, Hassanzadeh-Rad A and Eftekhari M. Adverse effects of radioactive iodine-131 treatment for differentiated thyroid carcinoma. *Nuclear Medicine Communications*. 2014;35:808–817.
- [73] Schroeder PR, Haugen BR, Pacini F, Reiners C, Schlumberger M, Sherman SI, Cooper DS, Schuff KG, Braverman LE, Skarulis MC, Davies TF, Mazzaferri EL, Daniels GH, Ross DS, Luster M, Samuels MH, Weintraub BD, Ridgway EC and Ladenson PW. A comparison of short-term changes in health-related quality of life in thyroid carcinoma patients undergoing diagnostic evaluation with recombinant human thyrotropin compared with thyroid hormone withdrawal. *The Journal of Clinical Endocrinology and Metabolism*. 2006;91:878–884.
- [74] Luster M, Felbinger R, Dietlein M and Reiners C. Thyroid hormone withdrawal in patients with differentiated thyroid carcinoma: a one hundred thirty-patient pilot survey on consequences of hypothyroidism and a pharmaco-economic comparison to recombinant thyrotropin administration. *Thyroid: Official Journal of the American Thyroid Association*. 2005;15:1147–1155.

- [75] Ma C, Kuang A and Xie J. Radioiodine therapy for differentiated thyroid carcinoma with thyroglobulin positive and radioactive iodine negative metastases. *The Cochrane Database of Systematic Reviews*. 2009;Cd006988.
- [76] Ma C, Xie J and Kuang A. Is empiric ¹³¹I therapy justified for patients with positive thyroglobulin and negative ¹³¹I whole-body scanning results? *Journal of Nuclear Medicine: Official Publication, Society of Nuclear Medicine*. 2005;46:1164–1170.
- [77] Schlumberger M, Mancusi F, Baudin E and Pacini F. ¹³¹I therapy for elevated thyroglobulin levels. *Thyroid: Official Journal of the American Thyroid Association*. 1997;7:273–276.
- [78] Schlumberger M, Tubiana M, De Vathaire F, Hill C, Gardet P, Travagli JP, Fragu P, Lumbroso J, Caillou B and Parmentier C. Long-term results of treatment of 283 patients with lung and bone metastases from differentiated thyroid carcinoma. *The Journal of Clinical Endocrinology and Metabolism*. 1986;63:960–967.
- [79] Pineda JD, Lee T, Ain K, Reynolds JC and Robbins J. Iodine-¹³¹ therapy for thyroid cancer patients with elevated thyroglobulin and negative diagnostic scan. *The Journal of Clinical Endocrinology and Metabolism*. 1995;80:1488–1492.
- [80] Coelho SM, Vaisman M and Carvalho DP. Tumour re-differentiation effect of retinoic acid: a novel therapeutic approach for advanced thyroid cancer. *Current Pharmaceutical Design*. 2005;11:2525–2531.
- [81] Yamazaki CA, Padovani RP, Biscolla RP, Ikejiri ES, Marchetti RR, Castiglioni ML, Matsumura LK, Maciel RM and Furlanetto RP. Lithium as an adjuvant in the postoperative ablation of remnant tissue in low-risk thyroid carcinoma. *Thyroid: Official Journal of the American Thyroid Association*. 2012;22:1002–1006.
- [82] Ho AL, Grewal RK, Leboeuf R, Sherman EJ, Pfister DG, Deandreis D, Pentlow KS, Zanzonico PB, Haque S, Gavane S, Ghossein RA, Ricarte-Filho JC, Dominguez JM, Shen R, Tuttle RM, Larson SM and Fagin JA. Selumetinib-enhanced radioiodine uptake in advanced thyroid cancer. *The New England Journal of Medicine*. 2013;368:623–632.
- [83] Carvalho DP and Ferreira AC. The importance of sodium/iodide symporter (NIS) for thyroid cancer management. *Arquivos brasileiros de endocrinologia e metabologia*. 2007;51:672–682.
- [84] Chung T, Youn H, Yeom CJ, Kang KW and Chung JK. Glycosylation of Sodium/Iodide Symporter (NIS) Regulates Its Membrane Translocation and Radioiodine Uptake. *PLoS One*. 2015;10:e0142984.
- [85] Li W, Tan J, Wang P and Wu P. Cotransfected sodium iodide symporter and human tyroperoxidase genes following human telomerase reverse transcriptase promoter for targeted radioiodine therapy of malignant glioma cells. *Cancer Biotherapy and Radiopharmaceuticals*. 2011;26:443–451.

- [86] Dohan O, De la Vieja A, Paroder V, Riedel C, Artani M, Reed M, Ginter CS and Carrasco N. The sodium/iodide Symporter (NIS): characterization, regulation, and medical significance. *Endocrine Reviews*. 2003;24:48–77.
- [87] Cheng W, Fu H, Feng F, Ma C, Li J, Chen S and Wang H. Efficacy of lentiviral-mediated transfection of hTSHR in poorly differentiated thyroid carcinoma cell line. *Nuclear Medicine and Biology*. 2013;40:576–580.
- [88] Feng F, Wang H, Hou S and Fu H. Re-induction of cell differentiation and (131)I uptake in dedifferentiated FTC-133 cell line by TSHR gene transfection. *Nuclear Medicine and Biology*. 2012;39:1261–1265.
- [89] Durante C, Puxeddu E, Ferretti E, Morisi R, Moretti S, Bruno R, Barbi F, Avenia N, Scipioni A, Verrienti A, Tosi E, Cavaliere A, Gulino A, Filetti S and Russo D. BRAF mutations in papillary thyroid carcinomas inhibit genes involved in iodine metabolism. *The Journal of Clinical Endocrinology and Metabolism*. 2007;92:2840–2843.
- [90] Liu D, Hu S, Hou P, Jiang D, Condouris S and Xing M. Suppression of BRAF/MEK/MAP kinase pathway restores expression of iodide-metabolizing genes in thyroid cells expressing the V600E BRAF mutant. *Clinical Cancer Research: An Official Journal of the American Association for Cancer Research*. 2007;13:1341–1349.
- [91] Ye X, Zhu Y and Cai J. Relationship between toxicities and clinical benefits of newly approved tyrosine kinase inhibitors in thyroid cancer: A meta-analysis of literature. *Journal of Cancer Research and Therapeutics*. 2015;11 Suppl 2:C185–C190.
- [92] Scott LJ. Lacosamide: A Review in Focal Seizures in Patients with Epilepsy. *Drugs*. 2015;75:2143–2154.
- [93] Gruber JJ and Colevas AD. Differentiated thyroid cancer: focus on emerging treatments for radioactive iodine-refractory patients. *The Oncologist*. 2015;20:113–126.
- [94] Shen CT, Qiu ZL and Luo QY. Sorafenib in the treatment of radioiodine-refractory differentiated thyroid cancer: a meta-analysis. *Endocrine-Related Cancer*. 2014;21:253–261.
- [95] Cooper DS, Doherty GM, Haugen BR, Kloos RT, Lee SL, Mandel SJ, Mazzaferri EL, McIver B, Sherman SI and Tuttle RM. Management guidelines for patients with thyroid nodules and differentiated thyroid cancer. *Thyroid: Official Journal of the American Thyroid Association*. 2006;16:109–142.
- [96] McGriff NJ, Csako G, Gourgiotis L, Lori CG, Pucino F and Sarlis NJ. Effects of thyroid hormone suppression therapy on adverse clinical outcomes in thyroid cancer. *Annals of Medicine*. 2002;34:554–564.
- [97] Durante C, Haddy N, Baudin E, Leboulleux S, Hartl D, Travagli JP, Caillou B, Ricard M, Lumbroso JD, De Vathaire F and Schlumberger M. Long-term outcome of 444 patients with distant metastases from papillary and follicular thyroid carcinoma:

benefits and limits of radioiodine therapy. *The Journal of Clinical Endocrinology and Metabolism*. 2006;91:2892–2899.

- [98] Linskey ME, Andrews DW, Asher AL, Burri SH, Kondziolka D, Robinson PD, Ammirati M, Cobbs CS, Gaspar LE, Loeffler JS, McDermott M, Mehta MP, Mikkelsen T, Olson JJ, Paleologos NA, Patchell RA, Ryken TC and Kalkanis SN. The role of stereotactic radiosurgery in the management of patients with newly diagnosed brain metastases: a systematic review and evidence-based clinical practice guideline. *Journal of Neuro-oncology*. 2010;96:45–68.
- [99] Kalkanis SN, Kondziolka D, Gaspar LE, Burri SH, Asher AL, Cobbs CS, Ammirati M, Robinson PD, Andrews DW, Loeffler JS, McDermott M, Mehta MP, Mikkelsen T, Olson JJ, Paleologos NA, Patchell RA, Ryken TC and Linskey ME. The role of surgical resection in the management of newly diagnosed brain metastases: a systematic review and evidence-based clinical practice guideline. *Journal of Neuro-oncology*. 2010;96:33–43.
- [100] Droz JP, Schlumberger M, Rougier P, Ghosn M, Gardet P and Parmentier C. Chemotherapy in metastatic nonanaplastic thyroid cancer: experience at the Institut Gustave-Roussy. *Tumori*. 1990;76:480–483.
- [101] Ahuja S and Ernst H. Chemotherapy of thyroid carcinoma. *Journal of Endocrinological Investigation*. 1987;10:303–310.
- [102] Mazzaferri EL. Management of a solitary thyroid nodule. *The New England Journal of Medicine*. 1993;328:553–559.
- [103] Sherman SI. Cytotoxic chemotherapy for differentiated thyroid carcinoma. *Clinical Oncology (Royal College of Radiologists (Great Britain))*. 2010;22:464–468.
- [104] Hay ID, Lee RA, Davidge-Pitts C, Reading CC and Charboneau JW. Long-term outcome of ultrasonography-guided percutaneous ethanol ablation of selected “recurrent” neck nodal metastases in 25 patients with TNM stages III or IVA papillary thyroid carcinoma previously treated by surgery and 131I therapy. *Surgery*. 2013;154:1448–1454; discussion 1454–1455.
- [105] Guenette JP, Monchik JM and Dupuy DE. Image-guided ablation of postsurgical locoregional recurrence of biopsy-proven well-differentiated thyroid carcinoma. *Journal of Vascular and Interventional Radiology: JVIR*. 2013;24:672–679.
- [106] Heilo A, Sigstad E, Fagerlid KH, Haskjold OI, Groholt KK, Berner A, Bjoro T and Jorgensen LH. Efficacy of ultrasonography-guided percutaneous ethanol injection treatment in patients with a limited number of metastatic cervical lymph nodes from papillary thyroid carcinoma. *The Journal of Clinical Endocrinology and Metabolism*. 2011;96:2750–2755.
- [107] Park KW, Shin JH, Han BK, Ko EY and Chung JH. Inoperable symptomatic recurrent thyroid cancers: preliminary result of radiofrequency ablation. *Annals of Surgical Oncology*. 2011;18:2564–2568.

- [108] Baek JH, Kim YS, Sung JY, Choi H and Lee JH. Locoregional control of metastatic well-differentiated thyroid cancer by ultrasonography-guided radiofrequency ablation. *AJR American Journal of Roentgenology*. 2011;197:W331–W336.
- [109] Monchik JM, Donatini G, Iannuccilli J and Dupuy DE. Radiofrequency ablation and percutaneous ethanol injection treatment for recurrent local and distant well-differentiated thyroid carcinoma. *Annals of Surgery*. 2006;244:296–304.
- [110] Papini E, Bizzarri G, Bianchini A, Valle D, Misischi I, Guglielmi R, Salvatori M, Solbiati L, Crescenzi A, Pacella CM and Gharib H. Percutaneous ultrasonography-guided laser ablation is effective for treating selected nodal metastases in papillary thyroid cancer. *The Journal of Clinical Endocrinology and Metabolism*. 2013;98:E92–E97.