
Angiography and Endovascular Therapy for Below-the-Knee Artery Disease

Akihiro Higashimori

Additional information is available at the end of the chapter

<http://dx.doi.org/10.5772/67179>

Abstract

Critical limb ischemia (CLI) is growing in global prevalence and is associated with high rates of limb loss and mortality. “Endovascular-first” approach is considered to be the current standard care for symptomatic infrainguinal atherosclerotic disease. Given the facts that many CLI patients have severe comorbidities and endovascular-first approach is a common practice and may reduce the magnitude of the surgical trauma and systemic complications. In this chapter, updated angiographic approach for below-the-knee disease is described with endovascular technique.

Keywords: critical limb ischemia, below-the-knee disease, angiosome, indigo carmine

1. Introduction

Critical limb ischemia (CLI) is growing in global prevalence and is associated with high rates of limb loss and mortality. The “endovascular-first” approach is considered to be the current standard treatment for symptomatic infrainguinal atherosclerotic disease [1]. Given the fact that many CLI patients have severe comorbidities, the endovascular-first approach is most common since it reduces the magnitude of surgical trauma and systemic complications. In this chapter, an updated angiographic approach for below-the-knee artery disease is described with endovascular techniques.

2. Basic angiographic technique for below-the-knee artery

2.1. Vascular anatomy of the below the knee

Normally, from the direct continuation of the popliteal artery and past the branch of the anterior tibial artery (ATA) is the tibioperoneal trunk. This vascular segment splits into the posterior tibial artery (PTA) and the peroneal artery (**Figure 1**).

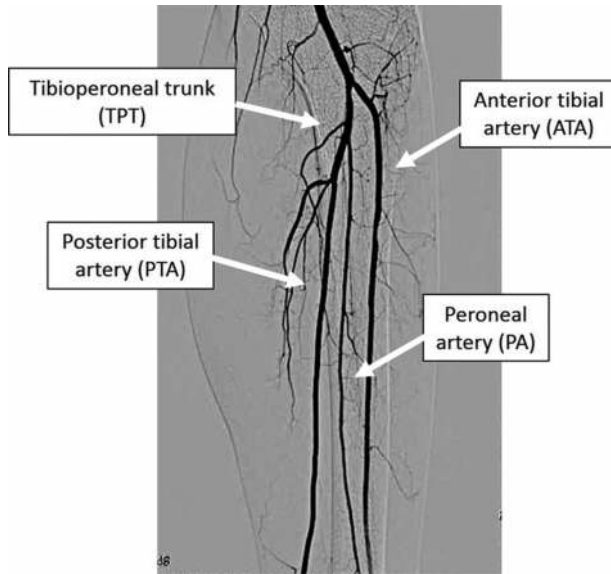


Figure 1. Anteroposterior view of the tibial trifurcation shows anterior tibial artery, tibioperoneal trunk, peroneal artery, and posterior tibial artery.

The distal peroneal artery splits into the anterior malleolar branch and the calcaneal branch (**Figure 2**).

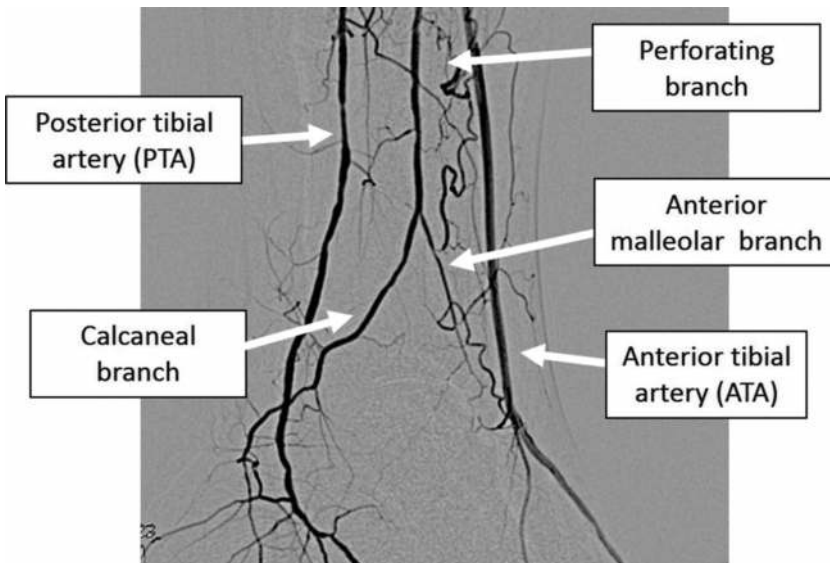


Figure 2. Lateral view at the distal leg shows the distal anterior and tibial arteries and peroneal artery. Distal peroneal artery splits into the anterior malleolar branch and calcaneal branch.

The dorsal pedis artery is a continuation of the ATA in the foot. The PTA bifurcates into the lateral plantar artery and medial plantar artery (**Figure 3**).

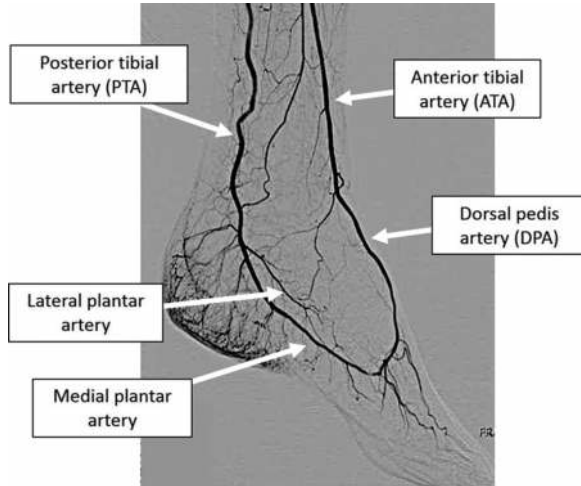


Figure 3. Lateral view of the ankle shows distal anterior tibial artery and posterior tibial artery. Dorsal pedis artery is a continuation of the anterior tibial artery in the foot. Posterior tibial artery bifurcates into the lateral plantar artery and medial plantar artery.

By definition, the popliteal artery ends at the origin of the first tibial artery, which typically is the ATA. In about 4% of cases, we find a so-called high origin of the ATA at the level of the knee joint or even some centimeters more proximal (**Figure 4**).

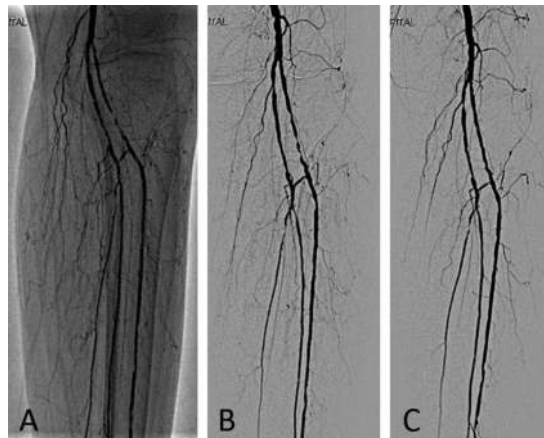


Figure 4. (A and B) High division of popliteal artery branching and anterior tibial artery at the knee joint. The anterior tibial artery was diseased. (C) Balloon angioplasty was performed in the anterior tibial artery.

Similarly, in just as small proportion of the population, a high origin of the PTA has been described. As a variation, a trifurcation of the popliteal artery into all three lower leg arteries at the same point has been observed in 0.4% of patients. The PTA may be missing completely in 1–5% of the normal adult population (**Figure 5**) [2].

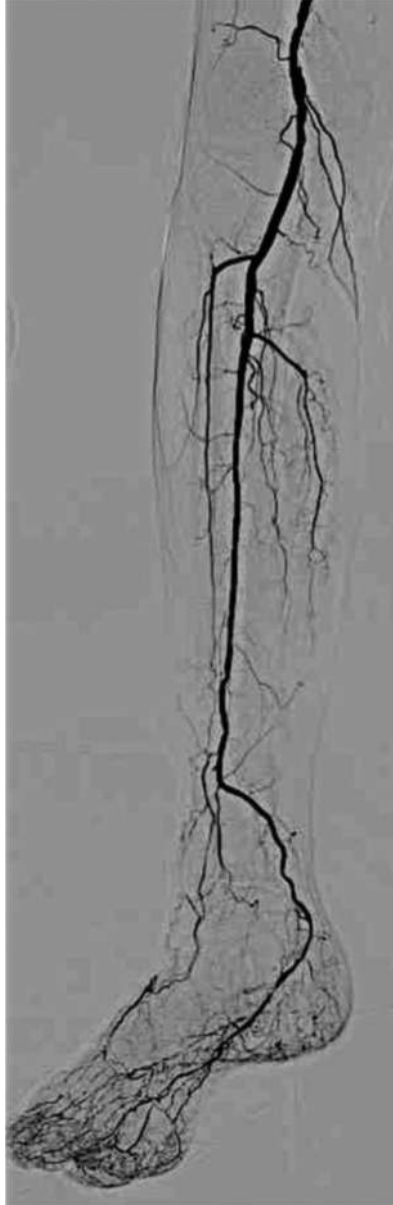

Figure 5. The posterior tibial artery is missing completely. Peroneal artery connects through the tibial arteries.

Branching variations of below-the-knee arteries are common. A practical triad classification of anatomical variations in the branching pattern has been reported [3], that is, Type 1, Type 1-B, Type 2-A, Type 3-A, and Type 3-B (Figure 6) [4].

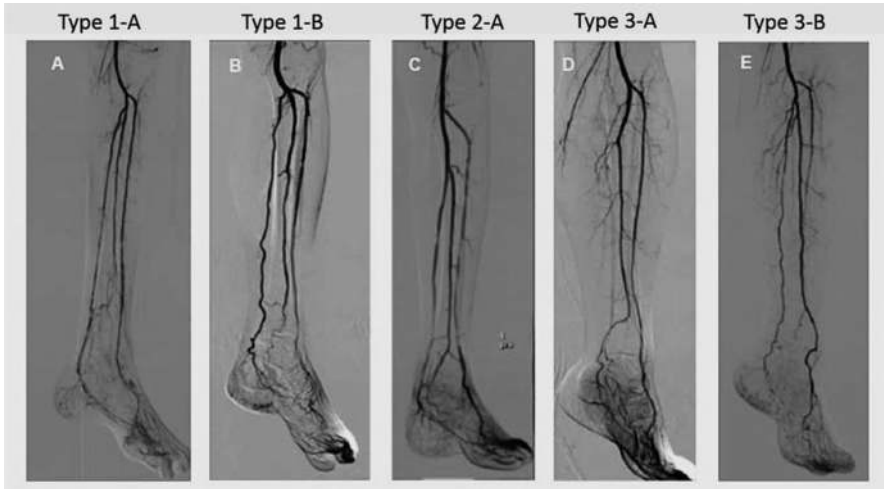


Figure 6. Anatomical variation of tibial arteries. (A) Type 1-A: normal level of arterial branching and most common pattern. The first branch is anterior tibial artery and peroneal trunk separates into peroneal and posterior tibial arteries. (B) Type 1-B: normal level of arterial branching. The three tibial arteries show trifurcation. (C) Type 2-A: high division of popliteal artery branching and the anterior tibial artery arises at the knee joint. (D) Type 3-A: hypoplastic posterior tibial artery and peroneal artery provide a distal supply to the plantar side of the foot. (E) Type 3-B: hypoplastic anterior tibial artery and peroneal artery provide distal supply to the dorsal side of the foot.

There are many more anatomical variations and we have to keep in mind that these variant arteries are rather common (Figures 7 and 8).

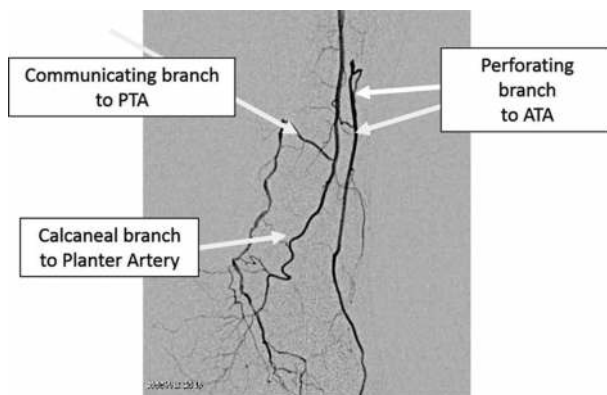


Figure 7. When ATA and PTA are occluded, the peroneal artery may function as the sole blood supply of the foot. Left ATA and PTA are occluded. Anterior terminal branch (perforating branch) of peroneal artery gives collateral to ATA. Similarly, posterior terminal branch (communicating branch) gives collateral to PTA.

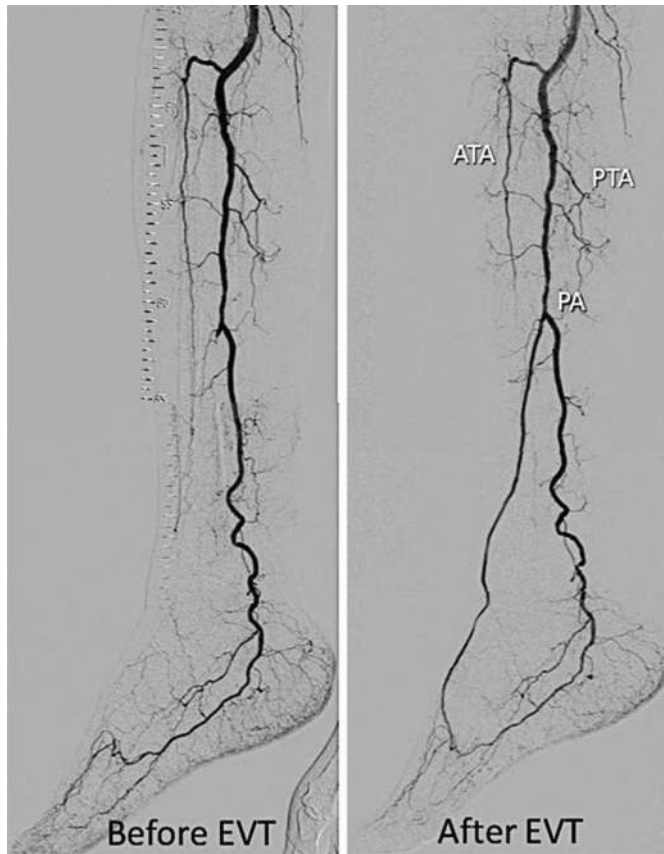


Figure 8. Based on pre-interventional below-the-knee angiography, it was assumed that anterior tibial artery is occluded. Post-interventional below-the-knee angiography showed that anterior tibial artery is hypoplastic. Peroneal artery continues to the dorsal pedis artery.

2.2. Angiography for below-the-knee arteries

Before intervention in below-the-knee vessels, the target vessel should be clearly identified. After confirming that no inflow disease is present, below-the-knee angiography is performed since the presence of inflow disease results in a less clear image [4]. **Figure 9** shows the basic image of below-the-knee angiography.

Only the AP view is insufficient to clearly visualize the below-the-knee anatomy and diseased segment. Four views are mandatory to see all below-the-knee arteries. There are two right anterior oblique (RAO) views and two left anterior oblique (LAO) views. In the upper RAO view, the proximal left ATA is well visualized and, in the lower RAO view, the three distal tibial arteries are well observed. In the upper LAO view, bifurcation of the peroneal artery and PTA is well visualized. In the lower LAO view, the ATA and peroneal artery overlap and these two vessels cannot be separated (**Figure 10**).

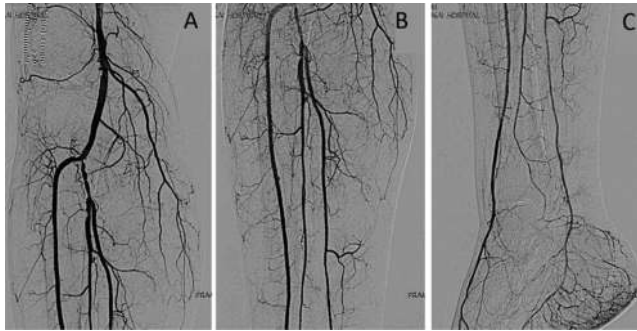


Figure 9. Basic below-the-knee angiography. Only AP view is insufficient to visualize the below-the-knee anatomy and diseased segment.

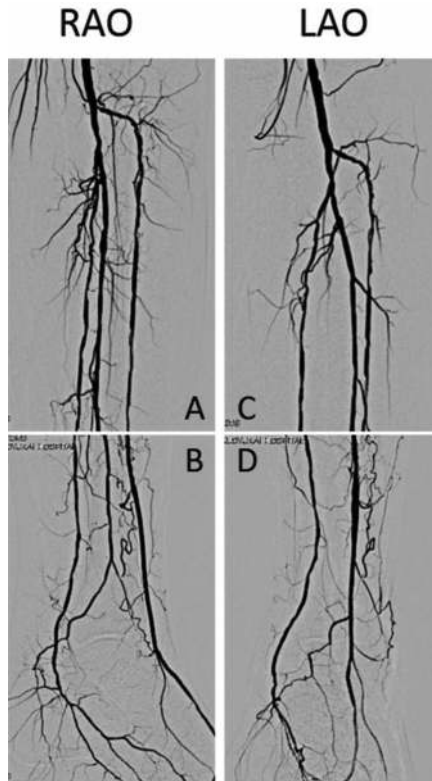


Figure 10. Basic below-the-knee angiography. (A) Upper right anterior oblique view. Proximal anterior tibial artery is well visualized, but peroneal artery and posterior tibial artery are overlapped. (B) Lower right anterior oblique view. In this view, distal three tibial arteries are separated. (C) Upper left anterior oblique view. Proximal peroneal artery and posterior tibial artery are well separated. (D) Lower left anterior oblique view. Distal posterior tibial artery is well visualized, but distal anterior tibial artery and peroneal artery are overlapped.

Figure 11 shows the basic angiographic steps. A femoropopliteal artery angiogram should be taken to rule out inflow disease (**Figure 11A**). After confirming that no inflow disease is present, below-the-knee angiography is performed through a catheter located at the distal popliteal artery (**Figure 11B**). Four views are taken before angioplasty (**Figure 11C**) and four more views after angioplasty (**Figure 11D**).

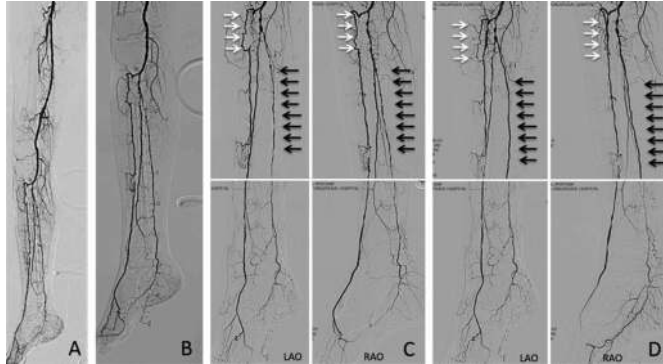


Figure 11. (A) Pre-interventional angiography for critical limb ischemia. Ipsilateral right femoropopliteal artery angiogram which can rule out inflow disease. (B) Below-the-knee angiography showed the entire three tibial arteries. (C) Pre-interventional below-the-knee angiography. This angiography showed the diseased proximal anterior tibial artery (white arrow) and mid-portion of the posterior tibial artery (black arrow). (D) Post-intervention below-the-knee angiography showed proximal anterior tibial artery and mid-posterior tibial artery successfully recanalized. Pre- and post-angiography were taken in the same angle and view.

If the patients have impaired renal function, four views are not mandatory. Moreover, pre- and post-interventional angiography should be taken in the same image size and angle (**Figures 12 and 13**).

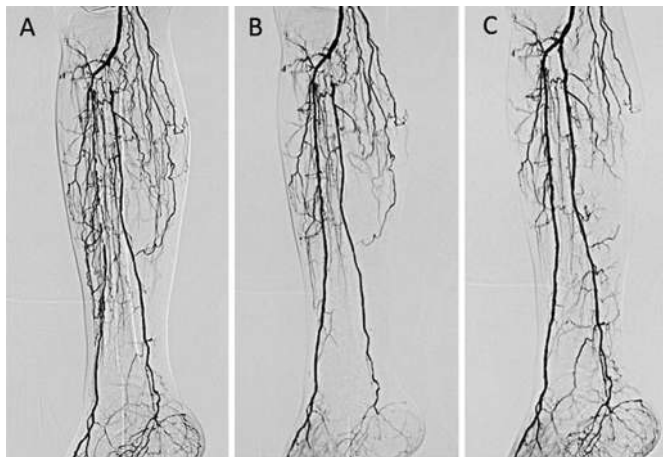


Figure 12. (A) Below-the-knee angiogram of pre-intervention. Right anterior tibial artery, peroneal artery, and posterior tibial artery were occluded. (B) Angiography of postanterior tibial artery intervention. (C) Angiography of postanterior and posterior tibial artery intervention. Peroneal artery was still occluded but sufficient blood flow seems to be obtained.

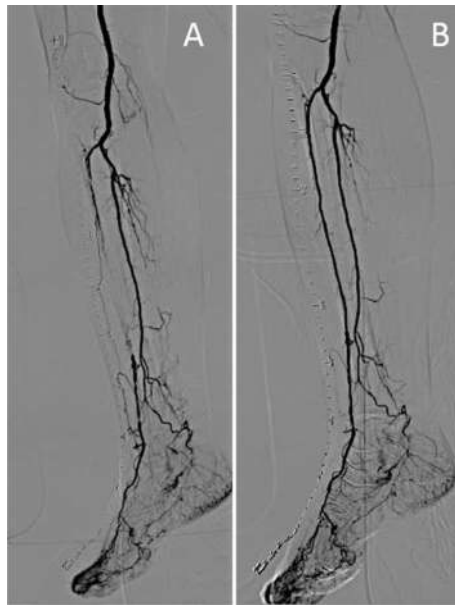


Figure 13:. Pre- (A) and post- (B) interventional angiography should be taken in the same image size and angle.

3. Basic angiographic technique for below-the-ankle arteries

3.1. Vascular anatomy of below-the-ankle arteries

The vascular anatomy of the foot is composed of the anterior and posterior circulation connected through the pedal arch. The anterior circulation consists of the dorsal pedis artery, lateral tarsal artery, and arcuate artery (Figure 14).

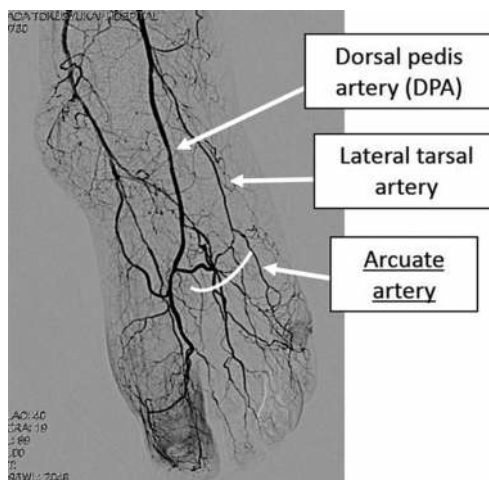


Figure 14. Anterior circulation consists of dorsal pedis artery, lateral tarsal artery, and arcuate artery.

The dorsalis pedis artery is a continuation of the anterior tibial artery distal to the ankle. The branches of the dorsalis pedis include the lateral and medial tarsal, first dorsal metatarsal, deep plantar, and arcuate arteries. The arcuate artery arises near the medial cuneiform, passing laterally over the metatarsal bases deep to the digital extensor tendons and gives rise to the second through fourth dorsal metatarsal arteries before anastomosing with the lateral tarsal artery. The arcuate artery is classically described as being the primary source of blood for the second, third, and fourth dorsal metatarsal arteries [5]; however, a combination of the arcuate, lateral tarsal, and proximal perforating arteries may be involved depending on an individual’s vascular anatomy. The posterior circulation consists of the medial plantar artery and lateral plantar artery. These two arteries have an artery-to-artery connection which constitutes the deep plantar arterial arch. The first to fourth plantar metatarsal arteries are the branches of the deep plantar arterial arch (Figures 15–17).

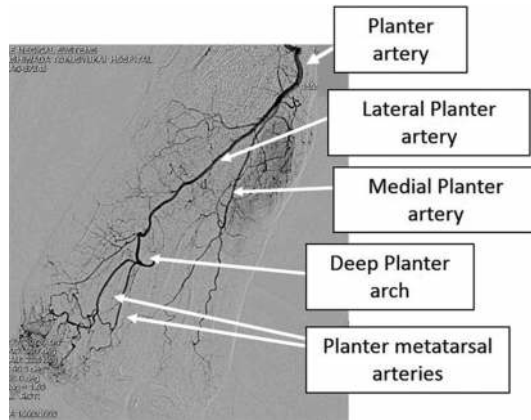


Figure 15. Posterior circulation consists of medial plantar artery and lateral plantar artery.

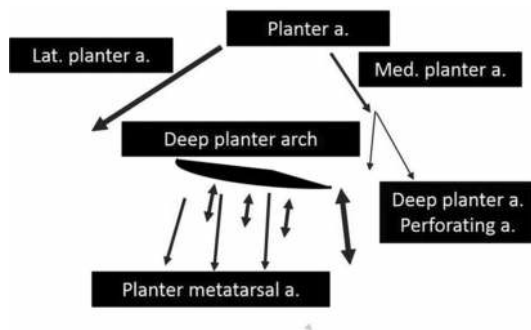


Figure 16. The digital branches originate from the anterior and posterior circulation. There are dorsal branches for each toe.

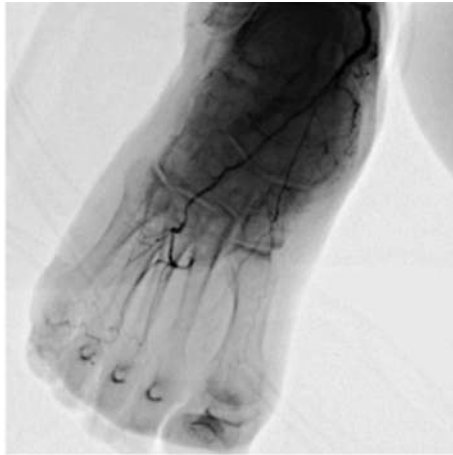


Figure 17. The digital branches originate from the anterior and posterior circulation. There are plantar branches for each toe.

Normally, the area between the anterior and posterior circulation forms the pedal arch. It primarily constitutes the deep perforating branches of the dorsal artery of the foot and the medial plantar artery. This arcade is the main supply for all distal forefoot circulation (**Figure 18**).

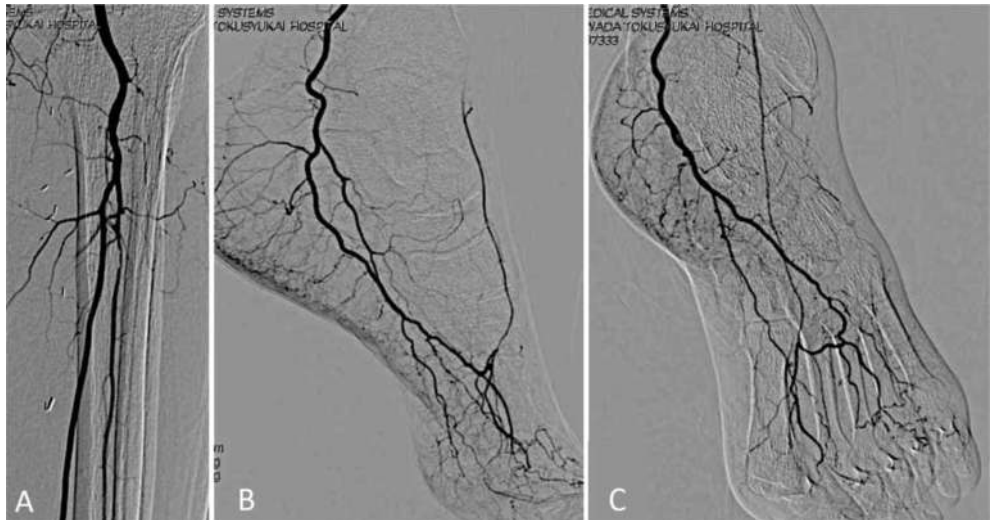


Figure 18. (A) Right anterotibial artery occluded at the proximal portion. (B) Lateral view of the right foot. Right dorsal pedis is retrograde visualized. (C) Dorsal pedis is visualized through the collateral via the deep plantar artery.

Moreover, we should keep in mind that anatomically variant arteries are quite common (**Figure 19**).

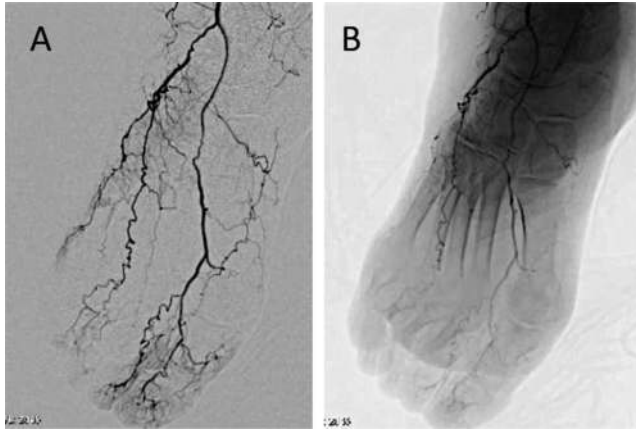


Figure 19. Angiography shows the absence of the arcuate artery and the anomalous origin of the dorsal metatarsal arteries (A) DSA image and (B) DA image.

The pedal arch at the completion of angiography has been classified as follows: Type 1, both dorsal pedis and plantar arteries are patent; Type 2A, only the dorsalis pedis artery is patent; Type 2B, only the plantar artery is patent; and Type 3, both the dorsalis pedis artery and plantar arteries are occlusive (**Figure 20**) [6].

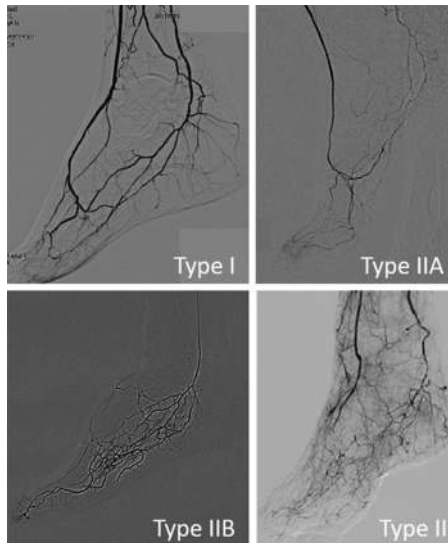


Figure 20. The pedal arch at the completion of angiography was classified into Types I, IIA, IIB, and III.

3.2. Angiography for below-the-ankle arteries

With severe ischemic limb, foot artery angiograms are hard to obtain due to patient leg movements. To minimize this problem, an injection of small amounts of contrast with inflow revascularization is essential. A typical below-the-ankle artery is shown in **Figure 21** [4].

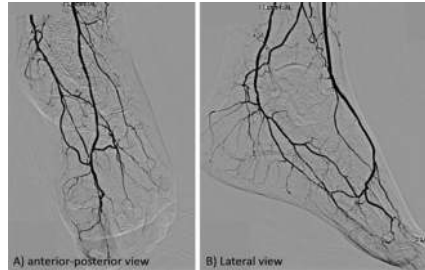


Figure 21. In the anterior view, plantaris medial and lateralis are well separated (A). In the lateral view, dorsal pedis artery is well seen but the lateral tarsal arteries are not well separated (B).

Basically, two views are sufficient: one is the anteroposterior view and the other a lateral view. In the lateral view, the dorsal pedis artery is well visualized but the lateral tarsal arteries are not well separated. In the anterior view, the medial and lateral plantar arteries are well separated. In the anterior view, the dorsalis pedis is well visualized and suited for retrograde dorsal pedis puncture (**Figures 22 and 23**).

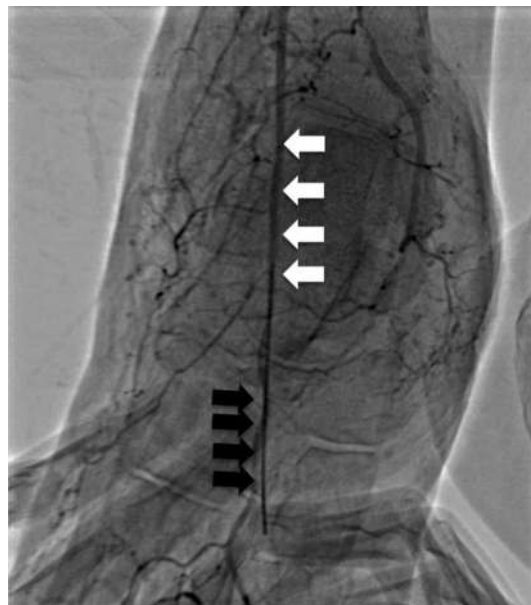

Figure 22. White arrow shows the dorsal pedis artery. Black arrow shows the puncture needle.

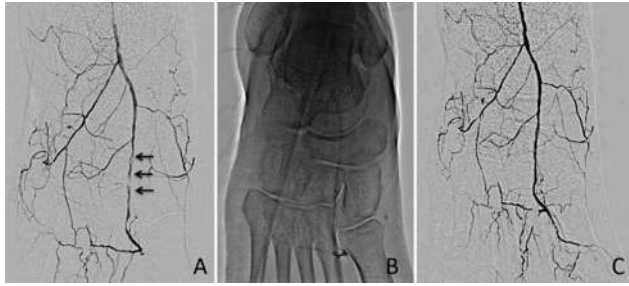


Figure 23. In anterior view, dorsal pedis artery is well visualized. Black arrow shows severe stenosis (A). This lesion was treated with 1.5 × 20-mm balloon (B). Post-angiography (C).

In the lateral view, the distal posterior tibial artery and proximal dorsalis pedis artery are well visualized and suitable for retrograde posterior tibial artery puncture (**Figures 24 and 25**).

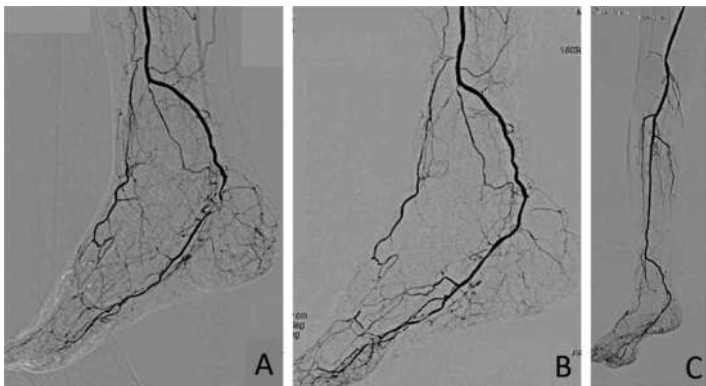


Figure 24. Balloon angioplasty to occluded plantar artery. Based on lateral angiogram, plantar artery was totally occluded (A). Using 2 × 40-mm balloon (B), the occluded vessel was recanalized (C).

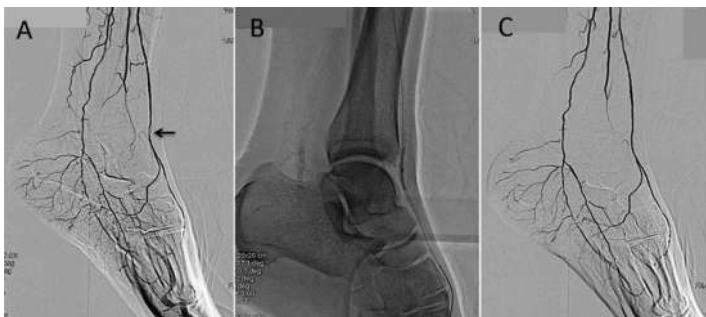

Figure 25. Based on lateral angiogram, proximal dorsal pedis artery disease is well visualized (black arrow) (A). This lesion was treated with 1.5 × 20-mm balloon (B). The stenosis lesion was recanalized (C).

4. Technical aspects of below-the-knee artery intervention

4.1. Endovascular therapy for below-the-knee artery disease

Endovascular therapy for the tibial vessels and foot arteries should be the first-line treatment in patients with CLI due to its good technical and clinical outcomes. Endovascular treatment is possible in most cases with a known low complication rate. The primary indications for tibial and foot artery intervention are limb salvage to avoid amputations. Patients with chronic leg ischemia face major future challenges and, in fact, the long-term survival rate with CLI is significantly lower than that of a matched population so that limb salvage is of major importance to such patients [2].

4.2. Access site

Antegrade access in the common femoral artery is, in our experience, the best approach to perform tibial and foot artery revascularization, with excellent guide ability of the wire and good pushability of the catheter balloons since this access site is closer to the lesions. Moreover, ultrasound-guided punctures may reduce radiation doses, screen time, and complications.

4.3. Guidewires

The tip load, tip stiffness, hydrophilic coat of the tip and body, guidewire flexibility, ability to shape, shaping memory, shaft support, torque transmission, trackability, and pushability are all critical components for a below-the-knee intervention guidewire [7]. Selection should be based on the specificities of the lesion such as localization, stenosis or chronic total occlusion (CTO), and lesion length. Non-hydrophilic guidewires allow a better tactile feel and a more controlled torque response when compared with hydrophilic wires. They are less likely to cause dissection of a vessel but have a higher resistance within the lesion, which decreases the chance of crossing, particularly “ronic total occlusions.” But some guidewires, rather than increased sharpness, may have greater tip stiffness due to weight addition which increases their penetration ability. Hydrophilic wires typically advance with minimal resistance, providing good maneuverability in tortuous and long vessels but at a cost of reduced tactile feel [8]. In the field of coronary artery disease, we only use 0.014 inch wires, but in the field of peripheral artery disease, we use 0.014 inch and 0.018 inch wires. Our first wire is the 0.014 inch Runthrough peripheral (Terumo, Tokyo, Japan) and the second wires are the 0.014 inch Cruise (Asahi Intec, Nagoya, Japan) or 0.014 inch Command (Abott Vascular, Santa Clara, CA, USA). For chronic total occlusion lesions, we use 0.018 inch wires. **Table 1** shows the wires we use in our daily practice. These five wires cover almost all of our below-the-knee and below-the-ankle procedures.

0.014" guidewires	Hydrophilic	Tip load	Remarks
Runthrough peripheral (Terumo)	N	1 g	1st wire
Cruise (Asahi intecc)	Y	1 g	2nd wire
0.018" guidewires	Hydrophilic	Tip load	Remarks
Treasure (Asahi intecc)	N	12 g	CTO lesion
Astato (Asahi intecc)	N	30 g	CTO lesion

Table 1. Guidewires for below-the-knee artery intervention.

4.4. Balloon catheter

There are many low-profile balloons of various sizes and lengths for below-the-knee intervention. The balloon platforms are mostly dependent on either a 0.014-inch or 0.018-inch system. The main objective in below-the-knee intervention is to cross a total occlusion. For this purpose, we prefer a 0.018-inch lumen size for the over-the-wire angioplasty balloon (OTW) with increased shaft strength. These balloons give adequate pushability and wire support, particularly in complex chronic total occlusions when compared to the rapid exchange monorail technique. The over-the-wire balloon catheter system with the 0.018-inch platform allows good control of the wire without resistance and a smooth exchange to the 0.018 inch or 0.014 inch wire. They also allow wire exchange without sacrificing the progress made through the lesion. Additionally, their lumen can be used to inject contrast as well as verify position and distal outflow (**Figures 26 and 27**).

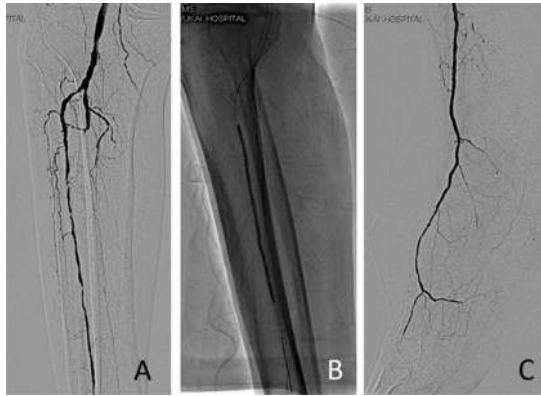


Figure 26. A 0.018-inch over-the-wire balloon catheter can be used to inject contrast, also verify position and distal outflow. (A) Pre angiography (B) Balloon dilatation (C) Tip injection.

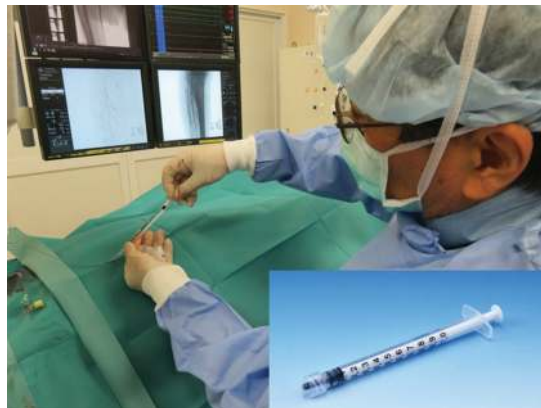


Figure 27. Injection of contrast through over-the-wire balloon. Contrast medium administered using a 1-ml Luer Lock syringe.

4.5. Transluminal recanalization for total occlusion

The first step in transluminal recanalization is to pass the proximal stenosis or negotiate the total occlusion by various wires until reaching the distal patent lumen. A drilling motion of the guidewire is used to properly penetrate and cross the lesion. As the initial wire, we prefer a 0.014-inch soft guidewire (**Table 1**) with an angulated tip since these very soft tips with coated wires have a higher chance of crossing the micro-channel without penetrating the subintimal space.

When we could not cross this soft 0.014 inch wire, it was exchanged with a 12-g 0.018-inch hard guidewire. The 0.018-inch wire has more controllability and penetration power compared to hard 0.014-inch wires. These wires are used with the OTW balloon catheter for wire support and exchange. In addition, the OTW balloon catheter can be used for tip injection to guide the wire and to understand what the problem is. However, in a 0.014-inch OTW balloon, there is a limitation for contrast injection (**Figure 28**).

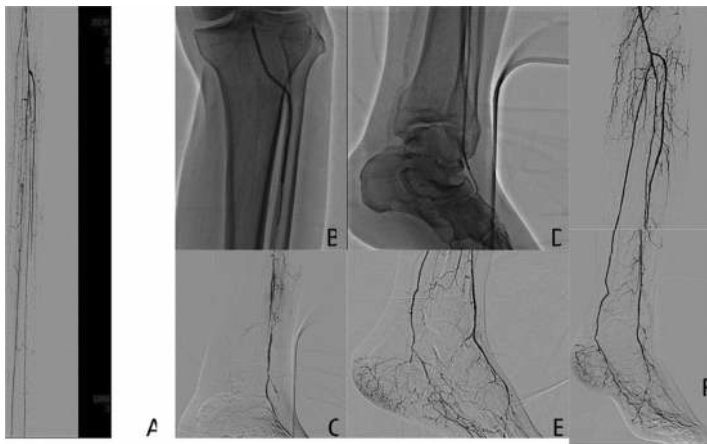

Figure 28. (A) Baseline angiography showed popliteal artery had severe stenosis and all below-the-knee vessels were occluded. (B) 0.014-inch soft guidewire was advanced into anterior tibial artery with 2.5×100 -mm over-the-wire balloon catheter. The balloon was inflated at the distal popliteal artery and proximal anterior tibial artery. (C) Injection of contrast through over-the-wire balloon at proximal anterior tibial artery. Angiogram clarifies the position of the distal tip of the over-the-wire balloon and occluded segment. (D) 0.014-inch guidewire was changed to 0.018-inch hard guidewire which succeeded in crossing the occluded segment. A 2.0×100 -mm balloon was inflated at the occluded segment. (E) Injection of contrast through over-the-wire balloon at the distal anterior tibial artery. Angiogram shows below-the-ankle vessels. (F) Final angiography shows complete revascularization was obtained.

4.6. Subintimal recanalization for total occlusion

A subintimal recanalization in below-the-knee arteries is one of the options after intraluminal attempts have failed and it was not possible to cross the lesion. Subintimal angioplasty was first described by Bolia [9], and since then there have been many publications to confirm its value and assess the clinical results of this technique to treat tibial vessels. We normally perform a subintimal recanalization in the crural arteries with a 0.018-inch J-tip guidewire (**Figure 29**) or 0.014-inch hydrophilic guidewire (Command, Abott Vascular). A balloon catheter is used to support the guidewire during subintimal progression.

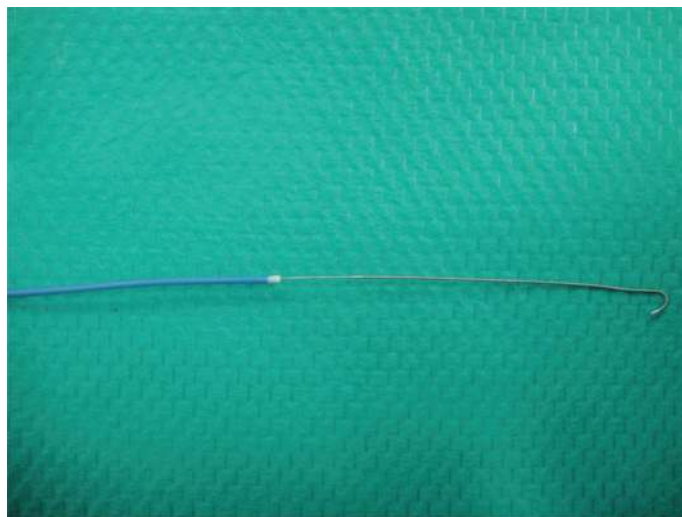


Figure 29. A 0.018-inch 1.5-mm J-tip wire (NEXUS NT 1.5J; Future Medical Design, Saitama, Japan).

4.7. Retrograde recanalization for total occlusion

When antegrade wiring cannot pass the lesion, such as the inability to reenter the patent distal true lumen after subintimal recanalization, a retrograde approach is the choice to cross the total occlusion. In these situations, the retrograde approach is an effective and safe technique for CTO interventions. Compared to other techniques such as the pedal/plantar loop technique and/or collateral wiring, retrograde distal access is easier and less risky without damaging the collateral vessels. In our daily procedures, distal retrograde access is the best technical strategy for reentry or to resolve any problems.

4.8. Techniques for distal puncture

All tibial vessels, including the anterior tibial, posterior tibial, and peroneal arteries, can be accessed in retrograde fashion. Generally, the distal anterior tibial artery or posterior tibial artery is selected because these approaches are easier to establish hemostasis under external compression. The peroneal artery can be punctured but it is difficult to achieve hemostasis. The degree of vessel opacification can be enhanced using vasodilators through the femoral access site to maximize the caliber of the arterial target. Usually, nitroglycerin is administered from the distal tip of a catheter. Patient cooperation and proper use of sedation are of utmost importance for the success of this approach. Local anesthesia at the puncture site should be minimized to make the precise puncture into the 1–2-mm vessel. The position of the foot during the access procedure is also important. When puncturing the dorsal pedis or anterior tibial artery, the foot is placed in plantar flexion (**Figure 30**).

When accessing the posterior tibial artery, we place the foot in eversion and dorsal flexion (**Figure 31**).

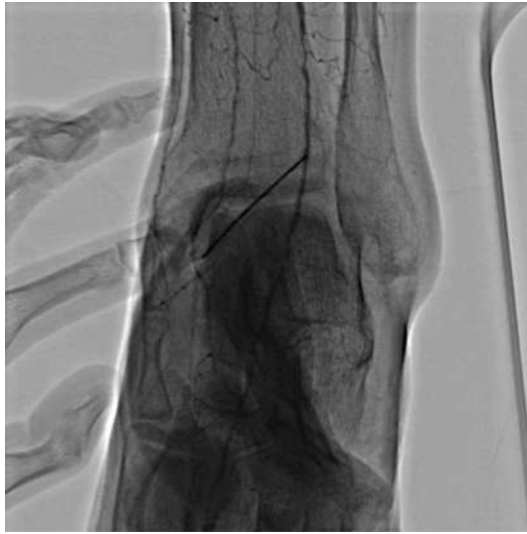

Figure 30. The dorsal pedis artery can be accessed percutaneously under fluoroscopic guidance with a micro-puncture. When accessing the dorsal pedis or anterior tibial artery, the foot is placed in plantar flexion.

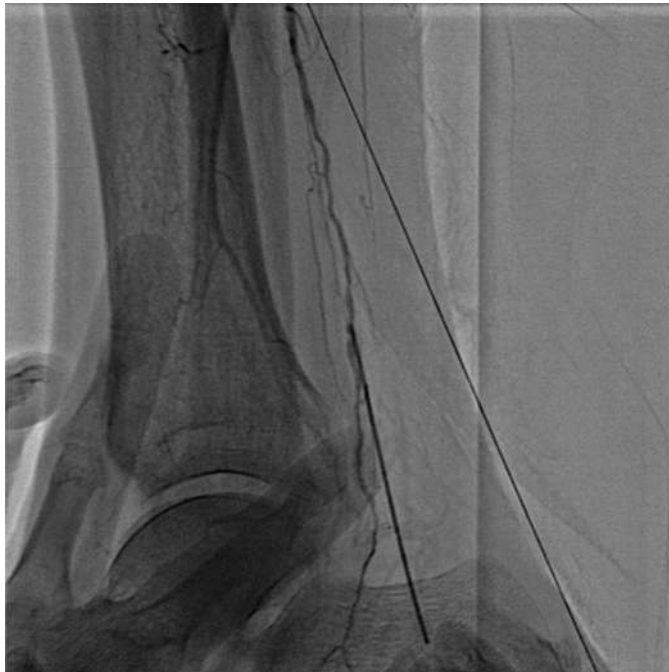

Figure 31. When accessing the posterior tibial artery, the foot is placed in eversion and dorsal flexion.

Selection of the puncture point is of vital importance in the cannulation of a 0.014-inch wire so that it is necessary to find a fairly normal vessel site. A micro-puncture needle (Cook Medical Inc., Bloomington, IN, USA) is best suited for this purpose. Under fluoroscopic guidance, a small amount of contrast is injected through a proximal vessel, most often the popliteal artery. After successful puncturing which is confirmed by back bleeding, the 0.014-inch hydrophilic wire (Cruise; Asahi Intec, Tokyo, Japan) is passed through the needle into the vessel under fluoroscopic guidance (**Figure 32**). The needle is then removed and inserted into a micro-catheter (Ichibanyari; Kaneka Medical Products, Osaka, Japan). This sheathless strategy can reduce the risk of disrupting the access vessel and is easier to achieve hemostasis (**Figure 32**).

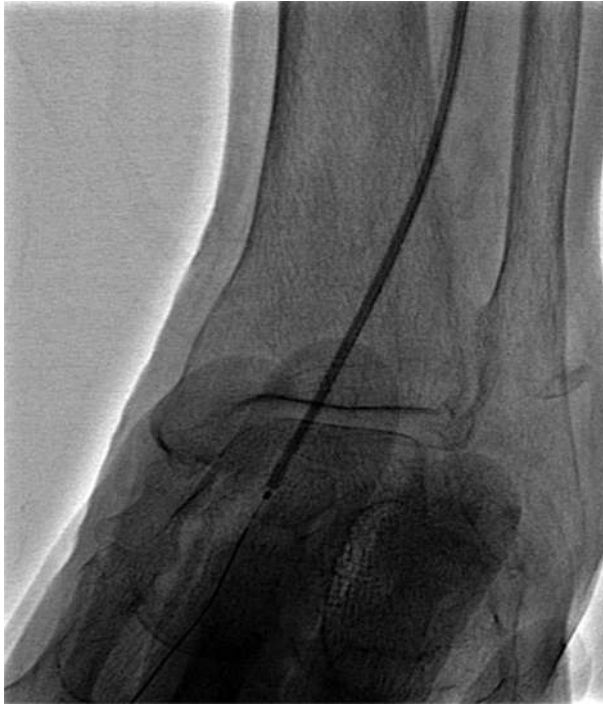

Figure 32. The retrograde micro-catheter is withdrawn and hemostasis is secured through digital compression and/or low-pressure balloon dilatation with appropriately sized balloons.

4.9. Complications

A vessel perforation by wiring could happen while attempting to cross a tibial chronic total occlusion. In most cases, bleeding due to wire perforation is of no clinical significance. However, the perforated site must be sealed. If the wire has crossed the lesion, balloon inflation is applied with low pressure and, in most cases, hemostasis can be established. However, when bleeding cannot be stopped or the wire did not cross the lesion, external compression guided by angiography or temporary balloon occlusion at the proximal to perforated site

should be tried. In conjunction with proximal balloon occlusion, an external compression method should also be performed. The Tometa-Kun compression system (Zeon Medical, Tokyo, Japan) is generally used to achieve complete hemostasis at the radial artery. The Tometa-Kun compression system is easy to use and quite an effective method for external compression (Figure 33).

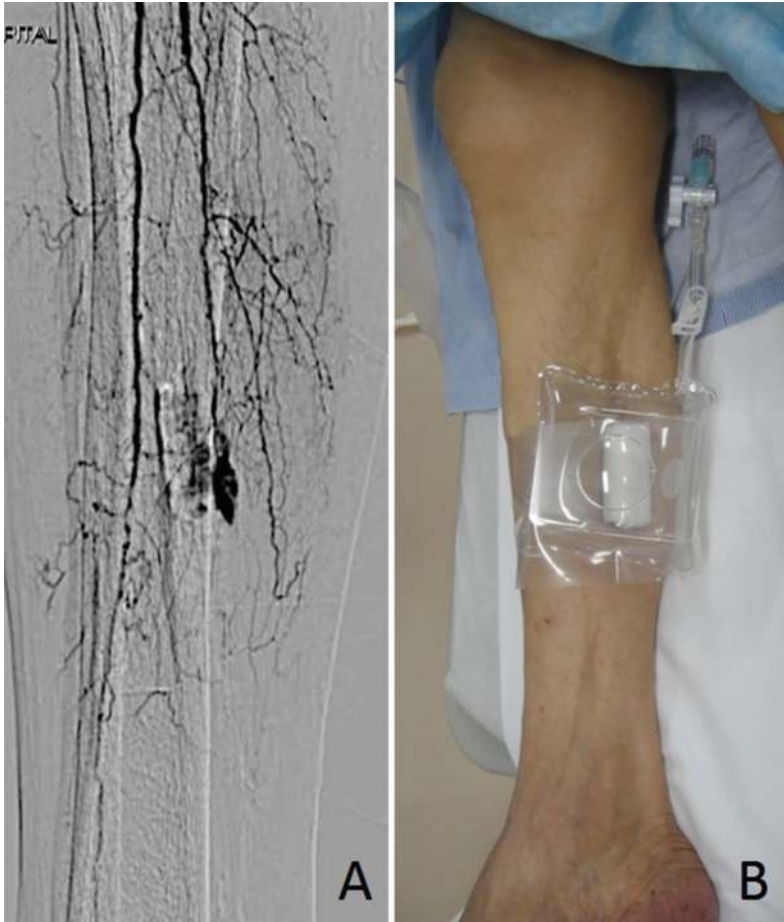

Figure 33. Perforation site is compressed with Tometa-Kun device which allows effective eternal compression.

5. Indigo carmine angiography

There are many issues regarding local perfusion problems of the foot. A non-healing ulcer often caused by macrovascular obstructions in combination with disease at the level of microcirculation in the foot. In addition to macrovascular ischemia, microcirculation,

particularly in a diabetic foot, is often damaged. Endovascular revascularization of the macrovessels is the first-line treatment; however, there are no validated tests to predict the clinical outcome after successful revascularization and often ulcer healing is the hard end point.

5.1. Indigo carmine

In the field of oral surgery, the injection of indigo carmine to tumor-feeding arteries has been used to determine the main feeding artery to the tumor. After confirming the color change of indigo carmine, the super-selective administration of chemotherapy infusions is performed [10]. The application of indigo carmine in patients with CLI has previously been reported, providing visual information regarding foot perfusion at the microcirculation level (**Figure 34**) [11].

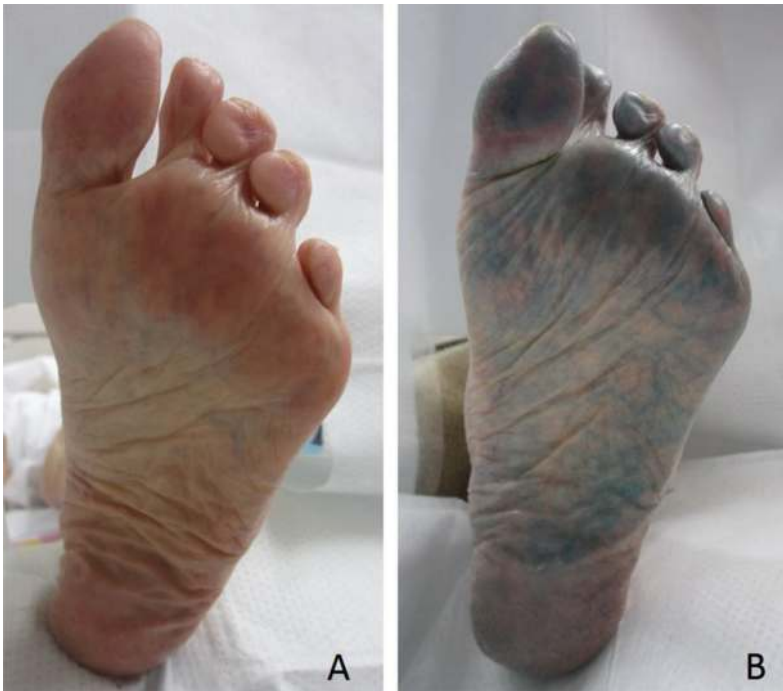

Figure 34. The application of indigo carmine in patients with CLI has been reported, providing visual information regarding foot perfusion at the microcirculation level.

5.2. The angiosome concept

The angiosome concept was introduced by Taylor and Palmer who showed the foot and ankle area to be composed of six distinct angiosomes supplied by the anterior tibial artery, posterior

tibial artery, and peroneal artery [12, 13]. The ATA supplies the dorsal side of the foot and toes while the PTA supplies the plantar side of the foot, toes, interdigital web spaces, and inner side of the heel. The PA supplies the lateral ankle and lateral side of the heel (**Figure 35**) [8].

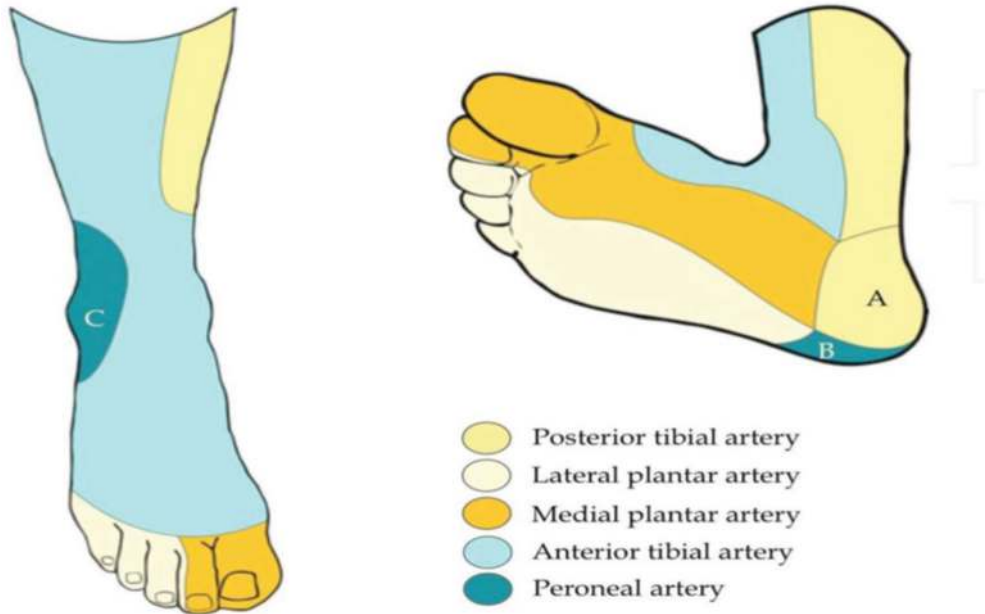


Figure 35. Six distinct angiosomes supplied by the anterior tibial artery (ATA), posterior tibial artery (PTA), and peroneal artery (PA).

However, there are extensive connections between below-the-knee arteries coursing throughout the foot and the inter-angiosome connections by choke vessels could be more important for revascularization in ischemic foot. Whether angiosome-guided EVT is essential for revascularization is not yet well elucidated since there is no objective method to evaluate foot perfusion after successful revascularization.

5.3. Indigo carmine angiography

Indigo carmine angiography to provide visual information is not a difficult process. Generally, 5-ml indigo carmine is injected after endovascular therapy. If the indigo carmine is injected from the distal portion of the below-the-knee artery, indigo carmine angiography shows the territory of the vessel. If indigo carmine is injected from the distal popliteal artery, indigo carmine angiography shows all of the below-the-knee feeding territories (**Figure 36**).

Indigo carmine angiography depicts microcirculation clearly by making the circulated area visible with blue dye. If the ulcerated area remains undyed after the EVT procedure, we can

speculate that sufficient blood flow was not established, informing us of the necessity for further revascularization with either distal bypass or EVT. Indigo carmine angiography is thus a completely new and effective method of evaluating distal microcirculation.

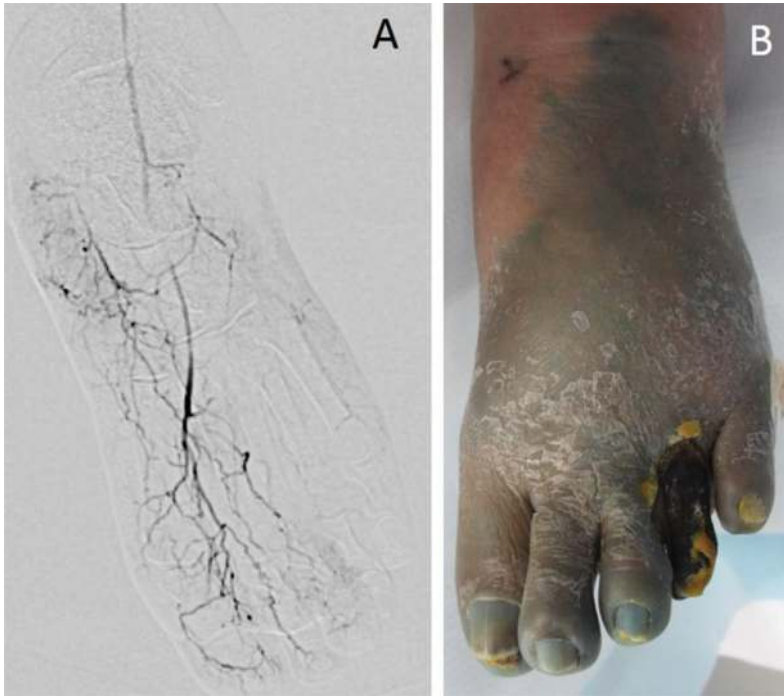

Figure 36. Indigo carmine angiography clearly depicts microcirculation by making the circulated area visible with blue dye.

Author details

Akihiro Higashimori

Address all correspondence to: akihiro.higashimori@gmail.com

Kishiwada Tokushukai Hospital, Osaka, Japan

References

- [1] Garg K, Kaszubski PA, Moridzadeh R, Rockman CB, Adelman MA, Maldonado TS, Veith FJ, Mussa FF. Endovascular-first approach is not associated with worse amputation-free survival in appropriately selected patients with critical limb ischemia. *J Vasc Surg.* 2014;59(2):392–9.

- [2] Marco M, Luis MP, Giacomo C. Revascularization of tibial and foot arteries: below the knee angiography for limb salvage. *Angioplasty, Various Techniques in Treatment of Congenital and Acquired Vascular Stenoses*. ISBN 978-953-0084-3, InTech, 2012.
- [3] Kawarada O, Yokoi Y, Honda Y, Fitzgerald PJ. Awareness of anatomical variations for infrapopliteal intervention. *Catheter Cardiovasc Interv*. 2010;76(6):888–94.
- [4] Yoshiaki Y. Angiography for peripheral vascular intervention. *Angioplasty, Various Techniques in Treatment of Congenital and Acquired Vascular Stenoses*. ISBN 978-953-0084-3, InTech, 2012.
- [5] Sandring S, Ellis H, Healy J, Johnson D, Williams A. Pelvic Girdle and Lower limb. In Sandring S, ed. *Gray's Anatomy: The Anatomical Basic for Clinical Practice*. 39th ed. Edinburgh: Elsevier, Churchill Livingstone, 2005. p. 1600.
- [6] Kawarada O, Fujihara M, Higashimori A, Yokoi Y, Honda Y, Fitzgerald PJ. Predictors of adverse clinical outcomes after successful infrapopliteal intervention. *Catheter Cardiovasc Interv*. 2012;80(5):861–71.
- [7] Godino C, Sharp AS, Carlino M, Colombo A. Crossing CTOs—the tips, tricks, and specialist kit that can mean the difference between success and failure. *Catheter Cardiovasc Interv*. 2009;74(7):1019–46.
- [8] Daniel B, Joana F, Armando M, Antonio GV. Below the knee technique: now and then. *Angioplasty, Various Techniques and Challenges in Treatment of Congenital and Acquired Vascular Stenoses*. ISBN 978-953-0084-3, InTech, 2012.
- [9] Bolia A, Miles KA, Brennan J, Bell PR. Percutaneous transluminal angioplasty of occlusions of the femoral and popliteal arteries by subintimal dissection. *Cardiovasc Intervent Radiol*. 1990;13:357–63.
- [10] Korogi Y, Hirai T, Nishimura R, Hamatake S, Sakamoto Y, Murakami R, Baba Y, Arakawa A, Takahashi M, Uji Y. Superselective intraarterial infusion of cisplatin for squamous cell carcinoma of the mouth: preliminary clinical experience. *AJR Am J Roentgenol*. 1995;165(5):1269–72.
- [11] Higashimori A, Yokoi Y. Use of indigo carmine angiography to qualitatively assess adequate distal perfusion after endovascular revascularization in critical limb ischemia. *J Endovasc Ther*. 2015;22(3):352–5.
- [12] Taylor GI, Palmer JH. The vascular territories (angiosomes) of the body: experimental study and clinical applications. *Br J Plast Surg*. 1987;40(2):113–41.
- [13] Taylor GI, Palmer JH. Angiosome theory. *Br J Plast Surg*. 1992;45(4):327–8.

