
Percutaneous. Recanalization of Chronic Total Occlusion (CTO) Coronary Arteries: Looking Back and Moving Forward

Simona Giubilato, Salvatore Davide Tomasello and Alfredo Ruggero Galassi

Additional information is available at the end of the chapter

<http://dx.doi.org/10.5772/54079>

1. Introduction

Chronic total occlusion (CTO) of coronary arteries is one of the most challenging PCI, usually defined as more than three-month-old obstruction of a native coronary artery. This coronary lesion subset is a frequent finding in patients with coronary artery disease (CAD) as CTOs have been reported in approximately one-third of patients undergoing diagnostic coronary angiography. However only 7-15% of CTOs were treated with percutaneous coronary intervention (PCI) [1] (Figure 1). Perhaps for the fact that procedural success is hampered by the difficulties associated with crossing and/or dilating the occluded segment with guide-wires and recanalization devices and by a high incidence of restenosis and reocclusion.

Despite these obstacles, several studies have documented that successful PCI of CTOs leads to an improvement in anginal status, normalization of functional tests, improvement of left ventricular function and avoidance of coronary artery bypass graft surgery (CABG) [2-6]. Patients with untreated CTOs face a threefold increase in cardiac mortality or complications in case of future acute events [7-9].

Historically, a procedural success rate of 60-70% was achieved using antegrade approach [6]. Nowadays, specifically trained operators are able to improve the rate of CTO recanalization thanks to several new techniques and dedicated device developments. In particular, the retrograde CTO PCI approach, that was first mastered by Japanese operators, has evolved rapidly, resulting in higher success rates, shortened procedural time and reduced exposure to radiation.

It should keep in mind that reopening of a CTO needs to be carefully considered in the presence of symptoms or objective evidence of viability/ischaemia in the territory of the occluded artery.

The aim of this chapter will be to provide a systematic overview of the current state-of-the-art in percutaneous recanalization of CTO, to enhance the understanding of this complex procedure and, consequently, promote safe and effective PCI for patients who present with this lesion subset. Specifically, after a brief introduction about CTO anatomy and definitions, the chapter will be divided into five paragraphs that address the most important clinical and technical aspects of CTO PCI. In the first paragraph the complex clinical CTO decision-making process will be described. This crucial step consists in the evaluation of clinical indication, patient selection and revascularization strategies. In the second paragraph, specific tools for CTO recanalization will be illustrated focusing on improvements in guidewire and dedicate device technology, responsible for improved procedural success in PCI of CTO. A further paragraph will be dedicated to the stent choice for the treatment of CTO. In fact, there is overwhelming evidence in the literature that drug eluting stent (DES) rather than bare metal stent (BMS) reduce significantly the restenosis and reocclusion rates after recanalization of CTOs. The fourth paragraph, will deal with the description of all techniques to cross CTO by anterograde and retrograde techniques. In this paragraph, the attention will be focused on common pitfalls and difficulties and related tips and tricks. Finally, the last paragraph will be focused on the strategies to prevent and treat the possible procedural complications including complications related to vascular access or to procedure such as coronary dissection, perforation or rupture and coronary thrombosis.

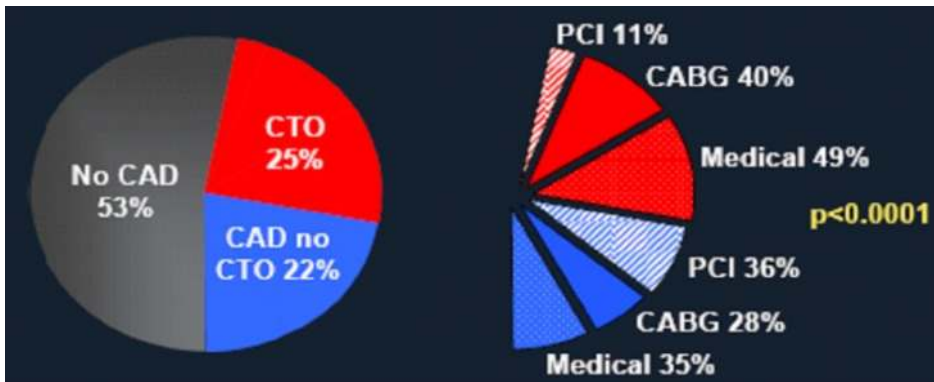


Figure 1. Diagnostic catheterization results stratified by treatment strategy. Adapted from Christofferson et al. [1]

2. CTO anatomy and definitions

A deeper understanding of CTO histopathology might offer insights into the development of new techniques and procedural strategies. The occluded part of the lumen in CTOs consists of two types of tissue: atheromatous plaque and old thrombus (Figure 2). The respective amount of these items are largely dependent on CTO formation which may be grossly classified as the two following phenomena:

1. The late organization and development of an acute occlusion due to a plaque rupture, generally apart from the maximal narrowing area.
2. The progressive occlusion of a long term and high-degree stenosis (with a large amount of plaque and sometimes several layers of additional thrombi).

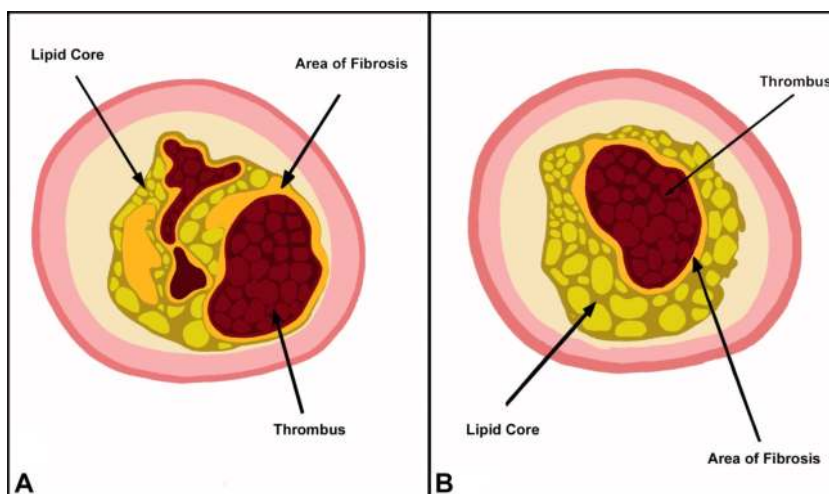


Figure 2. The two mechanisms of CTO formation: A) late evolution of an acute occlusion of an eccentric stenosis B) progressive occlusion of a long standing concentric stenosis.

The histopathology of CTOs was comprehensively described by Srivatsa and coll. in 1997 [10]. These lesions are characterized by a mix of luminal plaque, thrombin, fibrin, inflammatory cells and neovascular channels (Figure 3). The occlusive thrombus is mainly composed of collagen-rich extracellular matrix, intra and extracellular lipids, smooth muscle cells and mixed components, including a small quantity of cholesterol, dense collagen and calcium deposits. The core composition correlates with the CTO age. Older occlusions have higher concentration of fibrocalcific material (defined as “hard plaques”), while CTOs visible for less than one year have more cholesterol clefts and foam cells among less fibrous materials (defined as “soft plaque”). Typically CTOs may be classified as soft, hard or a mixture of both. Hard plaques are more prevalent with an increasing CTO age (> 1 year old) [11].

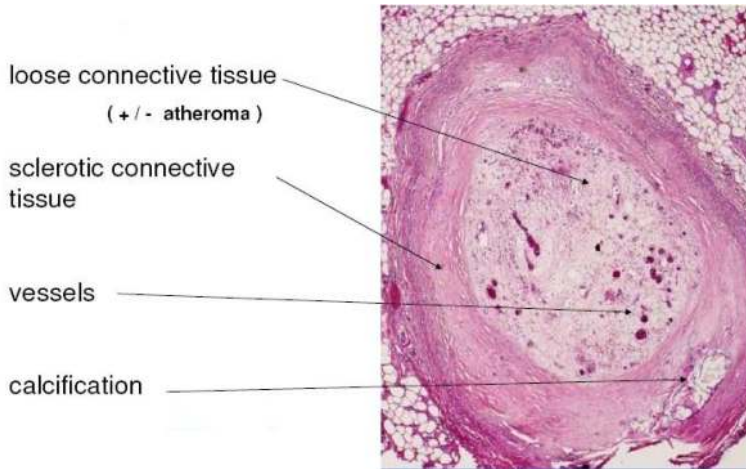


Figure 3. CTO plaque components.

The intraluminal process of plaque and thrombus organization is often followed by the so called “negative remodeling”. This event usually leads to an artery vessel shrinkage, which is mainly observed in CTOs older than 3 months. The negative remodeling process is connected to the replacement of soft plaque tissue with fibrous one, mainly in the middle section of the occlusion [12]. Another important CTO feature is the extensive process of “neovascularization” which increase with occlusion age. In CTOs that are less than one year old the new capillary formation is greater in the adventitia. In CTOs that are more than one year old there is a rich neovasculature network that often traverses the vessel wall (bridging collaterals) [13]. Neovascular process may usually lead to the formation of relatively large capillaries (from 100 to 500 μm) that are defined as “microchannels” (Figure 4). These vessels can frequently be found through the CTO’s body and can partially recanalize the distal lumen [14]. Guidewires may use microchannels as a passage to reach the distal vessel, hence they may have an important therapeutic value. Microchannels might also communicate with vasa vasorum and facilitate an extra-luminal pathways of collaterals o the distal part of the occluded segment, giving the typical aspect of “caput medusae” that is usually a sign of an old and difficult lesion to cross. Moreover, CTOs usually present a higher concentration of fibrous tissue at the proximal and distal parts of the lesion. These areas create a “fibrous cap” which is the hardest part of the plaque that surrounds a softer core of organised thrombus and lipids. Therefore, there are four components of CTO to take into consideration [15]: proximal cap, calcifications, microvessels and distal cap.

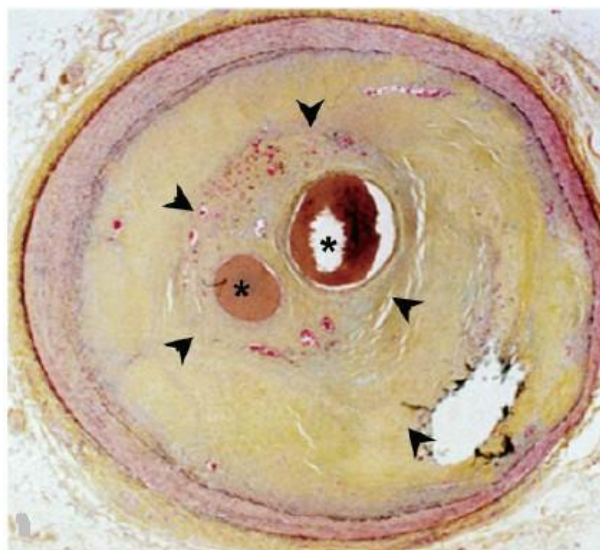

Figure 4. CTO microvessels. This image shows a healed total occlusion (arrowheads) with vascular channels (asterisks) surrounded by a rich collagen matrix (yellow). Adapted from Hoye A [15].

The temporal criterion used to define a CTO has varied widely through the literature, typically ranging from > 2 weeks [16] to > 3 months [17]. Furthermore, any definition of CTO must include different elements such as the degree of lumen narrowing, considering if any antegrade blood flow is present. According to the consensus documents from the EuroCTO Club, lesions can be classified as CTOs, when there is TIMI 0 flow within the occluded segment and angiographic or clinical evidence or high likelihood of an occlusion duration > 3 months [18].

CTOs are characterized by significant atherosclerotic vessel narrowing with a lumen compromise that results in either complete interruption of antegrade blood flow as assessed by coronary TIMI flow (grade 0), also known as “true” total occlusion, or with minimal contrast penetration through the lesion without distal vessel opacification (TIMI grade 1 flow), frequently referred to as “functional” total occlusions. However, the identification of TIMI 0 flow is not as straightforward as in recent post-MI occlusions, for which the TIMI classification was originally developed because antegrade contrast filling of the segment beyond the occlusion does not preclude TIMI 0 flow within the occluded segment. Indeed, particular conditions such as the presence of ipsilateral bridging collaterals may give antegrade flow and the false impression of a functional incomplete occlusion but they are true CTO. Their presence should be differentiated from TIMI 0 flow within the occluded segment by careful assessment in different angiographic planes. Moreover, the presence of intraluminal channels certainly plays a role in crossing the occlusion; antegrade contrast filling of the segment beyond the occlusion flow, in the absence of ipsilateral bridging collaterals and even when the occluded vessel segment

shows no intraluminal contrast filling, indicates a functional and not a true CTO. Only meticulous filming and a vigorous contrast injection with a well engaged catheter allow us to conclude that TIMI flow is 0 within the occluded segment and the lesion should then be classified as a CTO [19]. In absence of serial angiograms, the duration of CTO is difficult to establish with certainty and it might be estimated from available clinical information related to the timing of the event that caused the occlusion: acute MI or sudden change in angina pattern with ECG changes consistent with the location of the occlusion.

Since the time of the occlusion cannot be known, CTOs are usually distinguished into three levels of certainty:

- a. Certain (angiographically confirmed): the minority of cases where a previous angiogram (for instance before a previous CABG operation, or after an acute myocardial infarction) has confirmed the presence of TIMI 0 flow (3 months prior to the planned procedure);
- b. Likely (clinically confirmed): an acute myocardial infarction in the territory of the occluded artery distribution or acute coronary syndrome or deterioration of anginal threshold without other possible culprit arteries ≥ 3 months before the current angiogram;
- c. Possible (undetermined): a CTO with TIMI 0 flow and angiographic anatomy suggestive of long-standing occlusion (collateral development, no contrast staining) with stable unchanged anginal symptoms in the last months or silent ischaemia or, in case of recent acute ischaemic episodes (acute myocardial infarction or unstable angina or worsening effort angina), with the presence of a culprit artery different from the occluded vessel.

3. Decision-making process for patients affected by CTO

The clinical presentation of CTOs can be quite variable ranging from patients with stable angina to patients with silent ischemia or heart failure of ischaemic origin, or those undergoing primary PCI due to acute occlusion in a different culprit vessel, in whom a CTO is discovered as an incidental finding.

Several factors are associated with CTO clinical presentation such as the presence of other concomitant coronary lesions, the amount of CTOs related to myocardial viability, the severity and extension of CTO related to myocardial ischemia and finally the coronary artery involved.

Generally, asymptomatic patients, are more reliable to be left on medical therapy rather than being percutaneously revascularized, especially if these patients have one vessel disease or a previous PCI, which has been performed in another coronary vessel. Moreover, older patients often exert low level of physical activity which might not lead to angina symptoms, underestimating the real burden of myocardium at risk. However, we know that this thera-

peutic strategy might not be clinically appropriate but the decision to treat a CTO in an asymptomatic patient should be driven by a non-invasive functional imaging test, in order to clarify the amount of myocardial viability and severity/extension of myocardial ischemia.

On the other hand symptomatic patients represent the greatest challenge for the clinical decision making, because there are different scenarios which need to be considered:

- a. When the CTO is the only culprit lesion in the coronary tree, and presence of viability/ischemia by non invasive functional test has been shown, PCI is highly recommended especially if likelihood of success has been estimated >60%. Moreover, if PCI is unsuccessful, re-attempt might be performed 2-3 months later after first failure. Conversely, coronary artery bypass graft might be performed to guarantee a complete revascularization, especially in case of a large myocardial ischemia or in case of refractory symptoms. Underestimating the CTO clinical impact in a single vessel disease patient might be led to "catastrophic consequences". Indeed, although the CTO might be supplied by collateral circulation without ischemia at rest, acute donor vessel occlusion might cause a larger myocardial necrosis with a poor prognosis for the patients.
- b. It is not rare to see patients with a CTO angiographically documented few years before and without other coronary vessel diseases, which start to be symptomatic for effort angina only many years after the angiographic documentation is shown. In these cases, symptoms and myocardial ischemia could be related to the disease progression in vessels different from CTO, progression of disease in the donor artery, or to a reduction of blood supply from collateral circulation due to coronary collateral vasospasm [20].
- c. In case of multivessel disease, the presence of a CTO should not be a sufficient reason to deny percutaneous revascularization in the absence of significant left main disease and when the other lesions are suitable for PCI. Indeed, if the decision to perform a PCI is taken, a staged approach should be a reasonable strategy in order to avoid excessively long procedures and the use of large amount of contrast media. In this case consideration of which artery to tackle first, should be based on its importance. When complete revascularization is to be achieved, it is suggested to start PCI at the CTO vessel. As in case of the failure attempt, patient might be fully revascularized by surgery. Inversion of collateral flow direction through the recanalised CTO may protect myocardium at risk during treatment of lesions in the collateral donor vessel. Conversely, in many patients treatment at first of non occluded vessel may improve collateral visualization, significantly contributing to success of CTO recanalization. However, this strategy should be reserved to those patients in whom CTOs are likely to be successfully performed.
- d. Patient might also present two CTO vessels at the same time. In these cases if CTOs angiographic characteristics are favourable and the patient does not present any clinical contraindications such as renal failure or other comorbidities, PCI may be performed on both CTOs during the same procedure, paying careful attention to the amount of contrast mean administered and to the duration of radiations exposure.

CTO decision-making process requires an individualized risk/benefit analysis, considering clinical, angiographic and technical features:

1. clinical: patient's age, symptoms severity, associated co-morbidities (chronic obstructive pulmonary disease, diabetes mellitus, chronic renal insufficiency), left ventricular ejection fraction, associate valve disease and overall functional status.
2. angiographically: the extent and complexity of coronary disease (left main disease, bifurcation lesion, ostial lesion, long lesion, severe calcification), often not recognized before recanalization is performed.
3. technical: to evaluate percentage of success of revascularization preventing complications and considering restenosis rate on the basis of a total stent length required and vessel diameter size.

Regarding clinical features, a great concern is the patients' age. Indeed, in case of octogenarian patients, the operator should not expect any improvement of prognosis, and thus percutaneous attempt of CTO is supposed to be undertaken, only in presence of severe ischemia or refractory symptoms. Another clinical feature to evaluate is the renal function. Parameter used to assess renal impairment is the serum level of creatinine, or the glomerular filtration rate as measured by Cockcroft-Gault formula [21]. However, the risk of contrast induced nephropathy does not relate only to renal impairment before the procedure, but also to left ventricular ejection fraction (LVEF) and the presence of associated comorbidities such as diabetes mellitus and older age. The LVEF assessment is also relevant to consider the opportunity in which the left ventricular assistance device might be used during the procedure, such as intra aortic ballooning pumping (IABP). IABP displaces blood during diastole augmenting diastolic pressure. This augmented pressure wave carries blood flow up to the coronary arteries and can increase coronary blood flow across some coronary narrowing and, in some circumstances, even improving collateral flow to distal CTO coronary vessels. Immediately before systole, the deflation of the counter-pulsation balloon creates a negative space, reversing aortic flow and reducing ventricular after load and, hence, myocardial oxygen demand. Yoshitani, et al. demonstrated that IABP does not increase diastolic pressure distal to severe coronary stenosis, and thus, the major benefit of IABP in such patients with coronary artery disease is the reduction of myocardial oxygen demand [22]. The presence of left main stenosis might not represent a contraindication for CTO PCI. Indeed, the percutaneous treatment for CTO at first, might protect the patient from procedural ischemia during left main PCI, in case of contraindications to surgery. Nevertheless, in these cases it is always recommended to use IABP if Euroscore is ≥ 6 [23].

In patients underwent previous surgical revascularization, CTO treatment is a dilemma and the choice between performing native vessel and graft recanalization is not always easy, especially in case of old degenerated graft. Furthermore, even when the graft is not occluded but severely diseased at the level of the anastomosis PCI of the graft might be overtaken by recanalization of the native vessel if the occlusion is easy to approach. Moreover, it has been shown that myocardial ischemia might also occur in presence of a patent graft due to endothelial dysfunction [24]. Indeed, despite the presence of a patent and non-occlusive graft, regional myocardial blood perfusion might be still compromised, leading to ischemia.

A consensus document from EuroCTO Club [18] underlines that "PCI CTO should be attempted after careful review of clinical history, results of provocative tests, coronary anatomo-

my and personal experience” and “with average recanalization success rate of >70% in experienced hands with contemporary techniques the presence of a CTO should not be sufficient reason to switch from PCI to surgery in multivessel disease”.

3.1. Non invasive detection of myocardial viability

The non invasive assessment of myocardial viability has proved clinically useful for distinguishing hibernating myocardium from irreversibly injured myocardium in patients with chronic ischemic heart disease who exhibit marked regional and global left ventricular dysfunction [25]. The accurate noninvasive determination of myocardial viability is critically important for clinical decision making [26]. It makes allowance for the selection of patients with CAD and resting left ventricular dysfunction who benefit from revascularization strategies. Patients with substantial zones of viability and asynergic myocardium should demonstrate better function and overall better outcomes after revascularization compare with patients affected by a ventricular dysfunction related to large myocardial scar.

Thallium-201 is the imaging agent most frequently used with single photon emission tomography (SPECT) imaging for determination of myocardial viability. The reason is that the delayed uptake of thallium-201 on rest-redistribution imaging is related to myocardial cellular integrity. Several groups have shown that approximately 70% of segments showing >50% or >60% thallium-201 uptake on 3- to 4 hour rest thallium-201 redistribution scintigrams will demonstrate improved systolic function after revascularization [27-28]. The greater the number of viable segments detected preoperatively, the greater the improvement in LVEF post-operatively.

Although, 99mTc-labeled perfusion agents, such as sestamibi and tetrofosmin, do not show any significant redistribution over time after being injected intravenously, several studies have shown comparable accuracy for viability detection between these agents and thallium-201 [29-30]. This is thought to be due to high extraction of these tracers in the region of low flow in which myocytes are viable. These agents bind to the mitochondrial membrane and require an intact mitochondrial membrane potential for intracellular binding.

Positron emission tomography (PET) is considered to be the standard of reference for noninvasive detection of viability with nuclear cardiology techniques. A myocardial zone of asynergy is determined to have preserved viability when there is a “mismatch” between perfusion and 18F-fluorodeoxyglucose (FDG) uptake. Patients with a “mismatch” pattern (low blood flow perfusion/high metabolic uptake) will often show improved regional and global left ventricular function after revascularization, whereas patients with a concordant reduction in perfusion and FDG uptake, referred to as a “match” pattern, have predominantly scar and do not show any significant improvement in regional and global function after revascularization [31].

Allman et al performed a pooled analysis [32] consisted of 3088 patients in 24 studies reporting viability by use of radionuclide imaging, PET or dobutamine echocardiography, and long-term survival after revascularization or medical therapy. In patients with predominant viability, follow-up on medical therapy was associated with very high risk, as demonstrated

by a 16% annual mortality rate. In similar patients, revascularization was associated with an 80% reduction in annual mortality rate [16% vs 3.2%, $p < 0.0001$], as compared with medical therapy. Patients with the most severe LV dysfunction derived the greatest benefit from revascularization, that is the survival benefit associated with revascularization of patients with viable myocardium increased proportionately with worsening LVEF. The data suggested that the presence of viable myocardium as defined by noninvasive imaging in patients with heart failure, is a marker for very high natural history risk, and that risk appears to be significantly reduced by revascularization.

3.2. Impact of complete percutaneous revascularization

Complete myocardial revascularization remains a desirable goal to obtain with PTCA or CABG [33]. However, incomplete revascularization with PCI of the culprit vessel may be the suitable strategy in selected patients [34]. This may occur, when the vessel, responsible of ischemia, can be identified, particularly when this vessel is a favourable lesion that serves a large non-infarct territory, in case of an acute coronary syndrome, left ventricular dysfunction due to acute severe ischemia or pre-existing renal failure. Indeed, situations which involve complex anatomy such as CTOs may be more cumbersome to approach and a proper planning procedure rather than an hoc angioplasty may be also indicated in such patients. Hannan et al showed that incomplete revascularization with stenting is associated with an adverse impact on long-term mortality [35]. Even more important, this author showed that incompletely revascularized patients with total occlusions, particularly those with no other incompletely revascularized vessels experienced lower rates of subsequent PCI than other patients. Although, at first, it seems to be good news for these incompletely revascularized patients, the fact that they had higher long-term mortality than completely revascularized patients suggests that they might have benefited from more subsequent revascularization. Indeed, with the percutaneous approach the presence of a CTO remains the biggest and most important technical challenge to achieve complete revascularization. Furthermore, as the procedure of a CTO recanalization still remains time consuming, exposing the patient to high dose of ionizing radiation and contrast media, any percutaneous treatment in these subset of patients must be justified on the basis of a strict clinical indication, to improve patients' symptoms and prognosis survival [6]. Taking all that into consideration, stress myocardial perfusion imaging is an effective means of identifying ischemic and viable myocardium and its vascular distribution in patients undergoing coronary revascularization [36-38]. Nuclear data have suggested that adverse events after incomplete revascularization occur more frequently in patients with perfusion defects [39-41], and that myocardial scintigraphy is able to provide incremental prognostic information after adjusting for clinical, angiographic and exercise variables [42]. Recently, we have shown that in patients with a CTO in a main coronary artery left untreated, patients with either a severe perfusion defect or ischemia and necrosis at stress myocardial scintigraphy have the worst prognosis in terms of hard events at 9 years follow-up as compared to patients with normal or near normal myocardial scan or only either necrosis or ischemia [43]. In these patients the presence of another vessel incompletely revascularized beyond that of the CTO artery, did not seem to change the prognosis at follow-up as shown by the occurrence of hard events in those pa-

tients with severely abnormal scans. Moreover, this study provides sufficient evidence that the absence or presence and type of collaterals do not influence prognosis but rather being equally distributed in all subsets of patients. It is also interesting to note that normal scans were rare among the CTO patients accounting for only 6% of all scans; indeed, despite the presence of well developed collaterals (either by Rentrop or Werner classifications) abnormal scans were shown in the majority of patients. As shown by Werner and colleagues even in patients with normal regional LV function, collaterals provide a normal coronary flow reserve in less than 10% [44]. This study highlights how CTO patients need to be assessed appropriately by means of functional imaging testing before considering medical therapy instead of revascularization. Conversely, a functional nuclear stress imaging study would enable a tailored strategy of complete revascularization in those patients with multivessel disease and incomplete revascularization in which complete revascularization by PCI may be contraindicated, or difficult to achieve.

Although the concept of hibernating myocardium suggests that it is an adaptive steady state, potentially reversible with revascularization, several reports have suggested that progressive structural and clinical deterioration may occur in this pathophysiologic setting, with more advanced structural changes being associated with less favourable improvement after revascularization [45]. Indeed, patients with more advanced abnormalities had less improvement in regional and global function after revascularization suggesting that hibernation is an incomplete adaptation to ischemia and that once identified, prompt revascularization should occur. Consistent with this concept are data from Beanlans et al [46] who reported that after identification of patients with ischemic cardiomyopathy who had significantly viable myocardium by PET imaging, a substantial delay in revascularization was associated with death during that delay and absence of post-revascularization LV functional improvement, as compared with patients undergoing more prompt revascularization. These important studies have significant practical implications, suggesting that identification of patients with substantial ischemia and viability are not only at long-term risk, but risk in the short term as well, and that optimal reversibility of LV dysfunction and improvement in symptoms and outcome are dependent on prompt referral for revascularization. These important data might support the concept that viability information can assist in the selection of patients with CTO and regional left ventricular dysfunction for whom the most optimal potential outcome will come from PCI rather than medical treatment or surgical revascularization if not needed.

Cardiac Magnetic Resonance Imaging (cMRI) has enormous potential thanks to its major attributes of high image quality and resolution combined with non-ionising radiation. It can provide high quality diagnostic information about cardiac and valvular function, coronary anatomy, coronary flow reserve, myocardial perfusion, myocardial viability, contractile reserve and cardiac metabolism. It allows assessment of even subtotal wall motion disturbances resulting from the consistently high endocardial border definition, and the measurement of myocardial perfusion can be integrated into the same examination, with the high spatial resolution of the scans facilitating the determination of the transmural extent of a regional perfusion deficit.

Recently the technique of late enhancement with gadolinium contrast agent has been described, in which imaging of the heart is performed 15 minutes after an intravenous injection of gadolinium. The gadolinium concentrates in the necrotic (acute infarction) or scar tissue (chronic infarction) because of an increased partition coefficient and the infarcted area becomes bright [47]. There is very close correlation between the volume of signal enhancement and infarct size in animal experiments of acute infarction. The technique has high resolution, and can define the transmural extent of necrosis and scar for the first time *in vivo*. Although the technique has been recently developed, it has obvious applications in defining whether infarction has actually occurred in borderline cases. The technique of late enhancement has also clinical application to the assessment of viability and it is an excellent technique for the detection and quantification of myocardial infarction as reported by many studies [48-49]. First pass perfusion is the most widely used cMRI-technique for the detection of reduced myocardial blood flow and yields superior results compared to SPECT [50].

The different noninvasive modalities available to assess myocardial viability interrogate distinct pathophysiologic myocyte and myocardial processes. The SPECT radionuclide tracers examine myocyte cell membrane integrity, and dobutamine echocardiography assesses regional ventricular contractile reserve. PET images myocardial blood flow and metabolism, whereas magnetic resonance hyperenhancement imaging identifies scarred myocardium. Although no major differences have been identified among the modalities that would suggest differences in patient management, in a pooled analysis of studies reporting on rates of regional functional recovery, few years ago Bax et al. [38] reported that the radionuclide agents are more sensitive and that dobutamine echocardiography was more specific, with PET having slightly higher overall accuracy for predicting functional recovery [51].

However, in the presence of a CTO and a very low blood flow state due to the occluded artery, which is supplied only by small collateral channels, dysfunctional but viable LV segments may show a modest inotropic response to dobutamine because of the early occurrence of ischemia [52]. Indeed, asynergic but viable myocardium usually thickens under catecholamine stimulation [53]. However, this effect may be limited or even abolished in the presence of a very flow-limiting CTO, underestimating the amount of myocardial viability in these subsets of patients [54].

More recently contrast-enhanced MRI has shown to be comparable with a PET/SPECT imaging protocol for the prediction of regional and global functional improvement after revascularization [55]. However, in the presence of discrepant findings between the modalities, cMRI is superior to PET/SPECT for predicting lack of recovery of segmental myocardial function after revascularization. One of the reason for this finding may be explained by differences in the way the two techniques assess myocardial viability [56]. Indeed, a relatively small volume of dysfunctional viable tissue may show increased ¹⁸F-FDG PET uptake, with PET indicating viability, whereas the coexistence amount of scar impedes functional recovery. Although some individual studies may suggest better prediction about functional recovery by one test type over another, such data generally reflect differences in small regions or segments per patient and do not seem to affect long-term outcomes.

4. Tools for CTO recanalization

There are four important features of CTO wires:

1. **Polymer covers:** these are plastic sleeves of flexible but solid material which are applied directly over the core or over spring coils covering the tip of the wire. Based on the presence or absence of a polymer, CTO wires are divided in two main categories: polymer jacket wires (by default also hydrophilic coated) and spring coil wires (some hydrophilic coated and some not).
2. **Wire coatings:** these affect lubricity and tracking and facilitate smooth movement. There are two types: hydrophilic and hydrophobic. Hydrophilic coatings attract water and are applied over polymer and stainless steel, including tip coils. They are thin and non-slippery when dry and become gelatinous when wet, reducing friction. They usually cover the distal 30-35 cm of the wire. Hydrophobic coatings (Dow Corning Silicone) repel water. No wire flushing is required and they also reduce friction but not to the same extent as hydrophilic wires. These coatings usually cover the working area of wire, excluding the tip. There is an inverse relationship between lubricity and tactile feedback related to the presence or absence of coatings over coils and polymers at wire tips.
3. **Core materials and tapering:** the majority of CTO wires have a stainless steel core. Modern CTO wires have a transitionless parabolic core grind which provides excellent torque response and no prolapse points compared to conventional step tapering of non-CTO wires.
4. **Tip stiffness:** this ranges from 0.5 to 20 grams. Usually plastic jacket wires are in the low range of stiffness and spring coil wires cover the whole range. Tip tapering strongly affects penetration power as the force is applied over a smaller cross-sectional area in tapered wires.

4.1. Micro-catheters and over the wire balloons

Wires should be used with an over the wire (OTW) balloon or micro-catheter in order to ease torque in the tip response, preventing flexion, kinking, prolapse of the guide wire, and improving penetration ability. They also allow one to modify and reshape the guide wire curve, and exchange one guide wire for another. Micro-catheters in comparison with OTW balloons may provide a better tip flexibility, improving wire manipulation due to their larger inner lumen and hydrophilic coating which reduces friction. They also have the advantage of a radiopaque marker at the "real catheter tip" which has a flat end. Both of these characteristics help to avoid advancing too far into the lesion, a mistake that occurs frequently with OTW balloons. Additionally, most of the micro-catheters are braided which prevents shaft kinking, especially when crossing very tortuous vessels, a characteristic that OTW balloons lack. On the other hand microcatheters are more expensive and do not offer dilating capacity. The choice between an OTW balloon catheter and a dedicated micro-catheter depends on the features and CTO complexity and on the operator's personal experience. Micro-catheters differ from each other re-

garding construction characteristics, as well as flexibility, pushability, and trackability properties. One of the micro-catheters most generally used is the Finecross which is braided, hydrophilic coated and has a tapered body. It is available in 130cm and 150cm lengths, for the antegrade and retrograde approaches respectively.

The Tornus (Asahi Intecc Co., Nagoya, Japan) crossing micro-catheter has been developed to penetrate severe and hard lesions with greater flexibility and torquability with a rotational burrowing advancement manually manoeuvred by controlled counter-clockwise rotation.

The Corsair (Asahi Intecc Co., Nagoya, Japan) is a septal dilator catheter used for the retrograde approach. This is a micro-catheter which is dedicated for selective engagement of the collateral channel. It consists of a tapered tip and screw head structure, which reinforces torque transmission for the guide wire and creates better back-up support for CTO penetration. The Corsair provides superior tip flexibility which enables smooth approaches to narrow tortuous vessels, such as septal channels. Unlike other general micro-catheters, the Corsair possesses a soft tip with tungsten powder mix and a 0.8 mm platinum marker coil 5 mm from the tip, which makes it easy to identify the distal tip under fluoroscopy.

The Venture™ Catheter (Velocimed, Minneapolis, Minnesota, USA) is an over the wire, low profile support catheter, 6F compatible, flexible, torqueable with a radiopaque atraumatic tip. It has been recently designed to help direct the wire where there are difficult angles, providing strong support especially in occlusive lesions. It is also available as a rapid exchange device.

The Twin pass (Vascular Solutions, Inc Minneapolis, Minnesota, USA) is a dual access lumen rapid exchange micro-catheter (rapid exchange and over the wire) which helps the guide wire placement and exchange after reopening the occlusion and gaining access to different main branches.

The Crusade (Kaneka Corporation, Japan) micro-catheter has the similar design and application of the Twin pass.

4.2. Dedicated devices in clinical use

Many dedicated devices to open CTOs were developed in the past, but most disappeared because they did not prove superior to conventional CTO procedure equipment. The following dedicated devices are currently in clinical use:

Crosser. The Crosser CTO recanalization system (Flow-Cardia Inc, CA, USA) is comprised of a generator, transducer, foot switch, and a disposable catheter. Through the generator the catheter tip vibrates at a rate of 21,000 cycles/sec. This vibration provides mechanical impact and cavitation effects, which aid in the recanalization of the occluded artery. The catheter is monorail, hydrophilic, and can be advanced over a standard 0.014 inch guide wire. It is 1.1 mm in diameter, which makes it compatible with 6 Fr guiding catheters, and has a blunt tip. In a small single centre experience comprising 28 patients (30 lesions) technical success was obtained in 63% of the occlusions with minor complications [57]. In a single center registry of 45 patients with relative complex CTOs success rate was 84% but the use of the de-

vice was associated with lower time of procedure, time of fluoroscopy, and contrast load administration as compared with conventional techniques [58]. In the prospective multicenter CRAFT registry that enrolled 80 patients where the device was used as a first treatment choice success rate was 76% [59].

BridgePoint system. The BridgePoint technologies consists of three devices that can be used alone, or in concert with other wires/devices for rapid and safe CTO crossing and provisional luminal re-entry. The Crossboss catheter is an OTW stainless steel catheter with a rounded tip that can negotiate CTOs by using rapid bi-directional rotation. If the Crossboss, or conventional wires and devices, gain subintimal/subadventitial position, the flat Stingray balloon (with an exit port oriented toward the lumen) and Stingray guide wire can be utilized for dedicated lumen re-entry and distal vessel access. The FAST-CTOs pivotal trial enrolled 147 patients with wire-refractory CTOs. Technical success was 77%, 30 day MACE < 5%, and average procedure time was 105 minutes [60]. Recently, the preliminary European experience (42 patients) with this system was reported and the success rate was 67% without any safety issues [61].

5. The key of success of CTO PCI

The selection of the access route is dependent on the individual patient situation (e.g., severe peripheral vascular disease, which may mandate a radial approach) as well as on the operator's preference. Guiding catheter size is limited from the radial approach, but the radial artery can be easily used for contralateral injection (5 or 6 Fr diagnostic catheters). Most experts use the femoral approach (90% in Europe) and it has not been shown that either access is preferable except for about 10% of the cases in which even experienced radial operators select the femoral route.

Good passive support with coaxial alignment into the coronary artery for active support is crucial. Passive support is stronger with larger guiding catheters (7 and 8 Fr) while 6 Fr catheters offer the best balance between active and passive support. For the left coronary system extra backup-type catheters (Voda left, extra backup, geometric left, left support) are preferable, although some operators still prefer Amplatz type or even Judkins type catheters, the latter needing more manipulation to achieve optimal position and back up in complex cases (Figure 5). For the right coronary artery 6F and 7F catheters can be used with left Amplatz 0.75-2 shapes, hockey stick shapes for gentle superior origins of the RCA, Judkins shape for slightly inferior origins and internal mammary artery type guiding catheters for upward origins (Figure 6). One word of caution is that there is a higher risk of vessel injury at the ostium and first bend of the right coronary artery especially with an Amplatz left that has a tendency to jump into the artery, and with all kinds of 8 Fr catheters. In case of ostial dissection, a soft-tipped wire must be selected and steered carefully past the dissection that needs to be fixed before continuing the procedure. Often the guide catheter has to be changed to avoid an orientation towards the dissection.

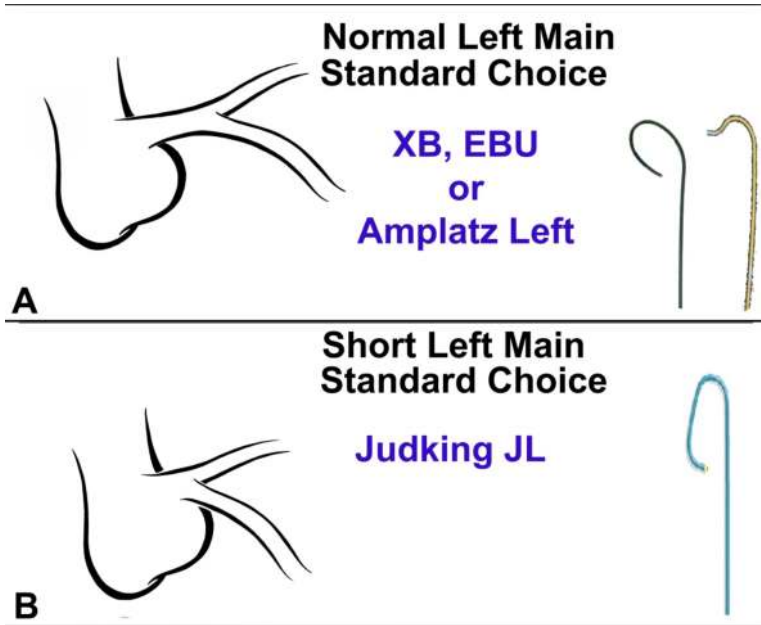


Figure 5. Guiding catheter selection for left coronary artery; A) normal left main; B) short left main.

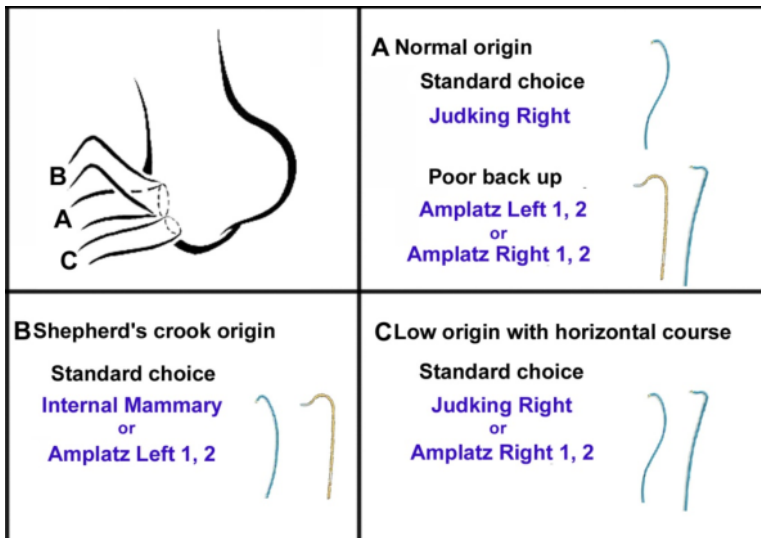


Figure 6. Guiding catheter selection for right coronary artery; A) normal origin; B) Shepherd's crook origin; C) low origin with horizontal course.

When the distal vessel is mainly filled by retrograde collaterals, or there are bridging collaterals originating near the occlusion that are likely to have their flow impaired after wire-catheter advancement, contralateral injection is necessary from the beginning of the procedure. The contralateral approach can also be achieved by puncturing the same groin with a 4 to 6 Fr catheter, which may allow the procedure to be better tolerated. The operators of the EuroCTO Club have used contralateral injection in 62% of cases of their personal series (range 33-78%) [62].

A floppy wire is often the best initial choice to negotiate the segment proximal to the occlusion and advance an OTW balloon or microcatheter up to the proximal stump and then exchange it to a stiffer dedicated wire.

Until recently, the standard way of selecting a guide wire was to use a gradual step-up approach, which consists of tackling the lesion with a medium-tipped guide wire (3-6 gr) and then exchanging it for a stiffer one (9-12 gr). Using this approach, a reasonable choice is to start with a Medium or a Miracle 3 first (Asahi Intecc Co., Nagoya, Japan), then switching to stiffer wires.

The introduction of very soft tapered polymeric wires such as the Fielder XT dramatically changed this practice. Soft tapered polymeric wires became the standard to start CTO procedures; in about 40% of the cases this wire will cross the occlusion taking advantage of invisible tiny channels [62]. The current trend is a sharp step up to very stiff tapered spring coil tapered hydrophilic wires such as Confianza pro 12 gr and PROGRESS 200T to overcome any hard calcified or fibrotic segments of the occlusion and quickly return to soft polymer/hydrophilic wires to continue long segment tracking and complete crossing of the CTO. This strategy significantly reduces procedural time and material consumption. With contemporary CTO techniques soft polymer wires are of increasing use followed by spring coil stiff but hydrophilic wires while bare spring coil wires became of secondary importance.

The shaping of a CTO guide wire tip is very important. Usually, a small 40-50° curve, 1.0-2.0 mm from the tip of the wire is needed to penetrate the proximal fibrous cap. In hard spring coil wires a gentler secondary 15-20° curve, 3.0-4.0 mm proximal to the distal tip is necessary to navigate into the CTO body, to orient the tip and to cross the distal fibrous cap especially in vessels bigger than 3.5 mm.

5.1. Single wire techniques

There are three fundamental elements of wire handling: rotating, pushing and pulling. After entering the proximal cap, one should very gently push while simultaneously keep applying torque, until the wire slides into the body of the occlusion. The wire should be rotated clockwise and counter clockwise, but not more than 360° in the same direction, in order to keep good tip control. Uncontrolled wire spinning may result in large dissections that might make difficult to find the distal true lumen or lead to complications such as wire exit and perforation or wire entrapment.

If resistance is strong, pushing (advancement of the OTW catheter close to the tip of the wire to increase stiffness and pushability) may open a false lumen and should be avoided. Apply-

ing rotation in combination with appropriate wire selection is the right choice as it will minimize resistance at the tip.

Wires, especially stiff ones, have the tendency to follow the outer part of the vessel curve which in tortuous occlusions can easily lead to vessel exit and perforation. It is important to direct the wire tip towards the inner part of vessel bends. Calcification or occluded stents are often good markers of the vessel course. Bridging collaterals should be carefully recognised and avoided as modern wires, especially polymer ones, can easily track these vessels and lead to major complications if perforated or dilated.

5.2. Parallel-wire technique

The parallel-wire technique was first described by Reifart in 1995 and was further developed by Katoh [63]. It is a cornerstone technique in CTO PCI that every operator should be familiar with. When the first wire enter the false lumen, it is left in place, and a second wire (typically stiffer and often tapered with different tip bend) supported by an OTW catheter, is passed parallel to the first wire aiming for the distal true lumen. The initial wire serves as a marker, occludes the wrong pathway and can potentially modify the anatomy by changing vessel geometry and smoothing sharp curves.

If the second wire also fails to enter the distal true lumen and follows a different incorrect pathway, often on the opposite wall, the first wire is withdrawn and steered in the direction of the true lumen using the second wire as a marker; the so-called “see saw” technique. Occasionally, three or more wires are used. As in single wire techniques it is of paramount importance not to over-rotate and push either of the wires, in order to avoid creation of large dissection and subintimal spaces as well as to avoid wire twisting. Often re-puncturing the proximal cup or navigating through the occlusion with a difference of fraction of a millimetre is critical for success.

5.3. Techniques with sub-intimal tracking

The STAR technique (sub-intimal tracking and re-entry) was introduced by Colombo [64] who demonstrated that the technique was feasible and safe. This method involves fashioning a large “umbrella-handle” shaped bend at the tip of a hydrophilic wire once the wire is within the dissection flap. Force is then applied to this tip and evenly distributed over a large surface area, along the length of the umbrella-handle, to break through the sub-endothelial layer thereby creating a communication between the false lumen and the true lumen. Carlino [65] introduced the modified STAR technique (guided-STAR technique), by injecting contrast into the subintimal space in an effort to simplify the original technique and make it more widely applicable. Once in a dissection plane pure contrast is gently injected from via an OTW balloon or a micro-catheter drawing a roadmap of the occluded segment. The injection might cause a coronary dissection whether tubular (a linear morphology consistent with the vessel outline) or storm cloud (small side branch or bridging collaterals dissection with diffuse contrast extravasation into the adventitia). Sometimes a communication between the false and true lumen can be created.

More recently, Carlino [66] proposed the “Microchannel technique”. The idea came from histological CTO data demonstrating that most occlusions have intra-luminal micro-channels with size between 100-500 μm that run within and parallel to the occluded vessel [67-68]. According to this technique after central puncture of the proximal cap with a very stiff spring coil wire for a length no longer than 1-2 mm and advancement of a OTW balloon or a micro-catheter, contrast is injected aiming to enlarge and connect these micro-channels creating a communication between the proximal and distal true lumens favoring guide wire crossing through the occlusion. This technique is mostly proposed for straight CTO segments with a concave proximal cap that will facilitate central puncture.

Galassi further refined the STAR proposing the “Mini-STAR” technique using the very soft Fielder polymeric guide wires. The Fielder FC and XT (tapered) can track intra-occlusion channels navigating through the occlusion. In cases of channel interruption or presence of harder tissue by forcing the wire when supported by a micro-catheter a J-tip shape is automatically created within the occlusion. This J tip is smaller compared to the one purposely created with stiffer polymeric guide wires during the STAR technique allowing “mini subintimal tracking” with the creation of much smaller subintimal spaces. This technique was successful as a rescue in 97.6% of cases during the same procedure after failure to recanalise with conventional techniques, and during a second attempt in 84.6% of the cases [69].

5.4. Retrograde approach

The retrograde techniques have a long standing history. In the late 80s Hartzler introduced the retrograde dilatation of native artery stenosis proximal to a distal SVG anastomosis. In the early 90s retrograde wire crossing of CTOs via saphenous vein graft (SVG) grafts were attempted. In late 90s the invention of the bilateral approach led to the marker wire technique where the retrograde wire was used as a roadmap for the antegrade wire. In the early 2000s initial attempts to break the distal cap with balloons were attempted and in 2005 Katoh pioneered the field introducing the Controlled Antegrade and Retrograde subintimal Tracking (CART) technique [70] establishing the modern era of retrograde CTO recanalisation. Beyond the concept of retrograde dilatation within the occlusion to facilitate antegrade wire crossing, the novelties introduced in this procedure was the retrograde balloon dilatation. Indeed, the principle of this technique is retrograde penetration and dilatation of the occlusion, most often close to the distal cap, thus creating a large target (subintimal space) facilitating antegrade wire crossing. In the reverse CART, the principle is the same as the CART technique with the difference that the subintimal space is created with antegrade balloon dilatations facilitating the crossing of the occlusion with the retrograde wire. Currently, this is the dominant technique in the retrograde CTO approach [71]. IVUS guidance for the connection of the antegrade and retrograde subintimal spaces [72], led by Japanese operators, significantly contributed to our understanding of these techniques, but did not receive widespread adoption due to its inherent complexity and cost. More recently, a variety of modifications to these cornerstone techniques have been introduced such as subintimal space stabilization with stents (stent CART technique after septal overdilatation and retrograde stenting and

the stent reverse-CART technique) introduced by Sianos [73]. The retrograde wire crossing technique (crossing of the occlusion purely retrograde without the need for creation of subintimal spaces), which accounts for almost 30% of successes, as well as the marker wire technique should also be kept in mind as simpler retrograde techniques which can always prove helpful [74].

6. The stent choice for CTO treatment

Several randomized studies have compared balloon angioplasty with stent implantation for the treatment of CTOs (Figure 7). Although these trials have shown diverse results regarding entry criteria, antithrombotic regimen and trial design, their findings are remarkably concordant. The restenosis rate was reduced from 70% in the balloon treated groups to 30% in the stent groups, with a corresponding reduction in the need for revascularization and with no increased risk of stent thrombosis. Also the rate of reocclusion was significantly reduced by stent implantation. The introduction of DES has determined a significant reduction in restenosis and re-occlusion as compared to BMS.

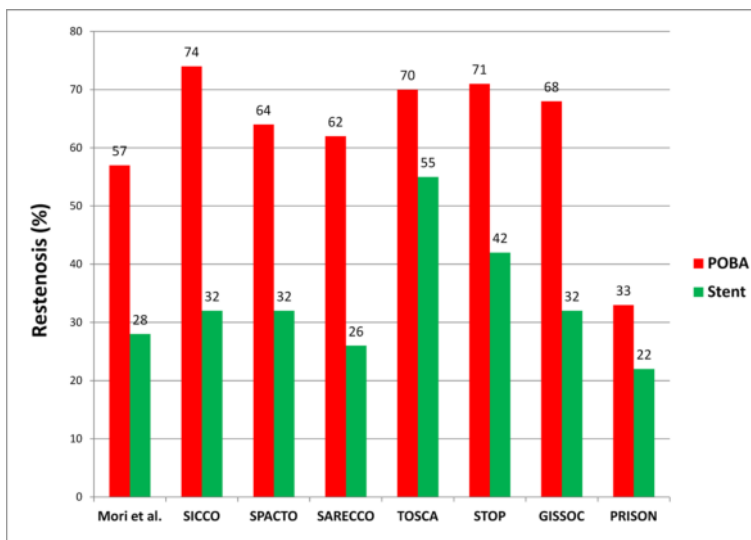


Figure 7. Restenosis after percutaneous recanalization of CTO: an overview of POBA versus stent implantation randomized trial

It is advisable to use DES with a very low late lumen loss are in CTOs, as these lesions have a large plaque load and the compression of these plaques within the adventitial space promotes intimal proliferation and therefore high restenosis and re-occlusion rates as previously demonstrated with BMS [75-81].

6.1. Paclitaxel-eluting stents (PES) for CTOs

Werner et al. [82] evaluated the efficacy of PES in 48 consecutive patients with CTOs compared with a matched group of 48 patients previously treated with BMS. Patients matching was performed on the basis of a history of diabetes mellitus, prior MI, diameter and number of stents implanted, lesion location and left ventricular function. The PES-treated group had significantly fewer adverse events relating to the reduced need for repeat revascularization; the advantage of PES over BMS was also significant both in diabetic and non-diabetic patients. Angiographic follow-up demonstrated the efficacy of the PES with a significantly smaller late lumen loss in the PES-treated group and significantly less restenosis (8% vs 51%) and reocclusion (2% vs 23%).

Two additional registries studied the role of PES in CTOs: among 65 patients with CTOs in the international WISDOM Registry, treatment with the PES resulted in freedom from MACE and repeat intervention at 1 year in 93.3% and 98.3% of patients [83], respectively; in the European TRUE Registry, among 183 with CTO treated with PES, 7-months rates of restenosis and target vessel revascularization were 17.0% and 16.9% respectively [84].

6.2. Sirolimus eluting stents (SES) for CTOs - Registries

Several observational studies examining clinical outcomes among patients treated with DES following successful CTO recanalization demonstrated the notion that unlike BMS, DES may achieve similar reductions in the need for repeat target vessel revascularization (TVR), as observed in non occlusive lesions.

The first data on the effectiveness of SES usage for CTOs came from the Rapamycin Eluting Stent Evaluated At Rotterdam Cardiology Hospital (RESEARCH) registry, a prospective single centre study set-up with the aim of evaluating the safety and efficacy of SES in a “real world” scenario [85]. In this registry SES was the device of first choice for every PCI performed at the Thoraxcenter irrespective of patient or lesion characteristics. Among 56 patients treated with SES following successful CTO revascularization during the first months, the 1-year survival free of major adverse cardiac events (MACE) defined as the composite of death, acute myocardial infarction or TVR was 96.4% compared with 82.1% among an historical control group of 28 patients receiving bare metal stents ($p < 0.05$). Six-month follow up angiography performed in 33 patients treated with SES showed a remarkable suppression of neointimal proliferation, with in-stent late loss of 0.13 ± 0.46 , a binary restenosis rate of 9% and a single reocclusion (3%).

More recently, the RESEARCH investigators have reported the 3-year clinical and angiographic follow-up of patients with CTO in a consecutive series of 147 patients [86], with comparison between BMS ($n = 71$) and SES ($n = 76$). The cumulative event-free survival of MACE was 81.7% in BMS group and 84.2% in SES group ($p = 0.7$). The authors concluded that, despite clinical benefit after 1 year, the use of SES was no longer associated with significantly lower rates of TVR and MACE in patients with CTOs after 3 years of follow-up compared with BMS. The issue of long term outcome after successful CTO revascularization and DES implantation will surely continue to deserve attention in the future.

Ge et al. provided other insights into the angiographic and clinical impact of implantation of SES in the re-opened CTOs [87]. The results of a group comprised of 122 patients treated with SES were compared with a historical control group of 259 patients treated for the same kind of lesions during an antecedent 2-year period. Coronary enzyme release during the procedures was insignificantly different despite considerably longer stented segments in the SES treated group. At 6-month follow-up, the cumulative rate of MACE was 16.4% in the SES group and 35.1% in the BMS group ($p < 0.001$), whereas the incidence of restenosis was 9.2% and 33.3% ($P < 0.001$) in SES vs BMS, respectively. The need for revascularization in the SES group was significantly lower, both for target lesion revascularization (TLR) (7.4 vs. 26.3%, $P < 0.001$) and TVR (9.0 vs. 29.0%, $P < 0.001$). No differences were observed between the groups in the occurrence of death, myocardial infarction, or stent thrombosis in the 6-month observation period.

The e-CYPHER was a registry designed to capture postmarketing surveillance data on the use of SES. Between April 2002 and September 2005, data on 15,157 patients treated with SES at 279 centers from 41 countries were entered into the registry. From the total amount of patients enrolled in the registry, 6-month follow-up data were available for 10,962 patients. A sub-analysis [88] assessed the outcomes of CTO, defined as an occlusion lasting > 3 months. A total of 415 patients were identified, representing 2.9% of the total population. When their results were compared with those ones seen for the rest of the patients enrolled in the registry, there was no difference regarding death, myocardial infarction, TLR, or MACE. Investigators concluded that the event rates were similar for patients with CTO treated with the SES and patients treated for other lesion types, with a low rate of TLR (2.9%) and MACE (6.5%) in the CTO group at 6-month follow-up.

The Sirolimus-eluting Stent in Chronic Total Occlusion (SICTO) study was a multicentre, prospective, non-randomized study of coronary stenting with SES in patients with CTOs [89]. A total amount of 25 patients was treated with the SES stent after successful balloon angioplasty and IVUS examination. At 6-month angiographic and IVUS follow-up, the use of the SES stent was associated with improvements both in reference vessel diameter and minimum lumen diameter. In addition, the rate of in-stent late loss was -0.1 ± 0.3 mm and percent stent plaque volume was $13.1 \pm 18.4\%$. The number of events at 6 months was also very low, with no deaths, myocardial infarction, stent thrombosis, or target lesion revascularization. There were 2 cases of target vessel revascularization (8%).

As a part of a multicentre Asian registry evaluating DES, Nakamura et al. investigated clinical and angiographic outcomes in 60 patients who received SES and 120 patients who received BMS [83]. After 6 months, the SES group still had significantly lower restenosis and reocclusion rates (2% and 0%, respectively) than did the BMS group (32% and 6%, respectively). Afterwards the loss was significantly smaller in the SES group than in the BMS group. Moreover, the SES group had fewer cardiac events, including target lesion revascularization (2% vs 23%, $p < 0.001$), than the BMS group did. At 1 year, treatment with SES was associated with sustained reductions in hierarchical MACE and TLR.

The ACROSS/TOSCA 4 (Approaches to Chronic Occlusions with Sirolimus-Eluting Stents/Total Occlusion Study of Coronary Arteries 4) study was a multicenter, non randomized pro-

spective trial, which examining the safety and efficacy of SES in CTOs PCI. In this study, the 6-months binary restenosis rates were 9.5% in-stent, 12.4% in-segment, and 22.6% in-“working length” representing the entire treatment segment. Rates of 1-year target lesion revascularization, MI and target vessel failure were 9.8%, 1.0% and 10.9%, respectively. Stent thrombosis occurred in two patients (1.0%) [90].

More recently, Galassi et al. have published the results of SECTOR (Sirolimus-Eluting Stent in Complex Coronary Chronic Total Occlusion Revascularization) Registry designed to assess angiographic and clinical outcomes after sirolimus-eluting stent (SES) implantation in the setting of a “real world” series of complex CTOs [91]. In this registry, the 9-12 months angiographic follow-up performed in 85.5% of lesions showed a binary restenosis rate of 16.8%. Moreover, at 2-year clinical follow-up, the rates of target lesion revascularization, non-Q wave MI, and total MACE were of 11.1%, 2%, and 13.1%, respectively.

6.3. Sirolimus eluting stents for CTOs - Randomized trials

The PRISON II [92] has been the first randomized trial performed to compare DES and BMS. PRISON II addressed a primary end point of angiographic binary restenosis at six months and secondary end points of MACE, target vessel failure (TVF), in-stent and in-segment mean luminal diameter (MLD), late lumen loss, late-loss index, and percent diameter stenosis at six months. A total of 200 patients were randomized to a bare BX Velocity stent or to the SES. In-stent restenosis results were 7% for the SES patient cohort vs. 36% for the patients in the bare metal control arm of the study ($p < 0.001$). The SES also achieved statistical significance in key clinical endpoints such as target lesion revascularization (4% vs. 19%; $p = 0.001$); TVF (8% vs 24%; $p = 0.003$) and MACE (4% vs 20%; $p < 0.001$). In-stent late loss in the SES patient cohort was 0.05 mm and 1.09 mm in the control ($p = 0.0001$). Such strong evidence from a well-conducted randomized study has provided clear evidence of efficacy of the SES and follow up is awaited to evaluate the long term outcomes.

Long term results of PRISON II were recently published [93]. At 5-year follow-up, event rates still favoured the SES arm over the BMS arm. In fact, SES group had significantly lower rates of target lesion revascularisation (12% vs. 30%, $p = 0.001$), target vessel revascularisation (17% vs. 34%, $p = 0.009$) and MACE (12% vs. 36%, $p < 0.001$). There were no significant differences in death and myocardial infarction. On the other hand, there is a trend to a higher stent thrombosis rate in the SES group (8% vs. 3%, $p = 0.21$).

The CORACTO study [94] was performed to evaluate the sirolimus-coated CURA stent in 95 patients with a CTO of > 3 months duration. Patients were randomized to treatment with either the CURA stent or BMS implantation; the primary end-point was late loss and restenosis at 6 months. Follow-up angiography demonstrated significant differences between the two groups in favour of CURA stents. The mean late loss was 1.46 mm in those treated with BMS vs 0.41 mm in the CURA stent group ($p < 0.001$). The suppression of neointimal proliferation was associated with less restenosis, reocclusion, and need for TVR. No patient died or suffered a stent thrombosis or myocardial infarction.

6.4. Comparative DES trials in CTOs revascularization

The clinical outcomes of both SES and PES for the treatment of CTO were further analyzed in the registry data from Rotterdam [95]. A cohort of 76 patients was treated with SES; subsequently, in the first quarter of 2003, all patients were treated with PES, including 57 treated for a CTO. These patients were compared with a similar group of patients (n=26) treated with BMS in the 6-month period preceding April 2002. At 400 days, the cumulative survival-free of target vessel revascularization was 80.8% in the BMS group versus 97.4% and 96.4% in the SES and PES groups respectively ($p=0.01$). The authors concluded that the use of both the SES and PES in the treatment of CTOs reduces the need for repeat revascularization compared to BMS.

Another report by Jang et al. involved 107 patients with CTO who received SES, and 29 patients with CTO who received PES [96]. At 6-month angiographic follow up, the restenosis rate was significantly higher in the PES group (28.6% vs. 9.4%; $p = 0.02$). Similarly, the late loss was significantly higher in the PES group (0.8 mm vs. 0.4 mm; $p = 0.025$). At one-year follow up, the MACE-free survival rate was significantly higher in the SES group (95.8% vs. 85.8%; $p = 0.049$).

Recently, a randomized study evaluating SES and PES has been performed by De Lezo et al [97]. No significant differences were reported between SES and PES in the rates of restenosis (7.4% versus 19%, respectively) and TLR (3.3% versus 7.0%). However, the PES group was found to have a significantly higher late loss and neointimal area on intravascular ultrasound. At 15 months, death and myocardial infarction rates were comparable between the two stents.

A prospective analysis of 1149 patients with 1183 CTOs (396 SES, 526 PES, 177 ZES, 64 EPC capture, 43 EES) in five high volume Asian centers after successful recanalization of CTO was recently performed [98]. The study endpoints were 30 days and 9 months MACE, 9 months angiographic restenosis and TLR. In this series patients treated with SES showed lesser rate of restenosis compared with other drug-eluting stents.

PRISON III ongoing trial will address whether or not SES are superior to other drug-eluting stents in total coronary occlusions. Indeed this prospective, randomized trial, SES implantation will be compared with zotarolimus-eluting stent implantation for the treatment of total coronary occlusions. A total of 300 patients will be followed for up to 5 years with angiographic follow-up at 8 months. The primary end point will be in-segment late luminal loss at 8 months angiographic follow-up [99].

A new randomised ongoing trial, the Non-Acute Coronary occlusion treated by EveroLimus-Eluting Stent (CIBELES) trial, aims to compare everolimus-eluting stent and sirolimus-eluting stent in treating CTOs, in terms of angiographic efficacy [100].

6.5. Optimization of stent deployment

The introduction of stent delivery systems, which used semi-compliant balloons to deploy stents at higher pressures, initially resulted in less use of balloon post-dilatation. However, it was soon recognized that adjunctive balloon post-dilatation following deployment of BMS im-

proved stent expansion in its entire length and resulted in better outcomes with less need for TVR [101-103]. Consequently, post-dilatation has been widely, although not universally, used. With the advent of DES and much lower rates of TVR, there has been renewed controversy regarding the need for adjunctive balloon post-dilatation to optimize outcomes. However DES thrombosis, which might be related to procedural variables, such as minimal stent area (MSA) and stent expansion following stent deployment, makes a come back the role of post-dilatation. Indeed, the frequency of stent thrombosis following DES implantation is relatively low [104-105], but the clinical sequelae of stent thrombosis are catastrophic and include death in about 45% of patients and non-fatal myocardial infarction in most of the survivors [106].

Similarly to stent thrombosis, maximizing MSA appears important in reducing the risk of TVR. This should be theoretically even more important in case of long standing CTO where severe and diffuse disease in presence of extensive calcification might prevent adequate stent expansion [107].

The inability to achieve optimum stent deployment is not due to undersizing the stent delivery balloon, but rather due to an inability of the stent delivery balloon to expand fully the stent to nominal size. With postdilatation using noncompliant balloons, the frequency of achieving optimum stent deployment doubles [108].

Lesions with heavy calcification or large plaque burden, such as CTO lesion, are likely to have increased resistance to dilatation. In such situations, inadequate stent expansion may be evident from the contour of the deployment balloon or the angiographic appearance of the stent post stent deployment. However, inadequate stent expansion is usually not detectable by angiographic assessment. In situations where there is likely to be increased resistance to dilatation, postdilatation with noncompliant balloons at high pressure appears to be a good strategy.

Theoretically, in an attempt to minimize stent thrombosis and TVR, post-dilatation with non-compliant balloons should be performed by IVUS guidance. Unfortunately, it is not practical and probably not cost-effective to perform IVUS and post-dilatation to all patients undergoing DES implantation. Moreover after DES implantation in long CTO lesion with multiple stents overlapping is recommended to perform post-dilatation with non compliant balloon in order to improve MSA and thus to obtained a good angiographic outcome.

Post-dilatation can improve significantly MSA within the limits of reference vessel size even if it is still likely not to affect non-uniformity expansion. An uniform stent expansion may be achieved with either adequate pre-dilatation or by the use of rotational atherectomy in calcified lesions to allow the symmetric expansion of the lesion by the balloon and stent.

7. Complications of CTO PCI

The PCI CTO procedural complications can be classified as follows: vascular access related and procedure related. Despite the development of new devices and techniques, complications still occasionally occur today. This is highlighted by the complications reducing with

improved learning curve. Therefore, the operator's experience is essential in order to quickly recognise and handle all sorts of complications.

7.1. Complications vascular access related

Access site complications are common during intravascular procedure and include hematomas of any size, pseudoaneurysm, and artero-venous fistulae [109]. Despite of the need of large size sheath and double coronary cannulation, both femoral vascular access are generally recommended during CTO PCI. Some operators prefer to place two sheaths in the same femoral artery, in order to reduce patient discomfort (Figure 8) however, this approach restrict the use up to smaller size sheaths and might limit the use of closure device after procedure thus increasing the occurrence of rare complication such as acute limb ischemia.

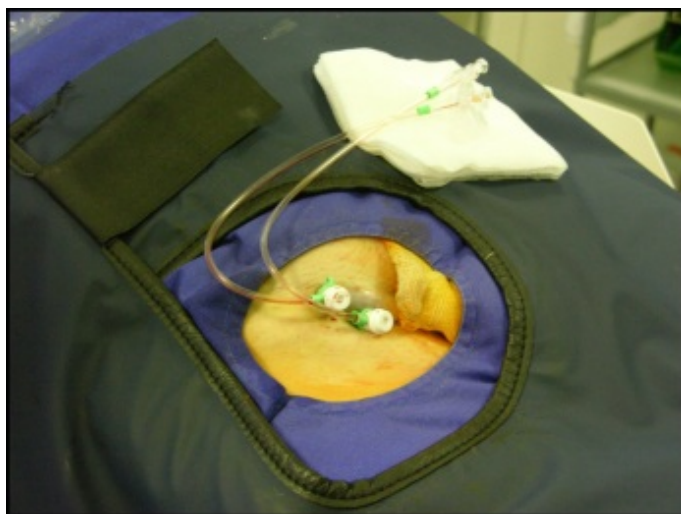

Figure 8. Two 6 French sheath in a femoral artery

Such complications are more frequent in older, female, overweight or previously anticoagulated patients, and can be prevented by careful puncture, compression technique and 6-12 hours bed rest after procedure. Small hematomas are common (2-15%) and usually produce only mild discomfort for a few days. Large hematomas (>10 cm) are less frequent (1-2%) and might require prolonged rest and a delay in hospital discharge; the complete resolution, thus may take in 3-4 weeks. Diagnosis can be based on clinical features (no femoral murmur) and confirmed by a Doppler study performed with standard echocardiography equipment. Occasionally, large hematomas become infected, and in this case is important to surgically drain the cavity by purulent materials. This may take 2-3 months to heal.

Uncontrolled bleeding (either evident or into retroperitoneal space) with severe haemodynamic compromise require aggressive fluid blood replacement, ruling out bleeding from another origin. In these cases vascular surgery might resolve the complications.

Femoral pseudoaneurysm and artero-venous fistulae might occur in case of low puncture (more than 2 cm below the inguinal ligament). Diagnosis is based on clinical grounds (the presence of hard and pulsatile mass in the case of pseudoaneurysm and the presence of continuous murmur in case of an artero-venous fistulae) and confirmed by Doppler examination. In most cases pseudoaneurysm can be closed successfully with femoral compression guided by echocardiography followed by bed rest for 12-24 hours after discontinuation of antithrombotic medication.

Dissection can be caused by the wire or the sheath at the access site and can extend retrogradely upward in to the vascular system; this occurs more frequently in older and hypertensive patients with marked aortic tortuosity and may cause limb ischemia.

7.2. Complications procedure related

Complications directly related to CTO procedure might be summarized in: *coronary perforation or rupture, coronary ostium dissection, coronary thrombosis and entrapment of device into a lesion*. Among these complications, coronary perforation is associated with different adverse cardiac event such as myocardial infarction and cardiac tamponade. Although coronary perforation accounts for 10% of total referrals for emergent cardiac surgery, it is most commonly managed in the catheterization laboratory with different approach. Several large PCI series shows an incidence of coronary perforation below 1% [110-113], and the presence of a CTO does not seem to increase significantly this value [114].

7.3. Coronary perforation

During PCI, coronary perforation is one of the most undesirable complications because it is occasionally life-threatening by causing cardiac tamponade or acute myocardial infarction [110-113]; it represents a disruption of the vessel wall through the intima, media and adventitia. Coronary perforations risk factors during standard PCI can be classified as *patient related, angiographic related and device and/or procedure related*. In term of *patient-related* risk several studies found that older age and female gender are associated with an increased incidence of coronary perforation [107, 108, 115].

Angiographic related risk factors are represented by heavy calcification and innaccurate assessment of vessel diameter size. Indeed, these lesions require often the use of multiple balloon dilatations coupled with relatively high inflation pressure, before and/or after stent implantation, in order to achieve full stent expansion. These might cause vessel wall perforation, especially when are used compliant or semi-compliant balloon. In a study of Tobis et al. the use of a high balloon to vessel ratio (1.2:1) with a mean inflation pressure of 15 atm determined an incidence of vessel rupture and major dissection of approximately 3-4% of the cases [116]. In the same study, the use of a smaller balloons, in a different subgroup, but with higher mean inflation pressure (16 atm) was associated with reduction of coronary perforation rate (0.7%) [116]. For these reasons, we suggest to use small diameter size balloon when performing PCI in CTO lesion.

Among device and/or procedure related complications several authors have shown that the use of *atheroblative debulking devices (laser, rotational atherectomy, directional coronary atherectomy)* might be associated with coronary perforation [112-113]. Other devices such as cutting balloon, IVUS probe, extraction catheters and embolic protection device might also enhance the likelihood of coronary perforation, as well as stiffer and/or hydrophilic wires that are routinely used for CTO recanalization. During the procedure is important to follow the path of the guide wire in multiple orthogonal projection, in order to recognize promptly site of vessel wall apart or segment of sub-intimal tracking.

Perforation due to stiff wires are divided in two categories: perforation of the false lumen while advancing the stiff wire into it, and perforation in distal small branch after crossing CTO lesion. Generally the first type of perforation do not require a specific treatment because it disappears after dilatation on another false lumen. Conversely in distal small branch perforation a careful observation through multiple contrast injection are needed to confirm the risk related to perforation. Indeed, these might lead to early or late cardiac tamponade. Thus, is recommended at the end of procedure, even if in successful cases, to perform at least two orthogonal cine angiograms to exclude the presence of it.

Ellis et al., on the basis of prospectively recorded data of a total of 12.900 PCI procedure from 11 US sites during a 2-year period [110], were able to draw a coronary perforation classification related to the angiographic appearance of blood extravasation during the procedure in four types:

- Type I, perforation with extraluminal crater without extravasation
- Type II, pericardial or myocardial blush without contrast jet extravasation
- Type III, extravasation through frank ($\geq 1\text{mm}$) perforation
- Type IV (cavity spilling) perforation into anatomic cavity chamber, coronary sinus, etc.

In addition this study evaluated its proposal classification system as a tool to predict outcome and as the basis management as follow:

- Type I: fully contained perforation rarely result in tamponade or in myocardial ischemia
- Type II: limited extravasation perforation have high treatment success rate when managed with prolonged balloon inflation, and commonly have a low occurrence of persistent contrast extravasation, consequently resulting in a low incidence of adverse sequelae
- Type III: brisk extravasation perforation are associated with rapid development of hemodynamic compromise and life-threatening complication, include cardiac tamponade and the need for emergent bypass surgery with high rate of mortality

Myocardial infarction and the majority of emergent CABG and cardiac tamponade were entirely limited of type III perforation [113]. Coronary perforation is associated with a significant mortality risk; its management and treatment need to be initiated very quickly. The strategy of treatment is determinate by angiographic characteristics and clinical circumstances [115].

In case of *type I perforation*, the retrieval of guidewire is sufficient to cope with the complication. In other cases a prolonged (3-5 minutes) proximal balloon inflation or stent implantation might help to solve the problem. However, a careful observation for 15-30 minutes with repeated injection of contrast mean is highly recommended. If the extravasation enlarges during time, intravenous administration of protamine sulfate is advised in order to neutralizing the anticoagulant effect, as patients performing CTO PCI are treated by unfractionated heparin alone. Generally re-administration of protamine sulfate is given intravenously over a 3-5 min time period for obtaining a ACT target less than 150 seconds as reported [112-115]. Moreover, it is to remember that protamine sulfate administration is safe in case of BMS implantation [117] but it might cause, albeit rarely, stent thrombosis with potential fatal consequences, in case of DES use [118].

In *type II perforation*, proximal balloon inflation and reversal of anticoagulation with protamine sulfate are the first actions to take. Echocardiographic assessment should be performed without delay; early diastolic right ventricular collapse and late diastolic right atrial collapse are early signs of cardiac tamponade and precede the haemodynamic instability. If these signs are observed urgent pericardiocentesis should be recommended and this is an action to be taken immediately after recognition of the perforation and before clinical symptoms develop. A placement of coronary perfusion catheter (CPC) balloon might be indicated, if after 5-10 minutes of proximal balloon inflation the seal of perforation does not occur. The passive CPC balloon has been initially developed to allow demands of the myocardium at risk, for prolonged inflation in patients with rigid artery stenosis [119] and later modified to seal coronary perforation. Several types of this device have the same principle design which consist of side-holes in the shaft of the catheter proximal and distal to the balloon, allowing passive blood perfusion during balloon inflation, depending on the aortic perfusion pressure. Perfusion catheters provide a blood flow of 40-60 ml/minutes to the region at risk [119]. Nevertheless, a significant number of patients do not tolerate prolonged inflation periods, either because of obstruction of a side branch or due to inadequate flow relative to the demands of the myocardium at risk. Therefore the CPC balloon devices might be used in preparation of emergent cardiac surgery [120], reducing pericardial blood blush and Q wave myocardial infarction occurrence. Emergent cardiac surgery is reserved for patients in whom hemostasis is not achieved with these measures.

The onset of *type III perforation* is usually dramatically: an immediate aggressive treatment strategy is needed, including adequate volume resuscitation, administration of catecholamines and urgent pericardiocentesis. Obviously, a proximal balloon inflation and heparin reversal is also needed immediately; and after the stabilization of patient clinical status a placement of covered stent (in case of epicardial coronary rupture) or synthetic microsphere embolization (in case of distal perforation) might seal the perforation [111-115]. In case of perforation resolution is advisable a careful post-procedure echocardiograms monitoring, before pericardial catheter removal and at discharge. The figure 9 reports a practical algorithm for the management of coronary perforation adapted by Dippel and colleagues [121] (Figure 9)

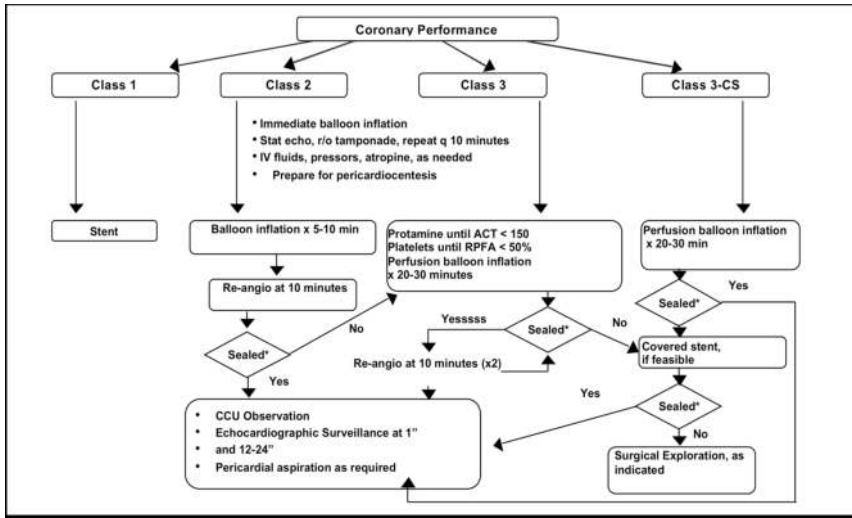


Figure 9. Algorithm of coronary perforation management in relation to angiographic type; adapted by Dippel et. al

7.4. Coronary ostium dissection

The need of high back-up force in CTO PCI, make the choice of guiding catheter very important. Several high back-up guiding catheters, such as Amplatz, could injure the coronary ostium, causing flow limiting tubular dissection. Indeed, “maladroitt” manipulation of guiding catheter or its deep intubation might also cause ostium dissection. This event happens frequently in the right coronary artery in case of proximal vessel disease. Thereafter in these case is recommended to stabilized the ostium and the proximal part of the vessel with stent implantation prior to beginning CTO PCI. Particular attention might give at the cannulation of donor vessel in case of retrograde approach. Indeed a dissection in the donor vessel might cause severe peri-procedural events.

7.5. Coronary thrombosis

The use of complex technique, such as retrograde approach and the use of multiple guide wire and device might added the risk of coronary thrombosis. Thus, after administration of initial bolus of 80-100 Units/Kg is recommended checking the ACT every 30 minutes maintaining the ACT >300 seconds (>350 second in case of retrograde approach). Indeed, careful observation in an angiogram might help to recognize early phase of coronary thrombosis. If a thrombus is observed, is advisable to abort the procedure, take away the double cannulation and resolve the situation with use of aspiration device and Gp IIb/IIIa inhibitors administration. Distal embolization resulting in slow-flow phenomenon is very frequent after CTO balloon dilatation; in these cases intracoronary administration of vasodilator such as adenosine or nitroprusside could improve coronary flow significantly.

7.6. Entrapment of device inside a lesion

Entrapment of device such as microcatheter or standard balloon might occur after CTO wire crossing especially in highly calcified and tortuous vessel. Several dedicated devices such as Tornus catheter, Corsair and Gopher might rarely stuck into the vessel in severe calcified lesions. Such an evenience might be approached by the see saw technique with stiff wires; indeed, the use of another stiff wire might find the way of a new dissection plane at the blocking site, breaking the calcium load which grapped the device. During retrograde approach, in case of very tortuous collaterals it is also possible entrapment of guide wire within the coronary artery. In these cases attention should be paid not to twist the wire into collaterals, as solution to this complication is only surgery.

Author details

Simona Giubilato, Salvatore Davide Tomasello and Alfredo Ruggero Galassi

Department of Medical Sciences and Pediatrics, Catheterization Laboratory and Cardiovascular Interventional Unit, Cannizzaro Hospital, University of Catania, Italy

References

- [1] Christofferson RD, Lehmann KG, Martin GV et al. Effect of chronic total coronary occlusion on treatment strategy. *Am J Cardiol* 2005; 95, 1088-1091.
- [2] Melchior JP, Doriot PA, Chatelain P, Meier B, Urban P, Finci L, Rutishauser W. Improvement of left ventricular contraction and relaxation synchronism after recanalization of chronic total coronary occlusion by angioplasty. *J Am Coll Cardiol* 1987;9:763-8.
- [3] Warren RJ, Black AJ, Valentine PA, Manolas EG, Hunt D. Coronary angioplasty for chronic total occlusion reduces the need for subsequent coronary bypass surgery. *Am Heart J* 1990;120:270-4.
- [4] Ivanhoe RJ, Weintraub WS, Douglas JS, Jr., Lembo NJ, Furman M, Gershony G, Cohen CL, King SB, 3rd. Percutaneous transluminal coronary angioplasty of chronic total occlusions. Primary success, restenosis, and long-term clinical follow-up. *Circulation* 1992;85:106-15.
- [5] Werner GS, Surber R, Kuethe F, Emig U, Schwarz G, Bahrmann P, Figulla HR. Collaterals and the recovery of left ventricular function after recanalization of a chronic total coronary occlusion. *Am Heart J* 2005;149:129-37.
- [6] Suero JA, Marso SP, Jones PG, Laster SB, Huber KC, Giorgi LV, Johnson WL, Rutherford BD. Procedural outcomes and long-term survival among patients undergoing

- percutaneous coronary intervention of a chronic total occlusion in native coronary arteries: a 20-year experience. *J Am Coll Cardiol* 2001;38:409-14.
- [7] Moreno R, Conde C, Perez-Vizcayno MJ, Villarreal S, Hernandez-Antolin R, Alfonso F, Banuelos C, Angiolillo DJ, Escaned J, Fernandez-Ortiz A, Macaya C. Prognostic impact of a chronic occlusion in a noninfarct vessel in patients with acute myocardial infarction and multivessel disease undergoing primary percutaneous coronary intervention. *J Invasive Cardiol* 2006;18:16-9.
- [8] van der Schaaf RJ, Vis MM, Sjauw KD, Koch KT, Baan J, Jr., Tijssen JG, de Winter RJ, Piek JJ, Henriques JP. Impact of Multivessel Coronary Disease on Long-Term Mortality in Patients With ST-Elevation Myocardial Infarction Is Due to the Presence of a Chronic Total Occlusion. *Am J Cardiol* 2006;98:1165-9.
- [9] Claessen BE, van der Schaaf RJ, Verouden NJ, Stegenga NK, Engstrom AE, Sjauw KD, Kikkert WJ, Vis MM, Baan J, Jr., Koch KT, de Winter RJ, Tijssen JG, Piek JJ, Henriques JP. Evaluation of the effect of a concurrent chronic total occlusion on long-term mortality and left ventricular function in patients after primary percutaneous coronary intervention. *JACC Cardiovasc Interv* 2009;2:1128-34.
- [10] 10. Srivatsa SS, Edwards WD, Boos CM, Grill DE, Sangiorgi GM, Garratt KN, Schwartz RS, Holmes DR Jr. – Histologic correlates of angiographic chronic total coronary artery occlusions influence of occlusion duration on neovascular channel patterns and intimal plaque composition. *J Am Coll Cardiol* 1997; 29, 955-963.
- [11] Stone GW, Reifart NJ, Moussa I, Hoye A, Cox DA, Colombo A, Baim DS, Teirstein PS, Strauss BH, Selmon M, Mintz GS, Katoh O, Mitsudo K, Suzuki T, Tamai H, Grube E, Cannon LA, Kandzari DE, Reisman M, Scharwtz RS, Bailey S, Dangas G, Meharan R, Abizaid A, Moses JW, Leon MB, Serruys PW – Percutaneous recanalization of chronically occluded coronary arteries: a consensus document: Part I. *Circulation* 2005; 112, 2364-72..
- [12] Burke AP, Kolodgie FD, Farb A, Weber D, Virmani R – Morphological predictors of arterial remodeling in coronary atherosclerosis. *Circulation* 2002; 105, 297-303.
- [13] Kinoshita I, Katoh O, Nariyama J, Otsuji S, Tateyama H, Kobayashi T, Shibata N, Ishihara T, Ohsawa N – Coronary angioplasty of chronic total occlusions with bridging collateral vessels: immediate and follow-up outcome from a large single-center experience. *J Am Coll Cardiol* 1995; 26, 409-415.
- [14] Sakuda H, Nakashima Y, Kuriyama S, Sueishi K – Media conditioned by smooth muscle cells cultured in a variety of hypoxic environments stimulates in vitro angiogenesis. *Am J Pathol* 2002; 141, 1507-1516.
- [15] Hoye A. – The how and why of...Chronic total occlusions. Part two: why we treat CTOs the way we do. Understanding the way we approach percutaneous coronary recanalisation of chronic total occlusions. *EuroInterv.* 2006; 2, 382-388.

- [16] Werner GS, Emig U, Mutschke O et al. Regression of collateral function after recanalization of chronic total coronary occlusion: a serial assessment by intracoronary pressure and doppler recordings. *Circulation* 2003; 108, 2877-2882.
- [17] Zidar FJ, Kaplan BM, O'Neill WW et al. Prospective, randomized trial of prolonged intracoronary urokinase infusion for chronic total occlusions in native coronary arteries. *J Am Coll Cardiol* 1996; 27, 1406-1412.
- [18] Di Mario C, Werner S, Sianos G et al. – European perspective in the recanalisation of Chronic Total Occlusion (CTO): consensus document from the EuroCTO club. *Euro-Interv* 2007; 3, 30-43.
- [19] Srivatsa S, Holmes D. The histopathology of angiographic chronic total coronary artery occlusion and changes in neovascular pattern and intimal plaque composition associated with progressive occlusion duration. *J Invasive Cardiol* 1997; 9, 294-301.
- [20] Pupita G, Maseri A, Galassi AR, et al. Myocardial ischemia caused by distal coronary constriction in stable angina pectoris. *N Engl J Med* 1990; 323: 514-520.
- [21] Cockcroft DW, Gault MH. Prediction of creatinine clearance from serum creatinine. *Nephron* 1976; 16:31-41
- [22] Yoshitani H, Akasaka T, Kaji S et al. Effects of IABP on coronary pressure in patients with stenotic coronary arteries. *Am Heart J* 2007;154:725-31.
- [23] Briguori C, Airolidi F, Chieffo A, et al. Elective versus provisional intraaortic balloon pumping in unprotected left main stenting. *Am Heart J* 2006; 152: 565-72.
- [24] Noguchi T, Miyazaki S, Morii I, Daikoku S, Goto Y, Nonogi H. Percutaneous transluminal coronary angioplasty of chronic total occlusions. determinants of primary success and long-term clinical outcome. *Cathet Cardiovasc Interv* 2000; 49:258–264
- [25] Bonow RO. Identification of viable myocardium. *Circulation* 1996; 94: 2674-80.
- [26] Haas F, Haehnel CJ, Picker W et al. Preoperative positron emission tomography viability assessment and perioperative and postoperative risk in patients with advanced ischemic heart disease. *J Am Coll Cardiol* 1997; 30: 1693-700.
- [27] Ragosta M, Beller GA, Watson DD, Kaul S, Gimble LW Quantitative planar rest-redistribution ²⁰¹Tl imaging in detection of myocardial viability and prediction of improvement in left ventricular function after coronary by-pass surgery in patients with severely depressed left ventricular function. *Circulation* 1998; 97: 833-38
- [28] Galassi AR, Centamore G, Fiscella A, et al. Comparison of rest-redistribution thallium-201 imaging and reinjection after stress-redistribution for the assessment of myocardial viability in patients with left ventricular dysfunction secondary to coronary artery disease. *Am J Cardiol* 1995; 75: 436-442
- [29] Kauffamn GJ, Boyne TS, Watson DD, Smith WH, Beller GA. Comparison of rest thallium-201 imaging and rest technetium-99m sestamibi imaging for assessment of my-

- ocardial viability in patients with coronary artery disease and severe left ventricular dysfunction. *J Am Coll Cardiol* 1996; 7: 1592-97.
- [30] Galassi AR, Tamburino C, Grassi R. et al Comparison of technetium-99m tetrofosmin and thallium-201 single photon emission computed tomographic imaging for the assessment of viable myocardium in patients with left ventricular dysfunction. *J Nucl Cardiol* 1998; 5: 56-63.
- [31] Bax JJ, Cornel JH, Visser FC et al. Prediction of improvement of contractile function in patients with ischemic ventricular dysfunction after revascularization by fluorine-18 fluorodeoxyglucose single-photon emission computed tomography. *J Am Coll Cardiol* 1997; 30: 377-83.
- [32] Allman KC, Shaw IJ, Hachamovitch R, Udelson JE. Myocardial viability testing and impact of revascularization on prognosis in patients with coronary artery disease and left ventricular dysfunction: a meta-analysis. *J Am Coll Cardiol* 2002; 39: 1151-8.
- [33] The Bypass Angioplasty Revascularization Investigation (BARI) Investigators. Comparison of coronary bypass surgery with angioplasty in patients with multivessel disease. *N Engl J Med* 1996; 335: 217- 225.
- [34] Zimarino M, Calafiore AM, De Caterina R. Complete myocardial revascularization: between myth and reality. *Eur Heart J* 2005; 26: 1824-30.
- [35] Hannan EL, Racz M, Holmes DR, et al. Impact of completeness of percutaneous coronary intervention revascularization on long-term outcomes in the stent era. *Circulation* 2006; 113: 2406- 12.
- [36] Iskander S, Iskandrian AE. Risk assessment using single-photon emission computed tomographic technetium-99m sestamibi imaging. *J Am Coll Cardiol* 1998; 32: 57-62.
- [37] Galassi AR, Foti R, Azzarelli S, et al. Usefulness of exercise tomographic myocardial perfusion imaging for detection of restenosis after coronary stent implantation. *Am J Cardiol* 2000; 85: 1362-1364.
- [38] Bax JJ, Wijns W, Cornel JH, Visser FC, Boersma E, Fioretti PM. Accuracy of currently available techniques for prediction of functional recovery after revascularization in patients with left ventricular dysfunction due to chronic coronary artery disease: comparison of pooled data. *J Am Coll Cardiol* 1997; 30: 1451-1460.
- [39] Breisblatt WM, Barnes JV, Weiland F, Spaccavento IJ. Incomplete revascularization in multivessel percutaneous transluminal coronary angioplasty: the role for stress thallium-201 imaging. *J Am Coll Cardiol* 1988; 11: 118-90.
- [40] Lauer MS, Lytle B, Pashkow CE, Marwick TH. Prediction of death and myocardial infarction by screening with exercise-thallium testing after coronary-artery-bypass grafting. *Lancet* 1998; 351: 615-622.
- [41] Alazraki NP, Krawczynska EG, Kosinski AS, et al. Prognostic value of thallium-201 single-photon emission computed tomography for patients with multivessel coro-

- nary artery disease after revascularization (the Emory Angioplasty Versus Surgery Trial – EAST). *Am J Cardiol* 1999; 84: 1369-1374.
- [42] Galassi AR, Grasso C, Azzarelli S, Ussia G, Moshiri S, Tamburino C. Usefulness of exercise myocardial scintigraphy in multivessel coronary disease after incomplete revascularization with coronary stenting. *Am J Cardiol* 2006; 97: 207-215.
- [43] Galassi AR, Tomasello SD, Barrano G et al. Long term outcome of patients with chronic total occlusions: the value of monitoring percutaneous coronary intervention by non-invasive imaging. *Eur Heart J* 2008; 29 Suppl: 774.
- [44] Werner GS, Surber R, Ferrari M, Fritzenwanger M, Figulla HR. The functional reserve of collaterals supplying long-term chronic total coronary occlusions in patients without prior myocardial infarction. *Eur Heart J* 2006; 27: 2406-2412.
- [45] Elasser A, Schelepper M, Klovekorn WP et al. Hibernating myocardium: an incomplete adaptation to ischemia . *Circulation* 1997; 96: 2920-31.
- [46] Beanlands RS, Hendry PJ, Masters RG et al. Delay in revascularization is associated with increased mortality rate in patients with severe left ventricular dysfunction and viable myocardium on fluorine 18-fluorodeoxyglucose positron emission tomography imaging. *Circulation* 1998; 98 (Suppl): 1151-6.
- [47] Kim RJ, Fieno DS, Parrish RB, et al. Relationship of MRI delayed contrast enhancement to irreversible injury, infarct age, and contractile function. *Circulation* 1999;100:185–92.
- [48] Kim RJ, Fieno DS, Parrish TB, et al. Relationship of MRI delayed contrast enhancement to irreversible injury, infarct age, and contractile function. *Circulation* 1999, 100:1992-2002.
- [49] Rehwald WG, Fieno DS, Chen EL, Kim RJ, Judd RM: Myocardial magnetic resonance imaging contrast agent concentrations after reversible and irreversible ischemic injury. *Circulation* 2002, 105:224-229.
- [50] Schwitter J, Wacker C, van Rossum A, et al. MRIMPACT: comparison of perfusion-cardiac magnetic resonance with single-photon emission computed tomography for the detection of coronary artery disease in a multicentre, multivendor, randomized trial. *Eur Heart J* 2008, 29:480-489.
- [51] Kim RJ, Wu E, Rafael A, et al. The use of contrast-enhanced magnetic resonance imaging to identify reversible myocardial dysfunction. *N Engl J Med* 2000;343:1445–53.
- [52] Chen C, Li I, Chen Long I et al. Incremental doses of dobutamine induce a biphasic response in dysfunctional left ventricular regions subtending coronary stenoses. *Circulation* 1995; 92: 756-66.
- [53] Cigarroa CG, deFilippi CR, Brickner ME, Alvarez LG, Wait MA, Grayburn PA. Dobutamine stress echocardiography identifies hibernating myocardium and predicts

- recovery of left ventricular function after coronary revascularization. *Circulation* 1993; 88: 430-6.
- [54] Lombardo A, Loperfido F, Trani C et al. Contractile reserve of dysfunctional myocardium after revascularization: a dobutamine stress echocardiography study. *J Am Coll Cardiol* 1997; 30: 633-40.
- [55] Kuhl HP, Lipke CSA, Krombach GA et al. Assessment of reversible myocardial dysfunction in chronic ischaemic heart disease: comparison of contrast-enhanced cardiovascular magnetic resonance and a combined positron emission tomography – single photon emission computed tomography imaging protocol. *Eur Heart J* 2006; 27: 846-53.
- [56] Kim RJ, Shah DJ. Fundamental concepts in myocardial viability assessment revisited: when knowing how much is “alive” is not enough. *Heart* 2004; 90: 137-140.
- [57] Melzi G, Cosgrave J, Biondi-Zoccai GL, Airolidi F, Michev I, Chieffo A, Sangiorgi GM, Montorfano M, Carlino M, Colombo A. A novel approach to chronic total occlusions: the crosser system. *Catheter Cardiovasc Interv* 2006;68:29-35.
- [58] Galassi AR, Tomasello SD, Costanzo L, Campisano MB, Marzà F, Tamburino C. Recanalization of complex coronary chronic total occlusions using high-frequency vibrational energy CROSSER catheter as first-line therapy: a single center experience. *J IntervCardiol*. 2010 Apr;23(2):130-8
- [59] García-García HM, Brugaletta S, van Mieghem CA, Gonzalo N, Diletti R, Gomez-Lara J, Airolidi F, Carlino M, Tavano D, Chieffo A, Montorfano M, Michev I, Colombo A, van der Ent M, Serruys PW. CROSSERAs First choice for crossing Totally occluded coronary arteries (CRAFT Registry): focus on conventional angiography and computed tomography angiography predictors of success. *EuroIntervention*. 2011 Aug;7(4): 480-6).
- [60] Whitlow PL, Burke MN, Lombardi WL, Wyman RM, Moses JW, Brilakis ES, Heuser RR, Rihal CS, Lansky AJ, Thompson CA; FAST-CTOs Trial Investigators. Use of a novel crossing and re-entry system in coronary chronic total occlusions that have failed standard crossing techniques: results of the FAST-CTOs (Facilitated Antegrade Steering Technique in Chronic Total Occlusions) trial. *JACC Cardiovasc Interv*. 2012 Apr;5(4):393-401.
- [61] Werner GS, Schofer J, Sievert H, Kugler C, Reifart NJ. Multicentre experience with the BridgePoint devices to facilitate recanalisation of chronic total coronary occlusions through controlled subintimal re-entry. *EuroIntervention* 2011;7:192-200.
- [62] Galassi AR, Tomasello SD, Reifart N, Werner GS, Sianos G, Bonnier H, Sievert H, Eh-ladad S, Bufe A, Shofer J, Gershlick A, Hildick-Smith D, Escaned J, Erglis A, Sheiban I, Thuesen L, Serra A, Christiansen E, Buettner A, Costanzo L, Barrano G, Di Mario C. In-hospital outcomes of percutaneous coronary intervention in patients with chronic total occlusion: insights from the ERCTO (European Registry of Chronic Total Occlusion) registry. *EuroIntervention* 2011;7:472-9.

- [63] Reifart N. The parallel wire technique for chronic total occlusions: Interventional Course Frankfurt, 1995: p. personal communication.
- [64] Colombo A, Mikhail GW, Michev I, Iakovou I, Airolidi F, Chieffo A, Rogacka R, Carlino M, Montorfano M, Sangiorgi GM, Corvaja N, Stankovic G. Treating chronic total occlusions using subintimal tracking and reentry: the STAR technique. *Catheter Cardiovasc Interv* 2005;64:407-11; discussion 412.
- [65] Carlino M, Godino C, Latib A, Moses JW, Colombo A. Subintimal tracking and reentry technique with contrast guidance: a safer approach. *Catheter Cardiovasc Interv* 2008;72:790-6.
- [66] Carlino M, Latib A, Godino C, Cosgrave J, Colombo A. CTO recanalization by intra-occlusion injection of contrast: the microchannel technique. *Catheter Cardiovasc Interv* 2008;71:20-6.
- [67] Stone GW, Kandzari DE, Mehran R, Colombo A, Schwartz RS, Bailey S, Moussa I, Teirstein PS, Dangas G, Baim DS, Selmon M, Strauss BH, Tamai H, Suzuki T, Mitsudo K, Katoh O, Cox DA, Hoye A, Mintz GS, Grube E, Cannon LA, Reifart NJ, Reisman M, Abizaid A, Moses JW, Leon MB, Serruys PW. Percutaneous recanalization of chronically occluded coronary arteries: A consensus document, Part 1. *Circulation* 2005;112:2364-2372.
- [68] Strauss BH, Segev A, Wright GA, Qiang B, Munce N, Anderson KJ, Leung G, Dick AJ, Virmani R, Butany J. Microvessels in chronic total occlusions: pathways for successful guidewire crossing? *J Interv Cardiol* 2005;18:425-36.
- [69] Galassi AR, Tomasello SD, Costanzo L, Campisano MB, Barrano G, Ueno M, Tello-Montoliu A, Tamburino C. Mini-STAR as bail-out strategy for percutaneous coronary intervention of chronic total occlusion. *Catheter Cardiovasc Interv*. 2012 Jan 1;79(1):30-40.
- [70] Surmely JF, Tsuchikane E, Katoh O, Nishida Y, Nakayama M, Nakamura S, Oida A, Hattori E, Suzuki T. New concept for CTO recanalization using controlled antegrade and retrograde subintimal tracking: the CART technique. *J Invasive Cardiol* 2006;18:334-8.
- [71] Tsuchikane E, Katoh O, Kimura M, Nasu K, Kinoshita Y, Suzuki T. The first clinical experience with a novel catheter for collateral channel tracking in retrograde approach for chronic coronary total occlusions. *J Am Coll Cardiol Intv* 2010;3:165-71.
- [72] Rathore S, Katoh O, Tsuchikane E, Oida A, Suzuki T, Takase S. A novel modification of the retrograde approach for the recanalization of chronic total occlusion of the coronary arteries intravascular ultrasound-guided reverse controlled antegrade and retrograde tracking. *JACC Cardiovasc Interv* 2010;3:155-64.
- [73] Sianos G. Stent CART, Reverse Stent CART, Septal Dilatation, and Retrograde Stenting: Technique and When to Consider. Presented at: Transcatheter Cardiovascular Therapeutics, Washington, DC, USA, 2010.

- [74] Sianos G, Barlis P, Di Mario C, Papafaklis MI, Buttner J, Galassi AR, Schofer J, Werner G, Lefevre T, Louvard Y, Serruys PW, Reifart N. European experience with the retrograde approach for the recanalisation of coronary artery chronic total occlusions. A report on behalf of the euroCTO club. *EuroIntervention* 2008;4:84-92.
- [75] Sirnes PA, Golf S, Myreng Y, Mølstad P, Emanuelsson H, Albertsson P, Brekke M, Mangschau A, Endresen K, Kjekshus J. Stenting in Chronic Coronary Occlusion (SICCO): a randomized, controlled trial of adding stent implantation after successful angioplasty. *J Am Coll Cardiol*. 1996 Nov 15; 28(6): 1444-51.
- [76] Buller CE, Teo KK, Carere RG. Three year clinical outcomes from the Total Occlusion Study of Canada (TOSCA). *Circulation* 2000; 102:II-1885.
- [77] Lotan C, Rozenman Y, Hendler A, Turgeman Y, Ayzenberg O, Beyar R, Krakover R, Rosenfeld T, Gotsman MS. Stents in total occlusion for restenosis prevention. The multicentre randomized STOP study. The Israeli Working Group for Interventional Cardiology. *Eur Heart J*. 2000 Dec;21(23):1960-6.
- [78] Sievert H, Rohde S, Utech A, Schulze R, Scherer D, Merle H, Ensslen R, Schröder R, Spies H, Fach A. Stent or angioplasty after recanalization of chronic coronary occlusions? (The SARECCO Trial). *Am J Cardiol*. 1999 Aug 15;84(4):386-90.
- [79] Hoye A, Tanabe K, Lemos PA et al. – Significant reduction in restenosis after the use of sirolimus-eluting stents in the treatment of chronic total occlusions. *J Am Coll Cardiol* 2004; 43, 1954-1958.
- [80] Werner GS, Krack A, Schwarz G et al. – Prevention of lesion recurrence in chronic total coronary occlusions by paclitaxel-eluting stents. *J Am Coll Cardiol* 2004; 44, 2301-2306.
- [81] Nakamura S, Muthusamy TS, Bae JH et al. – Impact of sirolimus-eluting stent on the outcome of patients with chronic total occlusions. *Am J Cardiol* 2005; 95, 161-166.
- [82] Werner GS, Schwarz G, Prochnau D et al. – Paclitaxel-eluting stents for the treatment of chronic total coronary occlusion: a strategy of extensive lesion coverage with drug-eluting stents. *Catheter Cardiovasc Interv* 2005; 67, 1-9.
- [83] Abizaid A, Chan C, Lim YT, Kaul U, Sinha N, Patel T, Tan HC, Lopez-Cuellar J, Gaxiola E, Ramesh S, Rodriguez A, Russell ME; WISDOM Investigators. Twelve-month outcomes with a paclitaxel-eluting stent transitioning from controlled trials to clinical practice (the WISDOM Registry). *Am J Cardiol*. 2006 Oct 15;98(8):1028-32.
- [84] Grube E, Biondi Zoccai G, Sangiorgi G et al. – Assessing the safety and effectiveness of TAXUS in 183 patients with chronic total occlusion: insights from the TRUE study. *Am J Cardiol* 2007; 96, 37H.
- [85] García-García HM, Daemen J, Kukreja N, Tanimoto S, van Mieghem CA, van der Ent M, van Domburg RT, Serruys PW. Three-year clinical outcomes after coronary stenting of chronic total occlusion using sirolimus-eluting stents: insights from the rapa-

- mycin-eluting stent evaluated at Rotterdam cardiology hospital-(RESEARCH) registry. *Catheter Cardiovasc Interv.* 2007 Nov 1;70(5):635-9.
- [86] Shen ZJ, García-García HM, Garg S, Onuma Y, Schenkeveld L, van Domburg RT, Seruys PW; Interventional Cardiologists at Thoraxcentre in 2000-2003. Five-year clinical outcomes after coronary stenting of chronic total occlusion using sirolimus-eluting stents: insights from the rapamycin-eluting stent evaluated at Rotterdam Cardiology Hospital-(Research) Registry. *Catheter Cardiovasc Interv.* 2009 Dec 1;74(7):979-86.
- [87] Ge L, Iakovou I, Cosgrave J, et al. Immediate and mid-term outcomes of sirolimus-eluting stent implantation for chronic total occlusion. *Eur Heart J* 2005;1056-62
- [88] Urban P, Gershlick AH, Guagliumi G, Guyon P, Lotan C, Schofer J, Seth A, Sousa JE, Wijns W, Berge C, Deme M, Stoll HP; e-Cypher Investigators. Safety of coronary sirolimus-eluting stents in daily clinical practice: one-year follow-up of the e-Cypher registry. *Circulation.* 2006 Mar 21;113(11):1434-41.
- [89] Lotan C, Almagor Y, Kuiper K, Suttorp MJ, Wijns W. Sirolimus-eluting stent in chronic total occlusion: the SICTO study. *J Interv Cardiol.* 2006 Aug;19(4):307-12.
- [90] Kandzari DE, Rao SV, Moses JW et al. Clinical and angiographic outcomes with sirolimus-eluting stents in total coronary occlusions. The ACROSS/TOSCA 4 (Approaches to Chronic Occlusions with Sirolimus-Eluting Stents/Total Occlusion Study of Coronary Arteries 4) trial. *J Am Coll Cardiol Intv* 2009; 2:97-106.
- [91] Galassi AR, Tomasello SD, Costanzo L, Campisano MB, Barrano G, Tamburino C. Long-term clinical and angiographic results of Sirolimus-Eluting Stent in Complex Coronary Chronic Total Occlusion Revascularization: the SECTOR registry. *J Interv Cardiol.* 2011 Oct;24(5):426-36.
- [92] Suttorp MJ, Laarman GJ, Rahel BM, Kelder JC, Bosschaert MA, Kiemeneij F, Ten Berg JM, Bal ET, Rensing BJ, Eefting FD, Mast EG. Primary Stenting of Totally Occluded Native Coronary Arteries II (PRISON II): a randomized comparison of bare metal stent implantation with sirolimus-eluting stent implantation for the treatment of total coronary occlusions. *Circulation.* 2006 Aug 29;114(9):921-8.
- [93] Van den Branden BJ, Rahel BM, Laarman GJ, Slagboom T, Kelder JC, Ten Berg JM, Suttorp MJ. Five-year clinical outcome after primary stenting of totally occluded native coronary arteries: a randomised comparison of bare metal stent implantation with sirolimus-eluting stent implantation for the treatment of total coronary occlusions (PRISON II study). *EuroIntervention.* 2012 Feb;7(10):1189-96.
- [94] Reifart N, Hauptmann KE, Rabe A, Enayat D, Giokoglu K. Short and long term comparison (24 months) of an alternative sirolimus-coated stent with bioabsorbable polymer and a bare metal stent of similar design in chronic coronary occlusions: the CORACTO trial. *EuroIntervention.* 2010 Aug;6(3):356-60.

- [95] Hoye A, Ong ATL, Aoki J, et al. Drug-eluting stent implantation for chronic total occlusions: comparison between the sirolimus- and paclitaxel-eluting stent. *Eurointervention* 2005;1:193-7.
- [96] Jang JS, Hong MK, Lee CW, Park DW, Lee BK, Kim YH, Han KH, Kim JJ, Park SW, Park SJ. Comparison between sirolimus- and Paclitaxel-eluting stents for the treatment of chronic total occlusions. *J Invasive Cardiol*. 2006 May;18(5):205-8.
- [97] Lezo JS, Medina A, Pan M et al. Drug eluting stents for the treatment of chronic total occlusion: a randomized comparison of rapamycin versus paclitaxel-eluting stents. *Circulation* 2005; 112 (suppl) II-477. Abstract.
- [98] Nakamura S, Bae JH, Cahyadi YH, Udayachalerm W, Tresukosol D, Tansuphaswadi-kul S. Drug-Eluting Stents for the Treatment of Chronic Total Occlusion: A Comparison of Serial Angiographic Follow-Up with Sirolimus, Paclitaxel, Zotarolimus and Tacrolimus-Eluting Stent: Multicenter Registry in Asia. *Circulation*. 2008;118:S-737. Abstract.
- [99] Suttorp MJ, Laarman GJ; PRISON III study investigators. A randomized comparison of sirolimus-eluting stent implantation with zotarolimus-eluting stent implantation for the treatment of total coronary occlusions: rationale and design of the PRImary Stenting of Occluded Native coronary arteries III (PRISON III) study. *Am Heart J*. 2007; 154:432-5.
- [100] Moreno R, Garcia E, Teles RC, Almeida MS, Carvalho HC, Sabate M, Martin-Reyes R, Rumoroso JR, Galeote G, Goicolea FJ, Moreu J, Mainar V, Mauri J, Ferreira R, Valdes M, Perez de Prado A, Martin-Yuste V, Jimenez-Valero S, Sanchez-Recalde A, Calvo L, Lopez de Sa E, Macaya C, Lopez-Sendon JL. A randomised comparison between everolimus-eluting stent and sirolimus-eluting stent in chronic coronary total occlusions. Rationale and design of the CIBELES (non-acute Coronary occlusion treated by everoLimus-Eluting Stent) trial. *EuroIntervention*. 2010 May;6(1):112-6.
- [101] Moussa I, Moses J, Di Mario C, et al. Does the specific intravascular ultrasound criteria used to optimize stent expansion have an impact on the probability of stent restenosis? *Am J Cardiol* 1999; 83: 1012–1017.
- [102] Russo RJ, Attubato MJ, Davidson CJ, et al. Angiography versus intravascular ultrasound-directed stent placement: Final results from AVID. *Circulation* 1999;100(Suppl. 1):I234
- [103] Fitzgerald PJ, Oshima A, Hayase M, et al. Final results of the Can Routine Ultrasound Influence Stent Expansion (CRUISE) study. *Circulation* 2000; 102: 523–530.
- [104] Moses JW, Leon MB, Popma JJ, et al. Sirolimus-eluting stents versus standard stents in patients with stenosis in a native coronary artery. *N Engl J Med* 2003; 349: 1315–1323.
- [105] Stone GW, Ellis SG, Cox DA, et al. A polymer-based paclitaxel-eluting stent in patients with coronary artery disease. *N Engl J Med* 2004; 350: 221–231.

- [106] Iakovou I, Schmidt T, Bonizzoni E, et al. Incidence, predictors, and outcome of thrombosis after successful implantation of drug-eluting stents. *JAMA* 2005; 293: 2126–2130.
- [107] Takebayashi H, Mintz GS, Carlier SG, et al. Nonuniform strut distribution correlates with more neointimal hyperplasia after sirolimus-eluting stent implantation. *Circulation* 2004; 110: 3430–3434.
- [108] Brodie BR, Cooper C, Jones M, Fitzgerald P, Cummins F: for the Postdilatation Clinical Comparative Study (POSTIT) Investigators. Is adjunctive balloon postdilatation necessary after coronary stent deployment? final results from the POSTIT Trial. *Cathet Cardiovasc Interv* 2003; 59:184–192
- [109] Schaub F, Theiss W, Bush R, et al. Management of 219 consecutive cases of post-catheterization pseudoaneurysm. *J Am Coll Cardiol* 1997; 30: 670-5.
- [110] Ellis SG, Ajluni S, Arnold AZ et al. Increased coronary perforation in the new device era. Incidence, classification management and outcome. *J Am Coll Cardiol* 1994; 90: 409-414.
- [111] Javaid A, Buch AN, Satler LF, Kent KN, Suddath WO, Lindsay J, Pichard AD, Waksman R. Management and outcomes of coronary artery perforation during percutaneous coronary intervention. *Am J Cardiol* 2006; 98: 911–914.
- [112] Fejka M, Dixon SR, Safian RD, *et al.* Diagnosis, management, and clinical outcome of cardiac tamponade complicating percutaneous coronary intervention. *Am J Cardiol* 2002; 90: 1183-6.
- [113] Fasseas P, Orford JL, Panetta CJ, *et al.* Incidence, correlates, management, and clinical outcome of coronary perforation: analysis of 16298 procedures. *Am Heart J* 2004; 147: 140-5.
- [114] Han Y, Wang Si, Jing QL, Zhang J, Ma Y, Luan B. Percutaneous coronary intervention for chronic total occlusion in 1263 patients: a single-center report. *Chinese Medical Journal* 2006; 119:1165-1170.
- [115] Stankovic G, Orlic D, Corvaja N, *et al.* Incidence, predictors, in-hospital, and late outcomes of coronary artery perforations. *Am J Cardiol* 2004; 93: 213-6.
- [116] Tobis J. *Technique in coronary artery stenting*. London: Martin Dunitz; 2000.
- [117] Briguori C, Di Mario C, De Gregorio J, Sheiban I, Vaghetti M, Colombo A. Administration of protamine after coronary stent deployment. *Am Heart J* 1999;138:64–68.
- [118] Cosgrave J, Qasim A, Latib A, Aranzulla TC, Colombo A. Protamine usage following implantation of drug eluting stents: a word of caution. *Cathet Cardiovasc Interv* 2008; 71:913-914.
- [119] Tun ZG, Campbell CA, Gottimukalla MV, Kloner RA. Preservation of distal coronary perfusion during prolonged balloon inflation with an autoperfusion angioplasty catheter. *Circulation* 1987, 75: 1273-80.

- [120] Sundram P, Harvey JR, Johnson RG, Schartz MJ, Bairn DS. Benefit of perfusion catheters for emergency coronary artery grafting after failed percutaneous transluminal angioplasty. *Am J Cardiol* 1989; 63:5 282-5.
- [121] Dippel EJ, Kereiakes DJ, Tramuta DA, et al. Coronary perforation during percutaneous coronary intervention in the era of abciximab platelet glycoprotein IIb/IIIa blockade: an algorithm for percutaneous management. *Catheter Cardiovasc Interv* 2001; 52:279-86.