

## Chapter

# The Importance of Lead Positioning to Improve Clinical Outcomes in Cardiac Resynchronization Therapy

*Mirela-Anca Stoia, Sabina Istratoaie, Sorin Pop, Florin Anton, Sorin Crisan and Dan Blendea*

## Abstract

Left ventricular (LV) lead positioning is one of the main contributors to the cardiac resynchronization therapy (CRT) response. Conventional left ventricular (LV) lead implantation faces several difficulties, which may ultimately affect lead stability and performance. Several imaging techniques have been proposed to overcome all these obstacles including multimodality cardiac imaging to help in preprocedural or intraprocedural identification of the latest activated areas of the LV. Emerging pacing strategies like LV multisite and multipoint pacing may help deliver an enhanced response to CRT, but prospective trials are warranted to confirm the superiority of this approach.

**Keywords:** cardiac resynchronization therapy, left ventricular lead implant, coronary sinus, coronary venous tree, left bundle branch block

## 1. Introduction

Cardiac resynchronization therapy (CRT) exerts its physiological effect by restoring the atrioventricular, interventricular, and intraventricular synchronicity. This in turn results in an enhancement in pumping efficiency. In addition, CRT leads to an improved left ventricular (LV) filling and, in some cases, a reduction in the mitral regurgitation. The beneficial effects of CRT translate in a majority of patients in an improved quality of life, increased exercise capacity, reduction in hospitalization for heart failure, and reduction in overall mortality [1–3].

In spite of all these advantages, a substantial minority (approximately 30%) of patients treated with CRT do not show clinical improvement [3, 4]. The reasons for non-response to CRT include: lack of LV dyssynchrony, non-optimal position of the LV pacing lead, high-myocardial scar burden, and suboptimal device programming [5–10].

Given these considerations, the aim of this chapter was to review the different strategies of lead placement for CRT and their effect on clinical outcomes.

## 2. Coronary venous anatomy

### 2.1 The structure of the coronary venous tree

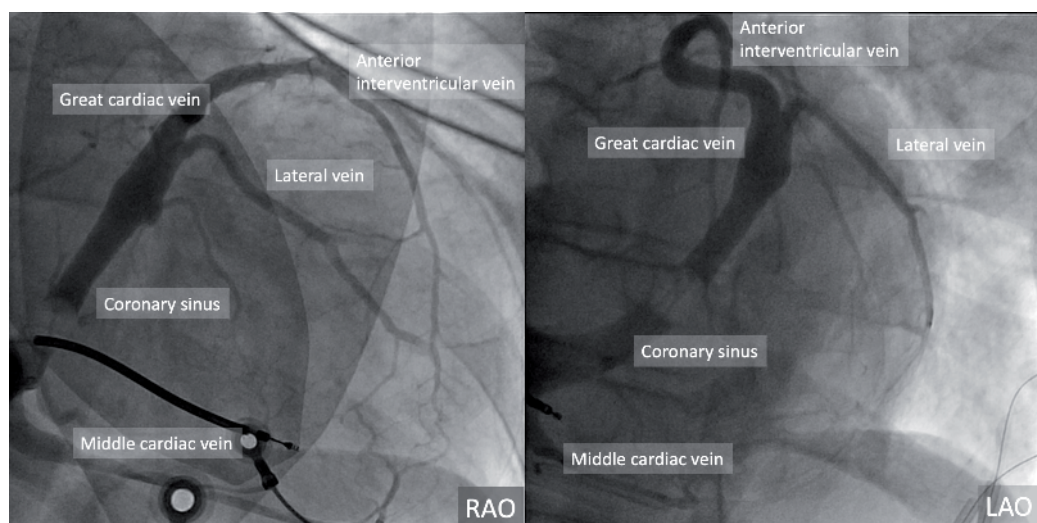
Lead positioning for CRT depends to a great extent on the coronary venous anatomy, which indirectly can impact outcomes of cardiac resynchronization.

The coronary sinus (CS) is a venous conduit situated in the vicinity of the left atrioventricular (AV) groove, which continues the great cardiac vein (GCV) and empties into the right atrium (**Figure 1**) [11]. Although the CS is a constant landmark vein, its length and diameter are highly variable. The diameter of the CS varies between 6 and 16 mm, while the diameter at its right atrial ostium can be from 5 to 20 mm. Its length can vary from 2 to 5 cm [11]. The major tributaries entering the CS-GCV are the anterior interventricular vein (AIV), the middle cardiac vein (MCV), the left marginal veins, and the posterolateral vein of the LV.

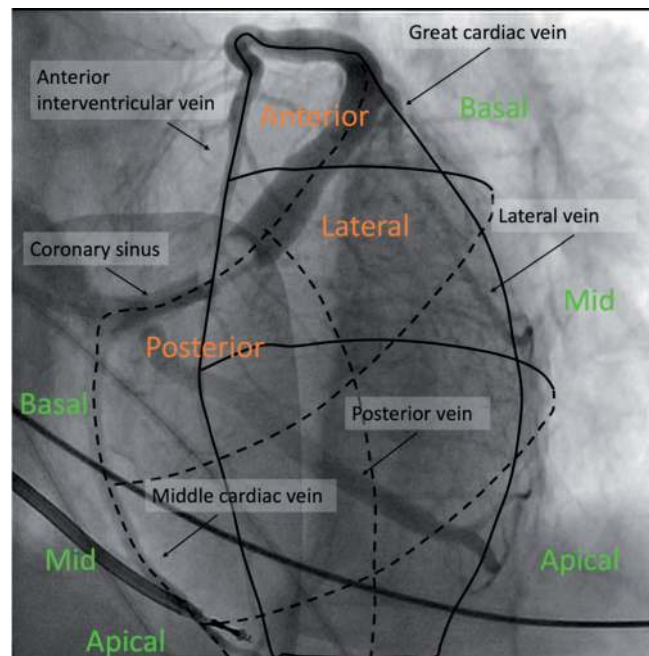
The AIV ascends in the anterior interventricular sulcus adjacent to the left anterior descending coronary artery from the apex toward the base of the heart. It then courses laterally at the base of the heart, along the left atrioventricular groove to form the GCV. This vein drains blood from the apical region of the heart, the anterior surfaces of both ventricles, and the anterior interventricular septum and parts of the left atrium [11]. The MCV travels along the inferior region of the heart, in the posterior interventricular groove, parallel to the posterior descending coronary artery [11]. The MCV drains the inferior walls of the ventricles, as well as the apical area and the posterior two-thirds of the septum. With an average diameter of 4 mm, the MCV empties into the CS near its right atrial ostium.

A more recent classification of the elements of the CS tree is the segmental approach, which, by establishing a correlation between venous tributaries and segments of the left ventricle, allows a more precise placement of the LV lead for enhancing cardiac synchrony [12]. The CS body is segmented along a horizontal axis, from the CS ostium to the anterior interventricular groove into three equal zones (**Figure 2**).

Branches originating in each segment are labeled posterior, lateral, or anterior segmental branches. The LV is divided along the longitudinal axis into three equal segments: basal, mid, and apical. The length of the first-degree tributaries and the position of the second-degree tributaries were defined according to these segments.



**Figure 1.**  
*The coronary venous tree as seen on a rotational angiogram.*



**Figure 2.** Coronary venogram in the LAO view illustrating the segmental approach to venous anatomy. From the base to the apex, the heart is divided along the long axis into basal, mid, and apical segments. In this LAO projection, branches originating in each segment were labeled posterior, lateral, or anterior segmental branches. The length of the first-degree tributaries and the position of the second-degree tributaries were defined according to these segments.

This segmentation scheme also promotes potential optimization of the positioning of the LV lead along the lateral walls, framed by the network of second- and third-order branches—optimization that becomes necessary in the absence of a suitable first-order segmental branch.

In most patients undergoing CRT, the target veins used for LV lead placement include the posterior, posterolateral, and marginal veins of the left ventricle. The number of left posterior veins may be from one to three, but usually, it is a single vein (60%). It empties into the CS in 75% of cases, but it can also terminate in the GCV. There are a few cases with no left posterior vein (5%), giving the place to the left marginal vein to drain the left ventricular posterolateral wall [11]. Usually, the left marginal vein is a tributary of the GCV (81%), but in approximately 19% of cases, it can drain directly into the CS. It is also named the obtuse marginal vein and drains much of the left ventricular myocardium.

## 2.2 Coronary venous imaging

The electrophysiologist should be aware of both the usual geometry of the coronary venous tree and also of the common variants and the alterations in geometry induced by the underlying cardiac pathology. A clear appreciation of these variations by a careful pre-implantation planning may help position the LV lead in an optimal position and thus allow for successful CRT. Methods used for preprocedural evaluation of CV anatomy include multislice computed tomography (CT) [13], electron beam CT, and the levophase of coronary angiography.

A major disadvantage for CT in evaluation for CRT lies in the fact that it cannot be repeated during interventions, its role being limited to preprocedural evaluation. Another limit may be the difficulty in visualizing second- and third-order tributaries, details that are of paramount importance in optimal placing of the LV lead.

The most commonly used method of imaging to facilitate the LV lead placement is intraprocedural CV angiography [11]. This technique requires cannulation of the coronary sinus, and a balloon occlusion catheter is placed in the proximal CS to impede the flow of blood. The contrast material is then injected to opacify the CV tree by retrograde filling, thus enabling the delineation of the venous anatomy in real time.

Standard coronary venous angiography (SCVA) defines coronary venous anatomy in two orthogonal static views that may lead to suboptimal delineation of the origin, angulations, and course of the venous tributaries. When compared to standard venography, high-speed rotational coronary venous angiography (RCVA) offers a multi-angle dynamic view of the CV tree, providing a three-dimensional perspective [11]. As described previously, RCVA uses a rapid 4-second isocentric rotation of the imaging camera over a 110° arc from a right anterior oblique 55° to left anterior oblique 55° [11]. The rotational images can then be reviewed over a full range of angles, providing the operator with a superior assessment regarding the coronary venous tree and its branches than standard images. RCVA showed promising steps toward obtaining the desired imaging quality, providing multiple visualization angles, allowing for better identification, separation, and delimitation of the CS tree, all orders of segmental branches, as well as a more precise estimation of the take-off and angulation of its tributaries.

### **2.3 Variability of coronary venous anatomy in patients undergoing cardiac resynchronization therapy**

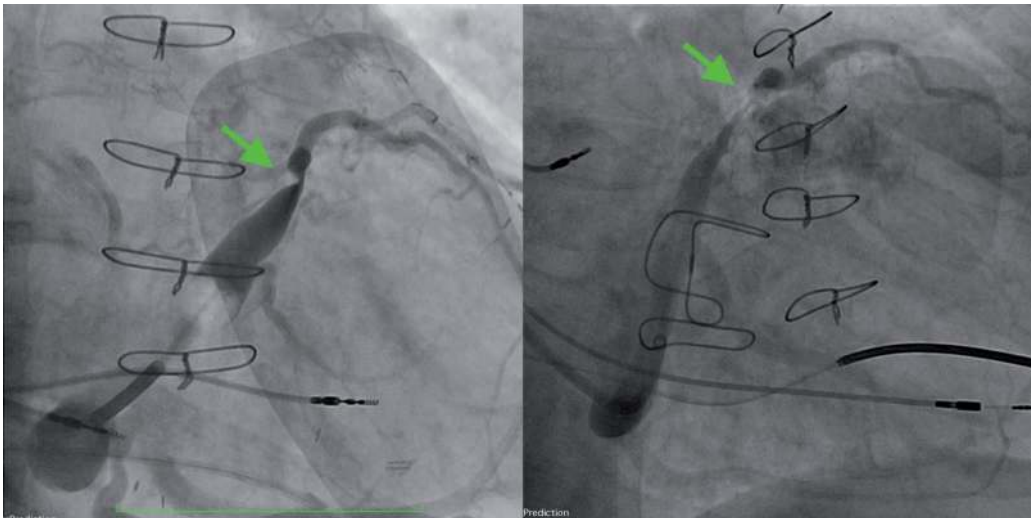
During LV lead placement, knowledge of CS variations in morphology is of paramount importance as it may assist in the selection of the guiding catheter, leading to a successful CRT. The following anatomical features are important for CS cannulation: the CS ostial angle, the posterior displacement of the CS, the decrease in diameter at the junction between CS and great cardiac vein (GCV), the presence of stenoses and aneurysmal dilatations.

The CS ostial angle is acute in patients with severe tricuspid regurgitation and is more obtuse in patients with larger left atrial size [14].

While the CS is typically displaced from the left coronary sulcus toward the left atrium wall, the displacement is significantly more pronounced in patients post coronary artery bypass grafting (CABG) [15]. This, in turn, affects the shape of the GCV, accentuating its tortuosity, and thus, slowing or potentially stopping the advancement of the CS catheter during LV lead implant. Another potential obstruction of the CS cannulation may occur around the CS-GCV junction, in the form of a sudden diameter reduction in the area where the vein of Marshall takes off from the CS, as the latter continues as the GCV. The decrease in diameter of the vessel post junction appears to be greater in patients post CABG [15]. The intervention seems to also affect the probability of encountering stenoses and aneurysmal dilatations of the CS, which are encountered in 5–10% of cases, predominantly post CABG (**Figure 3**).

Current practice involves LV lead placement targeting mainly posterior or lateral veins. Indeed, a study that analyzed RVCA images of 51 patients undergoing CRT reported successful identification of lateral veins in 91% of the patients and posterior veins in 76% of cases [11]. However, in terms of suitability for LV lead placement, characteristics such as diameter and take-off angles render many of the identified branches suboptimal for implant. Both posterior and lateral veins were tortuous in 15–30% of the patients undergoing CRT implant [11].

Another factor affecting the placement of the LV lead is the presence of myocardial scar from prior myocardial infarctions (MIs). In a study by van de Veire et al., it



**Figure 3.**  
*Coronary sinus-great cardiac vein stenoses (green arrows) in patients with prior coronary artery bypass grafting.*

was shown that patients with a history of myocardial infarction (MI) are less likely to CS tributaries in the segments with scar [13].

### 3. Electrical activation of the failing heart

#### 3.1 Electrical activation in patients with left bundle branch block

Left bundle branch block (LBBB) can be associated with conduction delay located at several anatomic levels in the conduction system from the distal His bundle to the left bundle branch and further distally to the arborization of the left bundle branch system [3]. In patients with LBBB and heart failure, the first ventricular site to be activated is the right ventricular (RV) free wall. The activation then proceeds to the right septum, and the latest RV site to be activated is the posterobasal region [16]. The first sites of the LV to be activated vary, but, most often these are located in the apical septum, and more rarely in the septobasal or midseptal region or in the anterior wall [17, 18]. In most patients, the activation spreads around the apex and across the inferior wall, in a “U-shaped” pattern, and reaches the anterolateral wall of the LV and then progresses toward the basal posterior or posterolateral wall [3, 17, 18].

The endocardial activation encompasses about 75% of the duration of the QRS complex [16]. The rest of the QRS is represented by the activation of the mid-myocardium and epicardium [3, 18].

#### 3.2 The electrical activation during CRT

During CRT, the RV and LV pacing leads generate two ventricular activation wavefronts, which move toward each other. If pacing is delivered with a sufficiently short AV delay, the left and right ventricular wavefronts merge before the intrinsic activation, conducted from the atria via the AV node, descends to the ventricles [3, 18–21]. The RV is depolarized entirely or almost entirely by the wavefront generated by the RV lead. The LV is activated from two sites: one situated in the interventricular septum initiated by the RV lead, and the other one situated onto the epicardial surface of the lateral LV initiated by the LV lead [17, 20, 22, 23].

## 4. Lead placement for cardiac resynchronization therapy

### 4.1 LV anatomical positioning: interlead distance

In order to implant an LV pacing lead via a transvenous approach, the CS is cannulated and the LV lead is advanced toward a second- or third-order branch of the CS situated preferably on the anterolateral, lateral, posterior, or posterolateral LV wall (**Figure 4**) [3, 10, 15, 18, 23].

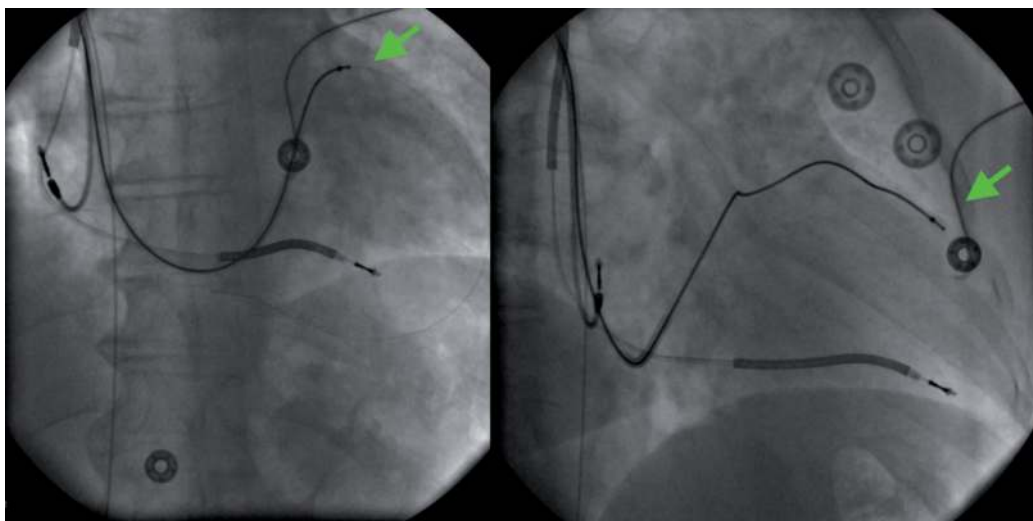
Achieving maximal anatomical and electrical separation between the right and left ventricular leads [23] may have a beneficial impact on clinical outcomes [10, 18].

The significance of the anatomical interlead distance (**Figure 5**) was emphasized by Heist and colleagues [24] in a study on 51 consecutive patients referred for CRT. The Delta dp/dt value, measured by echo-Doppler, related to acute hemodynamic improvement was correlated with the corrected direct LV-RV horizontal interlead tips distance measured on postprocedural lateral radiographs. Acute hemodynamic responders to CRT (Delta dP/dt >25%) had higher corrected interlead distance on the lateral film in comparison with non-responders. The interlead distance was found to be a useful anatomic parameter to help in guiding the lead placement on LV and RV sites in order to optimize CRT outcomes [24].

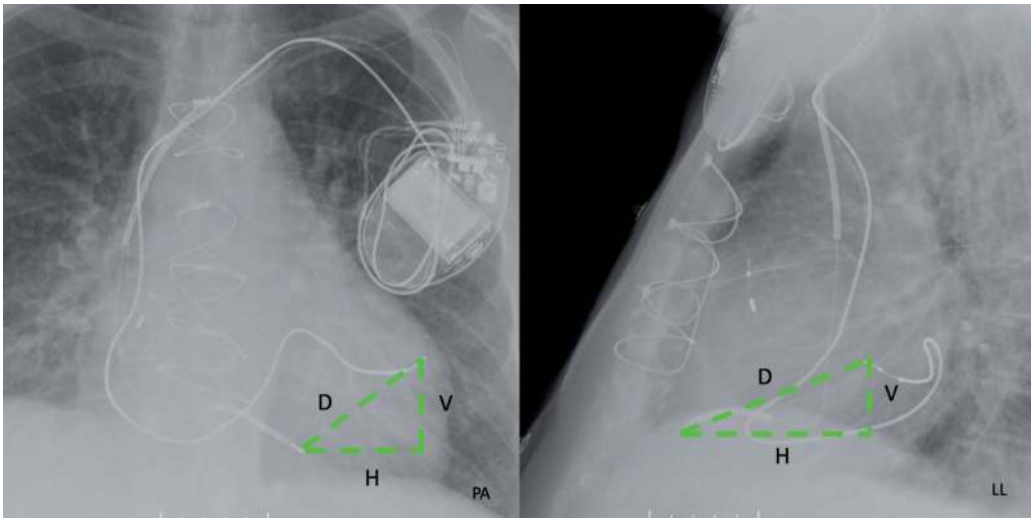
### 4.2 Anatomical positioning: segmental pacing site

A commonly used CRT strategy involves the placement of the LV lead in an anatomically favorable position [25]. The usually targeted zones for LV lead implant are the basal to mid, lateral, or posterolateral LV areas, due to their most delayed onset of activation in patients with typical LBBB [25]. There is a general agreement that an apical lead position is less favorable [9, 26]. This was also shown in the Multicenter Automatic Defibrillator Implantation Trial-Cardiac Resynchronization Therapy (MADIT-CRT) [27].

Regarding the non-apical positions, the results in the literature are not always concordant. The REsynchronization reVERses Remodeling in Systolic Left vEntricular Dysfunction (REVERSE HF) trial revealed better outcomes with lateral lead placement [25, 28], while in the Comparison of Medical Therapy, Pacing, and



**Figure 4.** Over-the-wire advancement of a left ventricular pacing lead into an anterolateral branch of the coronary sinus with final placement into a mid-ventricular segment.



**Figure 5.**  
*Measurement of the interlead distance on the posteroanterior (PA) and lateral (LL) chest radiograph. D = interlead distance; H = horizontal dimension; V = vertical dimension.*

Defibrillation in Heart Failure (COMPANION) trial and MADIT-CRT trial, the anterior, lateral, and posterior lead locations had comparable CRT outcomes [1].

Studies focused as well on a standardized anatomical positioning of LV lead implant according to its segmentation [12]. In the study by Merchant and colleagues [9], event-free survival was significantly lower in the patients with apical LV pacing, independent of clinical covariates. The apical group also demonstrated less improvement in NYHA functional class and less LV reverse remodeling. These data suggest that apical LV lead placement is associated with worse CRT outcomes and preferential positioning of LV leads in the basal/midventricle segments would be a choice in order to improve the outcomes. These results were also highlighted in a substudy analysis of the MADIT-CRT study [25, 29].

These observations have several potential explanations. Firstly, the LV depolarization wavefront in most conduction disturbances propagates from the apex to midventricle and last to the basal regions of the heart, which are the latest to be activated. Secondly, the main CRT objective is to synchronize the ventricles by electrical stimulation from RV and LV pacing sites, which ideally should be situated as far as possible from each other. An apically positioned LV lead is situated in the proximity of RV lead which results in reduced inter-electrode distance and inter-lead electrical separation, with unfavorable effects on heart failure evolution [18].

Besides anatomic segmental pacing position, shorter AV delays seem to increase the efficiency of LV apical pacing, as was shown in the article by Verbeek et al. [19]. Working on animal model, they demonstrated that LV function was optimized by using AV delays shorter than the baseline PQ time LV and BiV interconnected pacing, by excluding endogenous LV activation so far [18].

### 4.3 Maximum electrical delay

For an optimal result with cardiac resynchronization, it is necessary to detect the latest activated regions of LV, where the pacing lead should be preferably placed, resulting in LV hemodynamic improvements [18]. These LV areas of interest could be revealed by several invasive and non-invasive imaging techniques. One proposition was to use the intraprocedural measurement of the LV lead electrical delay

(LVLED), representing the calculated time between onset of the QRS on the surface ECG and the sensed signal on the LV lead (Q-LV) (**Figure 6**).

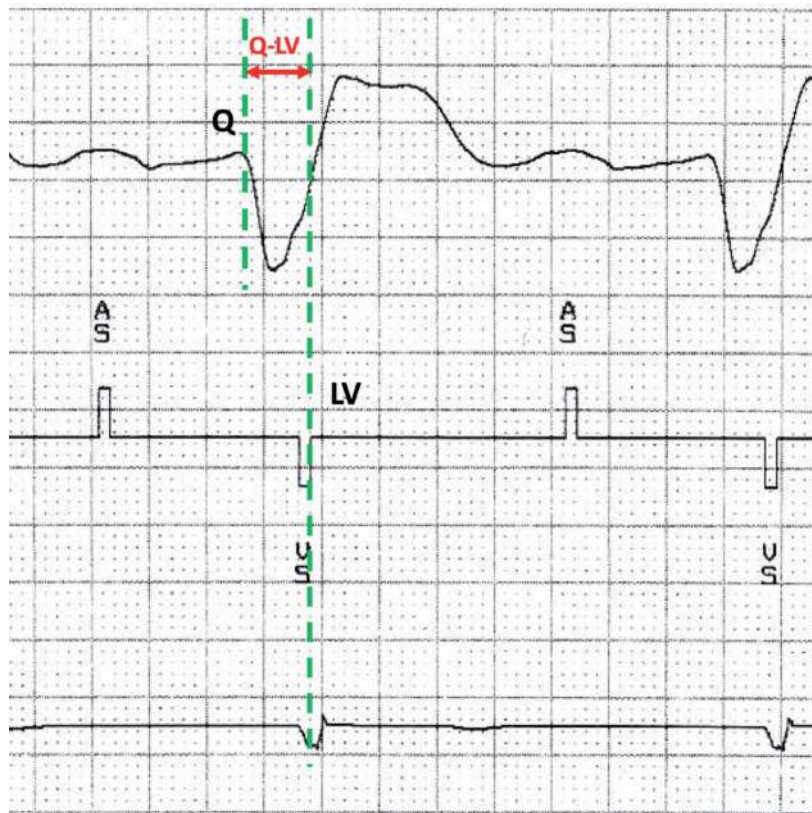
This delay is corrected for the baseline QRS (recorded simultaneously) by expressing it as a percentage of the baseline QRS duration (Q-LV/QRS duration ratio) [10].

Long LV lead electrical delays are linked with LV hemodynamic improvements, while shorter than 50% of LV lead electrical delays correlate with a worse clinical scenario [10, 18].

Both anatomic interlead separation and the LV electrical delay have been correlated with clinical outcomes following CRT in a study of Merchant and colleagues [9, 18]. They studied 61 consecutive patients undergoing CRT for standard clinical indications and found a positive correlation between corrected LVLED and horizontal interlead distance on lateral chest X-ray, and a negative correlation between LVLED and vertical interlead distance on posteroanterior chest X-ray [9, 18]. That inverse relationship has been transposed in a composite anatomic distance (defined as horizontal distance in lateral projection—vertical distance in PA projection), which correlated most closely with LVLED. These data suggest that LV-right ventricular interlead distance and LVLED appear to synergistically combine anatomic and electrical parameters for predicting LV anatomic reverse remodeling and optimizing them means improving CRT outcomes [9, 18].

A retrospective study of Heist et al. that used a model that included anatomic, hemodynamic, and electrical data was able to accurately predict 12-month event-free survival [30].

Efforts are being made to further define the importance of the electrical delay strategy in implanting the LV lead. ENHANCE CRT is a trial that aims to compare



**Figure 6.** Measurement of the Q-LV interval from the beginning of the QRS complex to the sensed electrogram on the left ventricular lead channel.



LV lead placement based on the electrical delay (Q-LV) with conventional implant in patients with non-LBBB [25, 31].

#### **4.4 Maximum mechanical delay**

Imaging techniques like tissue-Doppler, strain imaging, two-dimensional speckle-tracking imaging echocardiography, and tagged magnetic resonance imaging made possible identification of the latest activated segments of the LV [3, 6, 32, 33].

In a study on patients with heart failure undergoing CRT, that aimed to delineate the effects of CRT on LV performance, Ansalone et al. correlated the LV lead position with the site of the most mechanically delayed segment [6]. It was considered as concordance between LV pacing site and the most delayed area, when the LV lead was implanted in the region with the greatest regional mechanical delay as assessed by tissue Doppler. The results revealed that 42% of the patients were paced at a concordant site and showed the greatest improvements in clinical status and LV performance [3, 6].

A study evaluating the role of speckle-tracking echocardiography, an imaging modality that allows a more precise evaluation of the mechanical activation of different LV segments, revealed that LV lead implantation on the site of latest mechanical activation provided improvements in echocardiographic response after 6 months of CRT and better prognosis during long-term follow-up [33, 34].

Another study that assessed the impact of targeted LV lead placement using speckle-tracking echocardiography was the randomized targeted left ventricular lead placement to guide cardiac resynchronization therapy (TARGET) [35]. In the TARGET group of this study, the LV lead was positioned at the latest site of peak contraction with amplitude of 10% or greater to signify freedom from scar, while in the control group patients underwent standard CRT. When compared with controls, TARGET patients had a higher rate of lead concordance (lead placed at the most delayed LV segment) and higher rates of clinical response [35].

In the Speckle Tracking Assisted Resynchronization Therapy for Electrode Region (STARTER study), the concordance of LV lead with latest site was associated with an improvement in event-free survival [25, 36].

Summarizing the data available, there is no gold standard defined yet for selection of the optimal LV pacing segment and determination of the optimal pacing site could depend on input from several imaging modalities including image fusion strategies [25].

## **5. Emerging left ventricular pacing strategies**

### **5.1 Endocardial pacing**

During the electrical activation of epicardial pacing, the direction of pacing impulse is inverted, and that perturbation could become pro-arrhythmic. In this respect, endocardial biventricular pacing appears more physiological with the electrical impulse generated from endocardium and dissipated to epicardium [19]. The endocardial placement of LV lead is easier and without the restrictions of the coronary venous anatomy. Moreover, phrenic nerve stimulation could be often avoided, through the liberty to choose from multiple point LV lead positioning. The comparison with epicardial biventricular pacing seems to give encouraging results [19, 37–39].

Jais et al. [39] demonstrated that LV endocardial pacing is feasible. Other subsequent reports noticed improvement in clinical and of LV systolic function parameters [37, 40–43].

In an animal study on dogs with experimental LBBB, Van Deursen and colleagues [41] used pacing leads positioned in the right atrium, right ventricle, and at paired epicardial and endocardial LV sites. The endocardial biventricular pacing improved the electrical resynchronization and increased the benefit on  $LVdP/dt_{max}$  and stroke work by 90 and 50%, respectively, as compared with conventional epicardial approach [3]. Endocardial pacing seems not to be associated with the significant transmural dispersion of repolarization, often seen in epicardial procedures, and this in turn reduces the arrhythmogenic potential of CRT.

Another study that evaluated endocardial biventricular pacing [42] patients with ischemic cardiomyopathy revealed that endocardial biventricular pacing improved  $dP/dt(max)$  when compared with right ventricular apical pacing in all patients. In patients with pre-existing CS leads, LV endocardial pacing at the best endocardial site exceeded that achieved with the pre-implanted CRT device (using epicardial pacing via the existing CS lead). Optimal pacing sites were found to be located in LV segments outside from the postinfarct zone. The findings of this research suggest that CRT implanted at the best LV endocardial sites seems to be more effective than conventional CS lead epicardial pacing.

There are potential safety issues related to LV endocardial pacing such as thromboembolic complications or infection of the endocardial pacing lead [38]. Therefore, anticoagulation is required with a proposed international normalized ratio anticoagulation level around 3.5–4.5 (similar to mechanical valvular prostheses) [38].

## **5.2 Multisite and multipoint pacing**

Another emerging LV pacing strategy is multisite pacing, which has been proposed as an alternative resynchronization strategy aimed at improving clinical and echocardiographic outcomes [44]. Triple-site pacing showed improved reverse remodeling and heart failure symptoms over a follow-up of 1 year, but implantation was shown to be difficult and the complication rate was higher than a standard approach [3, 45]. The Triple Resynchronization in Paced Heart Failure Patients (TRIP-HF) study of Leclercq et al. [44] compared the effects of triple-site versus dual-site biventricular pacing in 40 patients diagnosed with moderate-to-severe heart failure and permanent atrial fibrillation requiring cardiac pacing for slow ventricular rate. The results of this study showed that cardiac resynchronization therapy with one RV and two LV leads was associated with significantly more LV reverse remodeling than conventional biventricular stimulation.

Quadripolar leads renewed the interest in multipolar pacing. Pacing from the most proximal and distal individualized multipoint electrodes could lead to improved resynchronization [25, 46]. Multipoint pacing when compared with biventricular pacing was shown to be associated with improved ventricular systolic and diastolic parameters in an acute hemodynamic study [3, 47].

In a comparison between left ventricular endocardial, multisite, and multipolar epicardial pacing, the optimal pacing method was found to be individually specific, and on a group level, only endocardial pacing was superior to standard CRT from a hemodynamic standpoint [3, 48]. Within individuals, however, different methods of stimulation were found to be optimal, suggesting a need to tailor the pacing strategy to the underlying substrate [48].

Even though the results of multisite and multipoint pacing were not found to be consistently better than the conventional biventricular pacing modality, they remain an option for non-responders to conventional CRT, particularly for patients who have underlying myocardial scar and a more heterogeneous LV activation [49].

Further studies and prospective trials are warranted to help in identifying the subgroups of patients for whom the multisite pacing strategy provides clinical and hemodynamical results which are superior to standard CRT.

## 6. Conclusions

The last two decades have brought a multitude of technical developments in the field of CRT. However, the optimal strategy for left ventricular lead positioning, one of the most important factors that determine CRT outcomes, continues to remain poorly defined.

Anatomical positioning is currently the most frequently used LV lead implant strategy; however, several alternative approaches including targeting the most electrically or mechanically delayed region of the LV have been shown to be associated with superior CRT outcomes although the results have been variable. Further prospective studies are needed to better define a more reproducible and feasible technique for LV segment selection for CRT.

## Conflict of interest

None.

## Author details

Mirela-Anca Stoia<sup>1</sup>, Sabina Istratoaie<sup>1</sup>, Sorin Pop<sup>1</sup>, Florin Anton<sup>1</sup>, Sorin Crisan<sup>2</sup> and Dan Blendea<sup>1,3\*</sup>


<sup>1</sup> Emergency Clinical County Hospital, University of Medicine and Pharmacy “Iuliu Hatieganu”, Cluj-Napoca, Romania

<sup>2</sup> Municipal Clinical Hospital, University of Medicine and Pharmacy “Iuliu Hatieganu”, Cluj-Napoca, Romania

<sup>3</sup> Massachusetts General Hospital, Harvard Medical School, Boston, MA, USA

\*Address all correspondence to: [dblendea@me.com](mailto:dblendea@me.com)

## IntechOpen

© 2019 The Author(s). Licensee IntechOpen. This chapter is distributed under the terms of the Creative Commons Attribution License (<http://creativecommons.org/licenses/by/3.0>), which permits unrestricted use, distribution, and reproduction in any medium, provided the original work is properly cited. 

## References

- [1] Bristow MR et al. Cardiac-resynchronization therapy with or without an implantable defibrillator in advanced chronic heart failure. *The New England Journal of Medicine*. 2004;**350**(21):2140-2150
- [2] Cleland JG et al. The effect of cardiac resynchronization on morbidity and mortality in heart failure. *The New England Journal of Medicine*. 2005;**352**(15):1539-1549
- [3] Blendea D, Singh JP. Lead positioning strategies to enhance response to cardiac resynchronization therapy. *Heart Failure Reviews*. 2011;**16**(3):291-303
- [4] Abraham WT et al. Cardiac resynchronization in chronic heart failure. *The New England Journal of Medicine*. 2002;**346**(24):1845-1853
- [5] Ypenburg C et al. Noninvasive imaging in cardiac resynchronization therapy—Part 2: Follow-up and optimization of settings. *Pacing and Clinical Electrophysiology*. 2008;**31**(12):1628-1639
- [6] Ansalone G et al. Doppler myocardial imaging to evaluate the effectiveness of pacing sites in patients receiving biventricular pacing. *Journal of the American College of Cardiology*. 2002;**39**(3):489-499
- [7] Bleeker GB et al. Postero-lateral scar tissue resulting in non-response to cardiac resynchronization therapy. *Journal of Cardiovascular Electrophysiology*. 2006;**17**(8):899-901
- [8] Wilton SB et al. Relationship between left ventricular lead position using a simple radiographic classification scheme and long-term outcome with resynchronization therapy. *Journal of Interventional Cardiac Electrophysiology*. 2008;**23**(3):219-227
- [9] Merchant FM et al. Impact of segmental left ventricle lead position on cardiac resynchronization therapy outcomes. *Heart Rhythm*. 2010;**7**(5):639-644
- [10] Singh JP et al. Left ventricular lead electrical delay predicts response to cardiac resynchronization therapy. *Heart Rhythm*. 2006;**3**(11):1285-1292
- [11] Blendea D et al. Variability of coronary venous anatomy in patients undergoing cardiac resynchronization therapy: A high-speed rotational venography study. *Heart Rhythm*. 2007;**4**(9):1155-1162
- [12] Singh JP et al. The coronary venous anatomy: A segmental approach to aid cardiac resynchronization therapy. *Journal of the American College of Cardiology*. 2005;**46**(1):68-74
- [13] Van de Veire NR et al. Non-invasive visualization of the cardiac venous system in coronary artery disease patients using 64-slice computed tomography. *Journal of the American College of Cardiology*. 2006;**48**(9):1832-1838
- [14] Blendea D et al. Impact of tricuspid regurgitation and prior coronary bypass surgery on the geometry of the coronary sinus: A rotational coronary angiography study. *Journal of Cardiovascular Electrophysiology*. 2010;**21**(4):436-440
- [15] Blendea D, Altman RK, Singh JP. Procedural aspects of lead positioning for cardiac resynchronization therapy. *The Journal of Innovations in Cardiac Rhythm Management*. 2011;**2**:165-171
- [16] Rodriguez LM et al. Variable patterns of septal activation in patients with left bundle branch block and

- heart failure. *Journal of Cardiovascular Electrophysiology*. 2003;**14**(2):135-141
- [17] Auricchio A et al. Characterization of left ventricular activation in patients with heart failure and left bundle-branch block. *Circulation*. 2004;**109**(9):1133-1139
- [18] Ellenbogen KA, Auricchio A. American Heart Association. Pacing to Support the Failing Heart. AHA Clinical Series. Chichester, UK; Hoboken, NJ: Wiley-Blackwell; 2008. xiii. 347 p
- [19] Verbeek XA et al. Intra-ventricular resynchronization for optimal left ventricular function during pacing in experimental left bundle branch block. *Journal of the American College of Cardiology*. 2003;**42**(3):558-567
- [20] Jia P et al. Electrocardiographic imaging of cardiac resynchronization therapy in heart failure: Observation of variable electrophysiologic responses. *Heart Rhythm*. 2006;**3**(3):296-310
- [21] Lambiase PD et al. Non-contact left ventricular endocardial mapping in cardiac resynchronisation therapy. *Heart*. 2004;**90**(1):44-51
- [22] Prinzen FW, Spinelli JC, Auricchio A. Basic physiology and hemodynamics of cardiac pacing. In: Ellenbogen KA et al., editors. *Clinical Cardiac Pacing, Defibrillation, and Resynchronization Therapy*. Philadelphia PA, USA: Saunders; 2007. pp. 291-335
- [23] Singh JP et al. Dialing-in cardiac resynchronization therapy: Overcoming constraints of the coronary venous anatomy. *Journal of Interventional Cardiac Electrophysiology*. 2006;**17**(1):51-58
- [24] Heist EK et al. Radiographic left ventricular-right ventricular interlead distance predicts the acute hemodynamic response to cardiac resynchronization therapy. *The American Journal of Cardiology*. 2005;**96**(5):685-690
- [25] Roka A, Borgquist R, Singh J. Coronary sinus lead positioning. *Heart Failure Clinics*. 2017;**13**(1):79-91
- [26] Brignole M et al. ESC guidelines on cardiac pacing and cardiac resynchronization therapy: The task force on cardiac pacing and resynchronization therapy of the European Society of Cardiology (ESC). Developed in collaboration with the European Heart Rhythm Association (EHRA). *The European Heart Journal*. 2013;**34**(29):2281-2329
- [27] Singh JP et al. Left ventricular lead position and clinical outcome in the multicenter automatic defibrillator implantation trial-cardiac resynchronization therapy (MADIT-CRT) trial. *Circulation*. 2011;**123**(11):1159-1166
- [28] Linde C et al. Randomized trial of cardiac resynchronization in mildly symptomatic heart failure patients and in asymptomatic patients with left ventricular dysfunction and previous heart failure symptoms. *Journal of the American College of Cardiology*. 2008;**52**(23):1834-1843
- [29] Kutiyifa V et al. Left ventricular lead location and long-term outcomes in cardiac resynchronization therapy patients. *JACC: Clinical Electrophysiology*. Nov 2018;**4**(11):1410-1420
- [30] Heist EK et al. Usefulness of a novel “response score” to predict hemodynamic and clinical outcome from cardiac resynchronization therapy. *The American Journal of Cardiology*. 2006;**97**(12):1732-1736
- [31] Singh JP et al. Rationale and design for enhance CRT: QLV implant strategy for non-left bundle branch

block patients. *ESC Heart Fail.* 2018;**5**(6):1184-1190

[32] Lardo AC, Abraham TP, Kass DA. Magnetic resonance imaging assessment of ventricular dyssynchrony: Current and emerging concepts. *Journal of the American College of Cardiology.* 2005;**46**(12):2223-2228

[33] Ypenburg C et al. Optimal left ventricular lead position predicts reverse remodeling and survival after cardiac resynchronization therapy. *Journal of the American College of Cardiology.* 2008;**52**(17):1402-1409

[34] Becker M et al. Impact of left ventricular lead position on the efficacy of cardiac resynchronisation therapy: A two-dimensional strain echocardiography study. *Heart.* 2007;**93**(10):1197-1203

[35] Khan FZ et al. Targeted left ventricular lead placement to guide cardiac resynchronization therapy: The TARGET study: A randomized, controlled trial. *Journal of the American College of Cardiology.* 2012;**59**(17):1509-1518

[36] Saba S et al. Echocardiography-guided left ventricular lead placement for cardiac resynchronization therapy: Results of the speckle tracking assisted resynchronization therapy for electrode region trial. *Circulation. Heart Failure.* 2013;**6**(3):427-434

[37] Garrigue S et al. Comparison of chronic biventricular pacing between epicardial and endocardial left ventricular stimulation using Doppler tissue imaging in patients with heart failure. *The American Journal of Cardiology.* 2001;**88**(8):858-862

[38] van Gelder BM et al. Transseptal endocardial left ventricular pacing: An alternative technique for coronary sinus lead placement in cardiac

resynchronization therapy. *Heart Rhythm.* 2007;**4**(4):454-460

[39] Jais P et al. Mid-term follow-up of endocardial biventricular pacing. *Pacing and Clinical Electrophysiology.* 2000;**23**(11 Pt 2):1744-1747

[40] Garrigue S et al. Usefulness of biventricular pacing in patients with congestive heart failure and right bundle branch block. *The American Journal of Cardiology.* 2001;**88**(12):1436-1441, A8

[41] van Deursen C et al. Left ventricular endocardial pacing improves resynchronization therapy in canine left bundle-branch hearts. *Circulation. Arrhythmia and Electrophysiology.* 2009;**2**(5):580-587

[42] Spragg DD et al. Optimal left ventricular endocardial pacing sites for cardiac resynchronization therapy in patients with ischemic cardiomyopathy. *Journal of the American College of Cardiology.* 2010;**56**(10):774-781

[43] Bordachar P et al. Left ventricular endocardial stimulation for severe heart failure. *Journal of the American College of Cardiology.* 2010;**56**(10):747-753

[44] Leclercq C et al. A randomized comparison of triple-site versus dual-site ventricular stimulation in patients with congestive heart failure. *Journal of the American College of Cardiology.* 2008;**51**(15):1455-1462

[45] Rogers DP et al. A randomized double-blind crossover trial of triventricular versus biventricular pacing in heart failure. *European Journal of Heart Failure.* 2012;**14**(5):495-505

[46] Thibault B et al. Acute haemodynamic comparison of multisite and biventricular pacing with a quadripolar left ventricular lead. *Europace.* 2013;**15**(7):984-991

[47] Pappone C et al. Multipoint left ventricular pacing improves acute hemodynamic response assessed with pressure-volume loops in cardiac resynchronization therapy patients. *Heart Rhythm*. 2014;**11**(3):394-401

[48] Shetty AK et al. A comparison of left ventricular endocardial, multisite, and multipolar epicardial cardiac resynchronization: An acute haemodynamic and electroanatomical study. *Europace*. 2014;**16**(6):873-879

[49] Niederer SA et al. Biophysical modeling to simulate the response to multisite left ventricular stimulation using a quadripolar pacing lead. *Pacing and Clinical Electrophysiology*. 2012;**35**(2):204-214