
Developmental Dysplasia of the Hip in Childhood – Etiology, Diagnostics and Conservative Treatment

Ismet Gavrankapetanović and Adnan Papović

Additional information is available at the end of the chapter

<http://dx.doi.org/10.5772/67481>

Abstract

Since developmental dysplasia of the hip (DDH) represents one of the most common congenital deformations of the musculoskeletal system and the most common deformation of the hip joint, the aim is to emphasize the importance of early recognition and diagnosis of DDH as well as comprehensive screening among newborns. DDH represents a dynamic process that results in the action of a number of exogenous and endogenous factors, physiological and mechanical, exerted to the mother and to the child during pregnancy and after delivery. Summary of all current knowledge about the origin of this deformity suggests that the most important factors in the development are hard abdominal muscles and uterine muscles, as limiting factors for fetal movement, which prevents its physiological turn, and reinforces the pelvic presentation of the fetus in uterus. Considering the fact that developmental dysplasia of the hip demands multidisciplinary approach and cooperation among gynecologists, neonatologists, pediatricians, radiologists, and orthopedic surgeons, the goal of this chapter is to make a consensus about early conservative treatment among clinicians, time of commencement, and its efficacy.

Keywords: developmental dysplasia of the hip, conservative treatment, early commencement, hip ultrasonography, Risser traction, cast shorts

1. Introduction

Developmental dysplasia of the hip (DDH¹) represents the most common congenital deformation of the musculoskeletal system, ahead of the congenital talipes equinovarus and torticollis. Statistical data of the frequency of occurrence of this deformity in Bosnia and Herzegovina states that one of the forms of developmental dysplasia of the hip occurs in 3–5% of all births.

The data is probably not definitive and variable, and certainly depends on geographical distribution, the degree of health care education, the organization of the health care system and many other factors. Developmental dysplasia of the hip more often occurs in some countries and regions. In Bosnia and Herzegovina, the frequency rate of one of the forms of developmental dysplasia of the hip is the largest in the whole of Europe (Sweden 1.7, Bosnia and Herzegovina 75 on 1000 newborns). To what extent will they be recorded depends on the other two factors. Probably, only in economically developed countries, it is possible to implement an adequate screening method, thus adequately examine all newborn children, in order to identify hip deformities and start the treatment in the most appropriate period of time. In countries where the health care system is still in development, including Bosnia and Herzegovina, medical attention to possible occurrence of some form of developmental dysplasia of the hip is mainly directed toward the high risk groups. The great importance was previously given to the genetic nature of the DDH has been generally reduced. The reason lies in the fact that there are a large number of children with healthy hip genetically marked for DDH, but also a large number of children with malformed hips without a positive family history. The pelvic presentation of the fetus at birth, for most of the authors is considered the group at greatest risk.

DDH can be associated with other anomalies of the musculoskeletal system, first of all with torticollis, and foot deformities called *pes metatarsus congenitus varus*. The gender distribution shows that DDH occurs more often in female children than in male children with ratio of 4:1. According to some authors, the mildest form of this deformity is equally present in both sexes, while the more severe forms are more often presented in female children, with the left hip more often affected than the right, noting that serious forms are twice more frequent than most lenient.

For a long period, wandering in its search for names for all degrees of congenital deformities of the hip, speaks enough about the complexity of the pathoanatomical changes on the deformed hip. As the mechanism of DDH still remains unclear, for our purposes we will mainly use the knowledge gathered up to now. Thus, DDH represents a dynamic process that results in the action of a number of exogenous and endogenous factors, physiological and mechanical, exerted to the mother and to the child during pregnancy and after delivery. Therefore, we are talking about a multifactorial etiology of DDH. As a predisposing factor in the course of the development of deformity is a loose joint capsule. The mechanism of hip dislocation in children is consisted in the fact that in fetal pelvic presentation, hips are in maximal flexion and knees in maximal extension. The muscles of the posterior aspect of the upper leg cause an increased pressure of the proximal part of the femur on the articular capsule and the head gradually slipping from the acetabulum. Further progression of the deformity flow is accelerated in the postnatal period with traditional practices of diapering a child (with a cloth), present in our country, with maximum outstretched legs. The reason is that a newborn baby has a congenital flexion contracture of 15° caused by the intrauterine fetal position. Forced extension with shortened *m. iliopsoas* (this muscle is given a big role in the formation of DDH), leading formation of one of the forms of this deformity. The pathoanatomical substrate shows different degrees of deformity of joint elements. The head of the femur is due to cartilage material commonly deformed, and a degree of deformity varies from case to case. It is most commonly deformed from its back side, although cases are known when it is a normal, spherical shape [1].

2. Developmental dysplasia of the hip

Deformities of the femoral neck also depend on the moment of recognition of DDH, ranging from shortened neck with a slight ante version, and normal CD angle, to a significant shortening of the neck and greater ante version with a significant increase in CD angle. Analog to removal of the femoral head from the bottom of the acetabulum, comes the prolonging and thickening of *ligamentum teres capitis*. Depending on the degree of DDH, new changes are reflected on the acetabulum as well. In the mildest form of deformity, the acetabulum is shallow, the roof is steep, and the smallest part covers the head of the femur. When it comes to more severe deformities, subluxation or dislocations, acetabulum as a natural cavity, since empty, now tends to close, doing it by pulvinar and hypertrophic *ligamentum teres capitis*. The oval shape of a healthy acetabulum becomes triangular. Limbus in dysplastic hips becomes rounded, while in the luxated hips it is inverted and does not allow the luxated head of the femur bone to reposition in the acetabulum. The joint capsule is loose in each case and stretched. Because of the tendency of the femoral head to travel proximally, the joint capsule gets stretched from the front, and narrowed in the space between the femoral head and the acetabulum, due to effects of a hypertrophic and shortened *m. iliopsoas*. It advances along the outside of the iliac bone and gets a look of an 'hourglass.' This narrowing, the so called isthmus, with an inverted limbus creates an insurmountable obstacle with the luxated head of the femur to its repositioning. All of these changes in the joint elements do not pass the muscles around them. This primarily refers to adductor muscles and *m. iliopsoas*, which is shortened and hypertrophied.

All mentioned so far about developmental dysplasia of the hip (DDH) speaks to the fact that this is a dynamic process; thus, we are more assured in the knowledge that the recently adopted name can completely suppress the previously rigid 'congenital hip dislocation.' For this reason, even quite simple classification into three basic levels of deformity of the hip cannot meet our needs. For practical reasons, we will use the classification depending on the age of the child, because of the clinical presentation, diagnosis, and treatment options.

For the *newborn of 3 months old*, because of the characteristic clinical features, great possibilities of using ultrasound diagnostics, and limited possibility of using X-rays, following classification is used:

1. Loose hip: joint elements are positioned in satisfactory relation and we are not able to do a manual dislocation, but there is a significant stretching of soft tissues and ligaments, and the separation of the femoral head from the acetabulum.
2. Luxable hip: such hip where we can do a manual dislocation, joint elements are in a satisfactory relationship, but slack joint capsule and ligaments allow luxation, where the head of the femur spontaneously reduces when the pressure of the hand ceases.
3. Luxated hip: the head of the femur is out of the acetabulum, and repositioning is performed with Ortolani maneuver.

For *children older than 3 months*, following classification is used:

1. Displastic hip: joint bodies are in a satisfactory relationship, but acetabulum is shallow with a steep roof.
2. Subluxated hip: the head of the femur is only in partial contact with the outer part of the acetabulum.
3. Luxated hip: the head of the femur is located outside the acetabulum in the soft tissues.

2.1. Incidence

In about 60% of patients the left hip is affected, about 20% both, and the remaining 20% patients the right hip is affected. Although the cause of disease is found to be multifactorial, still there are certain conditions that can be extracted, characteristics of medical history and risks that show a significant correlation with the incidence of DDH:

1. ligament hyperlaxity;
2. increased femoral antetorsion;
3. decreased acetabular antetorsion;
4. intrauterine malposition;
5. positive family history;
6. firstborn;
7. sectio cesarea;
8. oligohydramnion;
9. gemini and multiple pregnancy;
10. female gender; and
11. more frequent reporting with following orthopedic diseases: metatarsus varus, pes calca-neovalgus, torticollis, plagiocephalia, extensor knee contracture.

2.2. Clinical presentation

Clinical examination of the newborn should comply with all instructions relating to the pediatric examination of the child, which means that the child should be examined in a warm room, the table covered with clean and dry diaper cloth, provided only for child examination. Access to child should be in accordance to its behavior, and examination should be carried out gently, but with firm movements. The child lies on its back; an examination should begin with maximum, but not forced extension of the hip and knee, pulling the foot while pushing the knees with your thumb. In doing so, first pay attention to the length of the limb, because shortening speaks for dislocations to abbreviated side. Further attention

should focus on the presence of gluteofemoral and gluteogenital skin creases, as well as folds in the thigh.

The asymmetry of the folds, even if it does not represent the 'Bade diagnostic sign' especially in the newborn, still speaks in favor of the possible occurrence of DDH. What follows in the examination is flexion of the hip and knee while closely observing the knees which are in healthy children in the same level, and in children with affected side causes the lowering of knee level. The examiner now places hands on the knees applying slight pressure in the axial direction. On the side of possible dislocation elastic hip plunging can be observed. Further examination is continued with characteristic posture of orthopedic hip examination in children. Palm of the examiner is placed on knees, thumb on the medial side of the thigh, and the other fingers on the lateral side where the tip of the middle finger is placed on the great trochanter. Hips of the child are flexed in 90°. We perform flexion and extension of the hip, with attention to the trochanter. 'The walking' of trochanter is a sign of its dislocation or luxation, sometimes with the phenomenon of squeaking of the femoral head against the hip, therefore we talk about the positive Hoffa's sign. Hips are further abducted. In newborns there is an abductor contracture of 45°, and in infants of 60°. Greater values of this abductor contracture are signs of either some form of DDH or hypertonus of the adductor muscles and *m. iliopsoas*.

The values of the abduction of more than 90°, or hyperabduction on the other hand, are a sure diagnostic sign of dislocation.

Characteristic positive signs in the diagnosis of DDH represent 'skipping signs,' Ortolani sign of reposition and Palmen luxation sign. The first is carried out in a manner that in the position of abducted hips, examiner's middle finger is putting a pressure on the femur head and with that pressure it is pushed forward. Dislocated head is pushed over the back edge of the acetabulum, where the examiner can feel the distinctive phenomenon of 'skipping' or 'clicking.' Palmen luxation leap is caused by the applied pressure on the knee in the axial direction with hips in adduction position.

In luxable hips one can feel the characteristic 'overriding phenomenon,' which is caused by the femur head crossing over the dysplastic acetabulum.

After removal of the pressure on the knee there is a spontaneous repositioning. This completes the orthopedic hips examination in children (**Figure 1**). It is important to note that certain diagnostic signs hold greater importance depending on the age of the child, so we distinguish clinical examination of newborns and infants. The value of Ortolani and Palmen sign decreases as child grows older. The reason for this lies in secondary changes in the bones and soft tissues in terms of shortening and hypertrophy of adductor muscles and *m. iliopsoas*. On the other hand, importance of asymmetric skin folds' findings of gluteofemoral and genitofemoral region increases. At the same time there can be noted limited abduction, which is an important diagnostic sign for DDH in older children. For older children, at walking age, there is a characteristic-waddling gait on luxated side, which indicates the positive Trendelburg sign. Compensatory, in order to maintain balance, the child leans the upper body to the burdened party, which is a positive sign of Duchenne. When mutual dislocations are a finding, there can be noted distinctive 'duck walk,' with increased lumbar lordosis. Further verification of the possible positive clinical diagnostic signs need to be done by ultrasound and X-ray diagnostics.

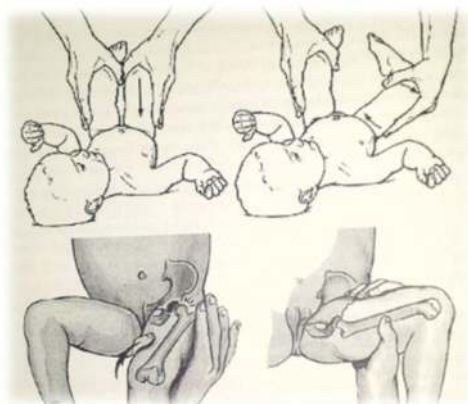


Figure 1. Two left images show Palmen test (provoked luxation), and two right images show Ortolani test (reposition of the luxated hip).

2.3. Diagnosis

According to all authors, ultrasound waves of 7.5 MHz frequency are completely harmless, which entails the conclusion that the ultrasound diagnosis of the hip disease in children is the most appropriate and harmless diagnostic way (**Figure 2**).

The method is simple and can be repeated. Among diagnostic methods, it is the preferred one, because it can give a diagnosis in the first days of life and refer us to the most appropriate treatment.

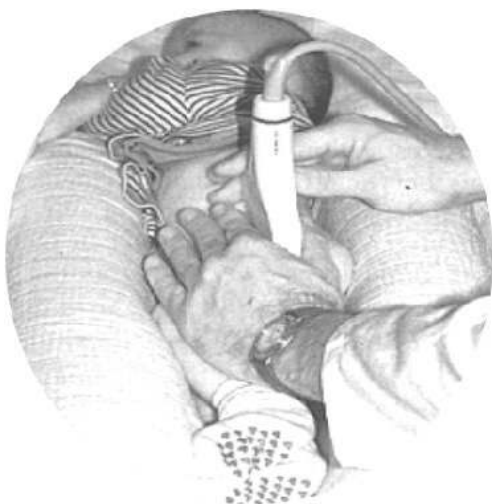


Figure 2. Child hip examination ultrasound.

Radiographic diagnostics, which was mainly used in our country, in addition to its proven harmful effects, is very difficult and misleading. The first months of life are crucial, for setting up possible diagnosis as well, because according to the data, the healing rate in open hip anomalies in the first month is 100%, yet already in the fourth month of life this percentage falls to 60%. This in itself speaks about the benefits of ultrasound diagnostics. Here we note the importance of quality and detailed ultrasound examination and extremely patient clinician, because even a small mistake, a small loss of patience or noncompliance of procedure can result in serious diagnostic failures with unforeseeable consequences.

We suggest an ultrasound hip screening of every baby up to 4 months of age without a specific indication. Of course that the positive family history, hormonal maintained pregnancy, oligohydramnios, pelvic presentation and caesarean section, indicate grounds for a pediatrician to send a child to children's orthopaedist as soon as possible.

An examination is performed in the lateral decubitus. Stability assessment is carried out through the assessments of the femur epiphysis and acetabulum, and by determining the angular parameters of bone and cartilage edge of the acetabulum on the sonogram (**Figure 3**).

Rather informatively, in short we list the Graphs infant hip classification based on ultrasound examination:

Type I: Fits to mature newborn hip, bone formation of acetabulum is good, but part of the acetabular cartilage supplements the bony part, thus the acetabular roof is completed.

Type II: Bone formation is not satisfactory, the cartilage roof is extended. Here we say that there is a delay in bone development.

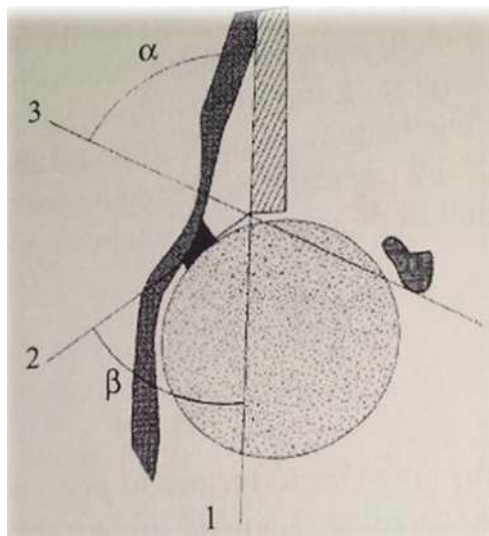


Figure 3. Schematic draws of diagnosis, using ultrasound with alpha and beta angles, based on marked lines 1, 2, and 3.

Type III: Cartilage part of the acetabular roof is deformed and pushed in craniolateral direction.

Type IV: Femoral head is luxated in dorsocranial direction. The entrance to the acetabulum is closed [2].

In this section, we will talk about subtypes and the morphometric ultrasonic hip balance change with reference lines, points, and angles.

Radiological diagnostic, after clinical and ultrasound examination leads to a definitive diagnosis of DDH. This type of examination is used only after 3 months of age. The reason lies in the fact that in the first 3 months, the reference bone structures are insufficiently developed, thus the recorded image is not suitable for interpretation. Technically, the imaging is done in the AP position, the child lies on its back with his feet together, with a mild hip and knee flexion of 30° in order to avoid the impact of the lumbar lordosis. Central rays are directed to the pubic symphysis, while protecting the gonads of a child, especially of male gender.

With interpretation, in order to avoid subjectivity, we use the extra lines that pave the X-ray of the pelvis with the hips:

1. Hilgenreiner line or Y line passing through Y crack.
2. Ombredann-Parkinson line perpendicularly cuts prior line and passes through the lateral edge of acetabulum.
3. Acetabular line passes along the edge of the roof of acetabulum.
4. Shenton-Menard line or cervical-obturatorious arc in healthy individuals it represents an unbroken line passing along the medial edge of the femur and continuing to the upper edge of obturator opening.

Squares incurred by crossing the first two lines define the position of the femoral head. In healthy hips, the head is placed regularly in the lower medial square, in subluxated hips in the lower lateral, and in luxated hips in the upper lateral square. Acetabular index represents the angle formed by Y cartilage and acetabular line crossing. After birth, acetabular index should not exceed 30°, and in the third year 20°. In infants, the value of acetabular index of 24° or more with the rounded edge of the acetabulum speaks in favor of a dysplastic hip (**Figure 4**).

In addition to the above mentioned diagnostic methods, arthrography, CT scan of the hip, and MRI are also used, but very rarely [3, 4].

2.4. Conservative treatment

Here we perform a strict division to the conservative treatment, which is possible in the first months of a child's life, and surgical treatment which we prefer in later months of child development.

We strongly emphasize the benefits of preventive measures, together with advice to parents for a wide diapering, the importance of exercises during dressing of a child, and of course strictly phasing out the use of early child support (walker and stroller). Every orthopedic surgeon and every doctor meets this challenging efforts of bad inherited practices and efforts for an early child support. Pointing out this error is never enough.

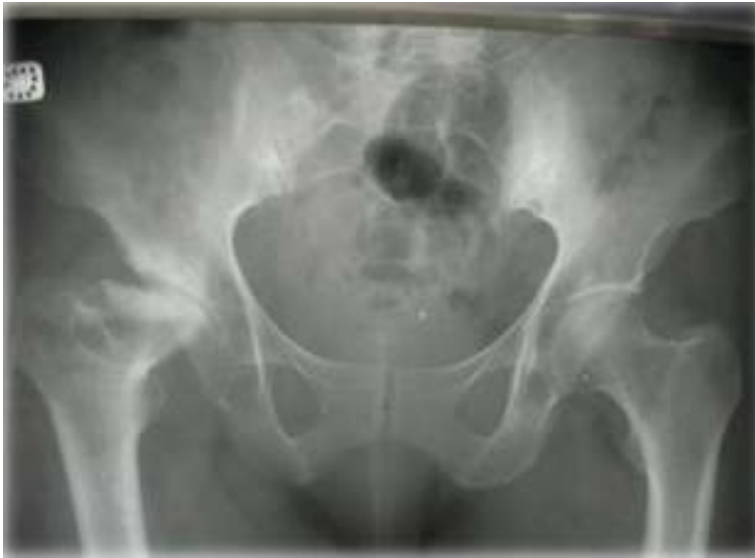

Figure 4. X-ray of the right neglected dysplastic hip and left healthy hip.

Abduction exercises for the hips suggest exercising approximately twenty times a day, each time you change a baby. These measures should be applied to every child as a mean of prevention.

Orthopedic briefs have almost been abandoned in practice, at our clinic as well. Its disadvantage lies in the fact that they can exacerbate harmful effect in the case of increased tension of adductor muscles.

Pavlik harness is a great way to treat DDH in the early months. Pavlik harnesses have the advantage of causing nonviolent reposition of the hip joint, and in addition, dynamically stimulate the development of joint elements. They can be used for the reduction, retention, and as an agent which enhances the maturation of the child hip. When we use them for reduction (reposition of the head in the acetabulum) the child is allowed to have small movements in the harness with basic abduction-flexion position. To encourage retention, we advise the use of tightly closed belts on the harness (pay attention to neurocirculatory status), while in the use for enhancing hip maturation we recommend the application as for a reduction but with no possibility of flexion in the hip. Reposition is achieved by abduction apparatus in flexion greater than 90 and abduction up to 50° (**Figures 5 and 6**).

Indications:

- primary DDH treatment at an early age; and
- continuation of treatment after the achievement repositioning with other method.

Application of the belt is made exclusively by a doctor in the presence of mother, but here we also must emphasize the importance of quality training of nurses to monitor the whole process.

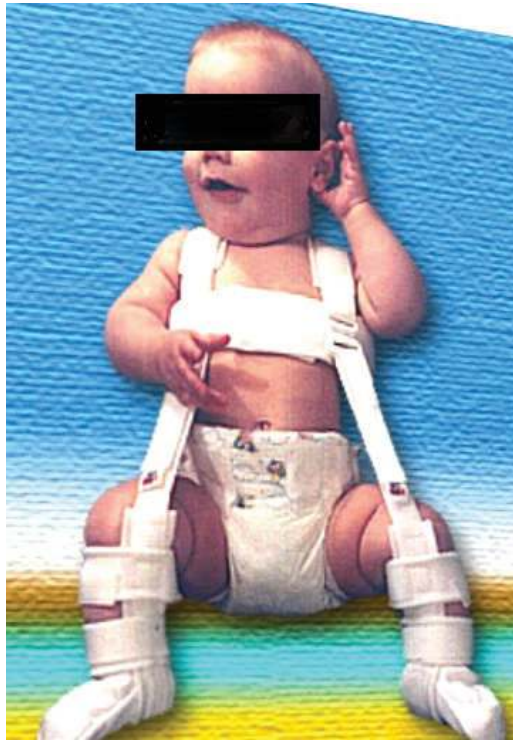

Figure 5. A child with Pavlik harness.

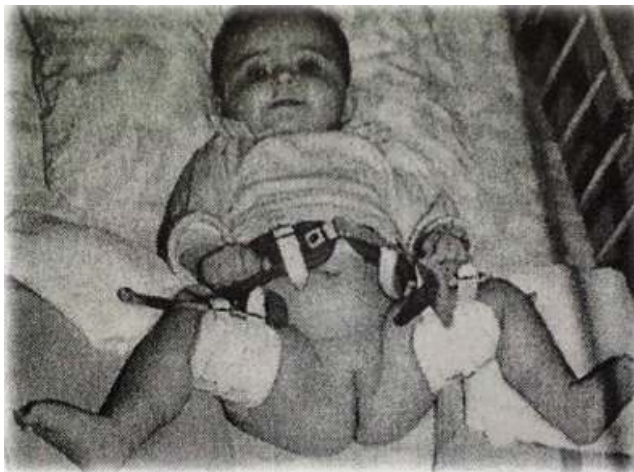

Figure 6. Apart from Pavlik harness, Hilger-Reiner apparatus is widely used in practice as well.

2.4.1. Traction techniques

Continuous traction aims to gradually progressively stretch the shortened soft tissues and to center the hip head in acetabulum, with the gradual adaptation of vascular and neurological elements.

Continuous traction is always carried out at the hospital. Here we should mention the position in which the reposition always takes place, and that is abduction and internal rotation.

There are two types of traction:

- overhead traction; and
- longitudinal traction according to Morel.

Overhead traction was first presented in the year 1955 in USA by Craig et al., and in Germany in the year 1956 by H. Mau and Dorr. Hips are flexed at the angle of 110° or more, while the abduction position is negligible (**Figure 7**). Abduction is increased very gently over the next 4 weeks, although the expansion is not recommended in the first 7 days. What occurs during this period is adaptation of adductor muscles and neurovascular net. Starting weight should not exceed 0.5–1 kg, depending on the age of the child. Mittelmeier reported 90% success with this method of repositioning. Essentially, we do not suggest a load increase over one-fifth of the body weight. Increasing the load to one-fourth of the body weight in order to enforce reposition has failed results [5].

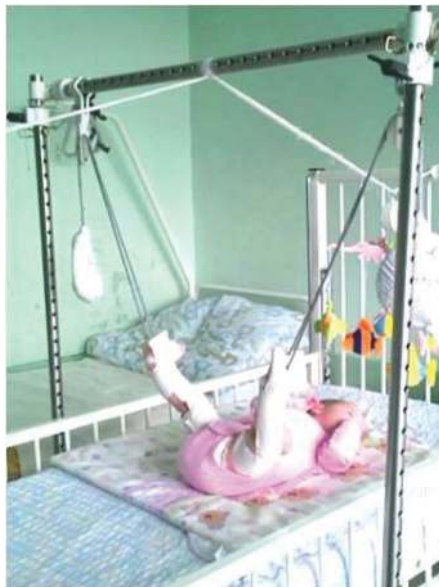

Figure 7. Risser traction is not only used before the apparatus application, but also as a part of preoperative patient preparation.

Longitudinal traction was displayed by Pravaz in 1874, and H. Mau and Dorr in Germany also presented this method and set rule that each closed reduction of luxated hip without preliminary traction represents the malpractice of the physician.

Elastic adhesive bandages are used to achieve the reduction. We recommend it to children of 12 months and to apply it in light flexion. Only after X-rays, if it shows the femoral head lowered below the level of the roof of acetabulum, we can begin easy abduction. If a physician is satisfied with reposition and stability of the hip, we suggest placing a child in vertical position and applying abduction apparatus for the walking below 60°. If the reduction is not stable, we recommend immobilizing the child with cast bandage in a reduced position.

We emphasize that the cast immobilization is done in the human position, which is the position of the upper leg abduction of 45°, 100 degrees of flexion with neutral rotation (**Figure 8**).

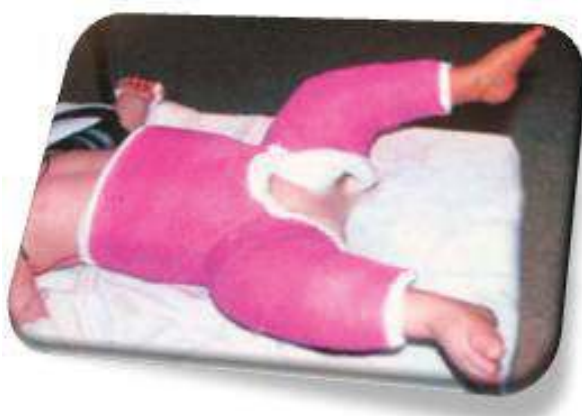

Figure 8. Cast shorts.

3. Conclusion

Hip ultrasonography as a screening method represents the most efficient and the cheapest method in detection of DDH where, with conservative treatment, great results can be achieved with no need for additional surgical intervention [6, 7]. This type of treatment represents relief for a patient, its' parents, medical personnel, and the society, in general. Because of this fact, appropriate and on-time cooperation among gynecologists, neonatologists, pediatricians, radiologists, and orthopedic surgeons is extremely important for early detection of DDH and the beginning of the conservative treatment [8].

Author details

Ismet Gavrankapetanović* and Adnan Papović

*Address all correspondence to: ismetcap@ortotrauma.com.ba

Clinic for Orthopedics and Traumatology, University Clinical Center Sarajevo, Sarajevo, Bosnia and Herzegovina

References

- [1] Graf R. Is DDH still a problem. *Arch Bone Jt Surg.* 2014;March(2(1):2–3).
- [2] Graf R, Mohajer M, Plattner F. Hip sonography update. Quality – management, catastrophes – tips and tricks. *Med Ultrason.* 2013;Dec(15(4):299–303).
- [3] Graf R. The use of ultrasonography in developmental dysplasia of the hip. *Acta Orthop Traumatol Turc.* 2007;(41(Suppl 1):6–13).
- [4] Stiegler H, Hafner E, Schuchter K, Engel A, Graf R. A sonographic study of perinatal hip development: from 34 weeks of gestation to 6 weeks of age. *J Pediatr Orthop B.* 2003;Nov(12(6):365–368).
- [5] Burian M, Dungal P, Chomiak J, Oštadal M, Frydrychova M. Efficiency of conservative treatment by overhead traction in developmental dysplasia of the hip. *Acta Chir Orthop Traumatol Cech.* 2010;Oct(77(5):371–377).
- [6] Dias JJ, Thomas IH, Lamont AC, Mody BS, Thompson JR. The reliability of ultrasonographic assessment of neonatal hips. *J Bone Joint Surg.* 1993;(75(3):479–482).
- [7] Leonhardi A, Reither M. Ultrasound screening of newborn infants. Uses and role in routine diagnosis. *Klinische Pediatrie.* 1993;(205(6):383–388).
- [8] Matasović T, Strinković B. *Dječija ortopedija.* Zagreb: Školska knjiga; 1986.

