

# The Application of Functional Magnetic Resonance Imaging in Neuropathic Pain

*Zhi Dou and Liqiang Yang*

## Abstract

In the past, neuropathic pain has been lacking in ideal imaging research methods, which not only limits our research on the pathogenesis of neuropathic pain but also seriously affects the prognosis of treatments. With the rapid development of fMRI technology, more and more scholars have begun to use fMRI technology in the study of neuropathic pain in recent years. This provides a new idea for revealing the underlining mechanisms of neuropathic pain and improving the clinical treatment concepts. In this chapter, we summarized the recent studies of fMRI in neuropathic pain so that readers can better understand the research status and future research directions.

**Keywords:** functional magnetic resonance imaging, brain region, brain network, neuropathic pain

## 1. Introduction

Neuropathic pain (NP) is a common type of pain disease with a prevalence of 1–2% in the total population [1, 2]. Although it is less common than nociceptive pain caused by degeneration of the spine and bones, neuropathic pain is often more severe, accompanied by severe emotional reactions, and the clinical efficacy is not ideal. The problems caused by neuropathic pain in the declined quality of life and the loss of working capacity have caused enormous burdens on patients, families, and our society. The International Association for the Study of Pain (IASP) defines neuropathic pain as “the pain that arises as a direct consequence of a lesion or diseases affecting the somatosensory system.” According to the location of the damage to the nervous system, neuropathic pain can be divided into peripheral and central types. Typical symptoms include hyperalgesia, allodynia, spontaneous pain, paresthesia, and other positive signs, as well as negative signs such as sensory loss and shallow reflex disappear [3].

It is now widely accepted that neuropathic pain is caused by a common change in the sensitivity of peripheral and central nervous system signaling. Peripheral mechanisms may include ectopic and spontaneous discharges, pseudo synaptic conduction, changes in ion channel expression, sympathetic neuron sprouting into dorsal root ganglia, and sensitization of nociceptors. The central mechanism also plays an important role in the pathogenesis of neuropathic pain, especially the processing and integration of information in the high-level centers such as the cerebral

cortex, brainstem, and cerebellum, which are closely related to the chronic pain and the emergence of many typical symptoms and signs [3]. In the past, studies on the central mechanism of neuropathic pain were mostly limited to clinical observations and animal experiments. However, in recent years, with the development of neuroimaging techniques, especially the maturity of functional magnetic resonance, researchers have been able to explore the structure and function of the brain in multiple levels, providing new ideas for the study of the underlying changes of central nerves system in neuropathic pain.

## **2. Functional magnetic resonance imaging (fMRI)**

Magnetic resonance imaging is an imaging technique based on the principle of nuclear magnetic resonance. According to the difference of research purposes, it can be roughly divided into two categories: structural imaging and functional imaging. The purpose of structure imaging is mainly to study the anatomical structure of brain tissue and the structural fiber connection between different brain regions. The main techniques are conventional brain structure imaging and voxel-based morphological measurement (VBM), diffusion tensor imaging (DTI), etc. VBM can provide regions of interest for brain function changes. DTI can be used to analyze the anatomical basis of functional connectivity in brain regions and therefore belongs to the generalized fMRI. The narrow sense of fMRI mainly refers to a technique for studying brain function activities by monitoring changes in cerebral blood flow. The purpose is to explore the neural activity of each brain region under different physiological or pathological conditions. According to the differences in research methods, it can be divided into task-state fMRI and resting-state fMRI.

### **2.1 VBM**

VBM is a technique for analyzing brain magnetic resonance images at the voxel level. It can quantitatively calculate the changes in local gray and white matter density and volume, so as to accurately display the morphological changes of brain structure. Neuropathic pain can cause changes in the plasticity of the brain structure, such as variation in the gray matter density of the cortex in the brain region. The degree of gray matter density in some brain regions is also related to various clinical indicators such as the length of disease and pain intensity. These changes can be studied with VBM [4].

By tracking follow-up of patients with herpes zoster (HZ), Cao et al. compared the differences in gray matter volume between patients with acute herpes zoster and postherpetic neuralgia (PHN). They found that the PHN brain showed decreased gray matter volume in the frontal lobe, the parietal lobe, and the occipital lobe but increased in the cerebellum and the temporal lobe. These changes may be correlated with HZ-PHN chronification [5]. In several trigeminal neuralgia studies, the reduction of the volume of the anterior cingulate cortex (ACC) and the increase of the volume of the temporal cortex were found. Li et al. also considered that the increase in the volume of the upper and middle gyrus was proportional to the duration of trigeminal neuralgia [6, 7].

### **2.2 DTI**

Modern brain science believes that the human brain is a complex and efficient network called the brain network. Each region of the brain is responsible for relatively independent functions and has a large number of structural and functional

connections with each other. The brain network is formed based on this separation and integration principle. White matter fiber bundle is the material basis for connecting the various nodes of the network for information transmission. Any damage to the structure or function of the white matter fiber bundles may affect the information transmission of the brain and cause disease manifestation. DTI is currently the only noninvasive method for effectively observing and tracking white matter fiber bundles. Because of the directionality of the white matter fiber bundles, the internal water molecules are dispersed in a direction-dependent manner, which is called anisotropic. By tracking of the movement direction of water molecules, DTI can reflect the dispersion characteristics of water in white matter fibers and reveal the influence of neuropathic pain on the connection state of brain network structure.

In many DTI studies, trigeminal neuralgia is the most studied type of neuropathic pain. In the case of primary trigeminal neuralgia caused by neurovascular compression, the degree of damage of the trigeminal white matter fiber can be estimated by DTI, thereby assessing the prognosis of microvascular decompression [8]. The diffusion of water molecules from the trigeminal root and root entry zone can help to classify the TN in order to select a more appropriate treatment [9]. In the study of postherpetic neuralgia, researchers also found that there exists altered microstructure integrity of white matter in multiple brain regions in patients with PHN, and these changes increase in size as the duration of the pain increases [10].

### 2.3 fMRI

Blood oxygenation level-dependent (BOLD) fMRI technique is currently the most widely used fMRI imaging method [11]. The normal functional activity of neurons requires a stable supply of oxygen provided by hemoglobin in the blood, wherein oxyhemoglobin exhibits diamagnetism in the magnetic field due to the shielding effect of oxygen atoms, while deoxyhemoglobin exhibits paramagnetism. In this way, differences in oxygenated blood and deoxygenated magnetic susceptibility can be captured by magnetically sensitive weighted MR images using BOLD fMRI technique [12]. When neurons are excited, the oxygen consumption of these neurons and their surrounding tissue increases, causing a transient decrease in blood oxygen content. This change in the ratio of oxygenated and deoxygenated hemoglobin causes a downward initial tilt angle of the BOLD signal. Due to the continued demand for oxygen, the blood flow there will increase rapidly, and excessive compensation will make the proportion of oxygenated hemoglobin increase and the BOLD signal go up. When the neurons stop exciting and the demand for oxygen is reduced, BOLD will have a negative signal after the stimulus and then gradually return to the baseline. Therefore, by measuring the changes of BOLD signal, fMRI can detect the activation of various regions of the brain and can analyze the temporal correlation of activation or inhibition of different brain regions by simultaneously recording the time series, thereby establishing functional connections of the brain in a specific state [13, 14].

According to the design type of fMRI research, it can be divided into task state and resting state. Task-state fMRI can detect brain regions closely related to certain functions or stimuli by comparing the fMRI images of subjects with and without tasks. It belongs to the study of functional separation of brain regions. By task-state fMRI, a large amount of data has been obtained about the locations and activations of brain regions in neuropathic pain. Resting-state fMRI refers to the data collection when the subject is lying still, the whole body is relaxed, the external stimuli are excluded, and the awake state is maintained. The obtained information is considered to reflect the spontaneous activities in baseline state of the central nervous

system. These spontaneous activities not only consume a lot of energy (60–80% of the total energy consumption of the brain) but also have an inherent spatial pattern called the resting brain functional network, which belongs to the study of functional integration between different brain regions of the brain [15, 16]. Studies have shown that many neurologically related diseases, including neuropathic pain, can have a characteristic impact on this resting brain functional network [17, 18], whereas the study of this brain functional network change is more conducive to the clarification of the disease mechanism and the improvement of the diagnosis and treatment level of neuropathic pain [15].

### 3. fMRI study of the central mechanism of neuropathic pain

#### 3.1 Pain perception in the brain and the process of information transmission

The brain's perception of pain has been one of the most interesting topics in the field of neuroimaging. Since the initial stage of fMRI technology, there have been a large number of related studies. With the in-depth study of the processing and transmission of pain information, the concept of “pain matrix” has gradually formed, which means that pain is achieved through the division of work between multiple regions of the brain, just like a network structure. The pain matrix mainly includes the thalamus, insula, primary somatosensory cortex (S1), secondary somatosensory cortex (S2), anterior cingulate cortex, periaqueductal gray (PAG), amygdala, etc. (Figure 1) [20–22]. Significant functional changes will occur in various brain regions within this pain matrix when suffering from acute nociceptive pain [23].

fMRI can be used not only in humans but also in animals such as rats and monkeys. Among these, spared nerve injury (SNI) rats can produce persistent and stable symptoms such as hyperalgesia, allodynia, and spontaneous pain, which are commonly used in the study of neuropathic pain. Komaki et al. studied the resting-state fMRI changes in the SNI rat model and studied the node efficiency of some regions of interest and the functional connections between regions of interest by graph theory. They found that the centrality and node efficiency of the S1 region

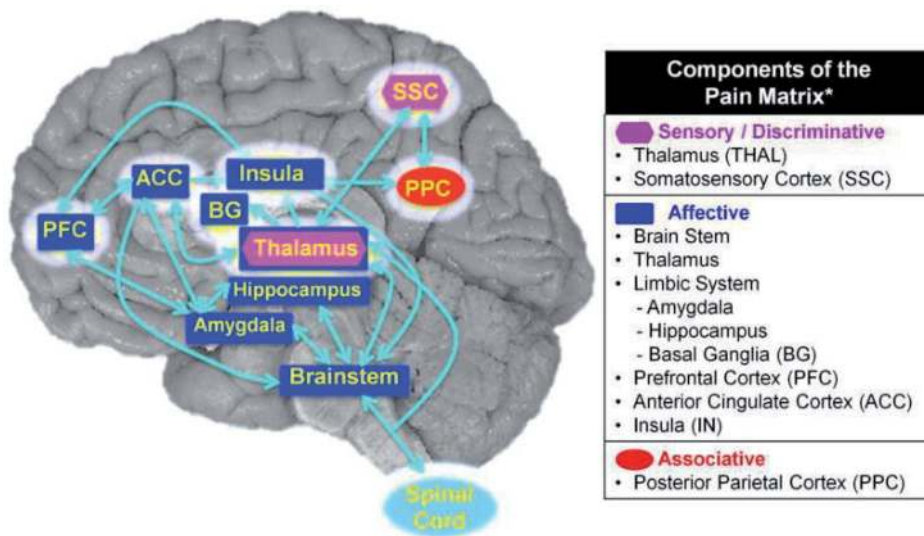


Figure 1. Schematic diagram of pain matrix [19].

in the opposite side of the injured limb were significantly lower after injury, while the functional connection between the ACC and the posterolateral nucleus of the thalamus was significantly enhanced. This phenomenon may be related to the regulation of secondary nociceptor function by glial cells in the thalamus [24], and mononuclear/macrophage and T lymphocytes may also be involved in [25].

The results of the above studies indicate that although many brain regions involved in pain perception overlap in their respective functions, their functional connections are regularly changing [26]. The lateral thalamus, S2, and insula may be involved in the perception of pain information, and excessive activation of the posterior parietal and prefrontal cortex (PFC) promotes cognitive attention to nociceptive stimuli. Different parts of the ACC are involved in the adaptation or emotional response to pain. Motion control areas (such as basal ganglia, SMA, cerebellum) are involved in the functional regulation of the pain-suppression system and the avoidance behavior of pain. The amygdala plays an important role in the processing of nociceptive information processing and participates in the regulation of medial prefrontal cortex and spinal cord excitability [27, 28]. Abnormal amygdala function is associated with the formation of neuropathic pain, and the destruction of the amygdala can reduce the incidence of neuropathic pain [29]. Through the study of these regular changes, we can deepen the understanding of pain information processing in the brain, and it also helps to define the neurobiological basis of the formation of various typical symptoms of neuropathic pain.

### **3.2 Chronic process of neuropathic pain**

The normal perception of pain and avoidance response is an important physiological protection mechanism. The chronic process of pain is the cause of neuropathic pain and the root of refractory disease. In the past, the understanding of the chronic process of neuropathic pain mostly stayed in the sensitization of nociceptors, the axonal buds of sensory neurons, etc. The understanding of advanced central structures and functional changes in the cerebral cortex was still limited. Nevertheless, fMRI is a powerful tool for studying the process of chronic pain. Both clinical observation and animal experiments have found that chronic process of neuropathic pain is associated with large-scale brain function changes and morphological remodeling [30].

Zhang et al. found that the connection strength of the brain's default network in patients with chronic neuropathic pain was significantly different from that of healthy controls, mainly as the weakening connections in characteristic areas of the default network itself (clamping back in the middle, back, inferior parietal lobule) and motor-related areas (superior parietal lobule, auxiliary sports area) [31]. Hubbard et al.'s task-state fMRI study of SNI rats found that when they stimulated the injured limbs in the injury (4 weeks after surgery), the activity of the contralateral somatosensory cortex (S1, S2), the posterolateral nucleus of the thalamus, and the dorsal striatum was enhanced compared with pre-injury and the control groups, whereas the activity of areas associated with painful emotional responses, such as contralateral insula, medial thalamus, and ipsilateral ACC, was inhibited. Resting-state fMRI study showed an enhanced functional connection between the nucleus accumbens (NAc) and the dorsal striatum. At the same time, molecular biology study found that the expression of dopamine 1A receptor and  $\kappa$  opioid receptor in NAc was downregulated. Moreover, the degree of functional compromise is proportional to the degree of downregulation of dopamine receptor gene expression. Inhibition of NAc's functional activity (injection of lidocaine) significantly reduced pain in SNI model animals [32]. At the late stage of injury (20 weeks after surgery), ACC, prefrontal, insula, basal ganglia, and S1 activity was significantly enhanced,

while activity in the medial thalamus and PAG areas was inhibited [33]. It can be seen that the formation of neuropathic pain is related to the inhibition of the function of the descending regulation system of pain [34]. ACC activity is inhibited in the early stages of nerve injury, and with the chronic process of pain, ACC activity is gradually enhanced, which may be related to the unpleasant emotional experience of neuropathic pain [29, 35, 36].

A recent resting-state fMRI study found that several major components of the limbic system, hippocampus, amygdala, striatum, and medial prefrontal cortex, are associated with neuropathic pain formation and maintenance [37]. Although SNI rats showed significant changes of activity degree in some brain regions in the early stage of pain, the functional connection between brain regions was not significantly different from that in rats receiving physiological pain stimulation. It can be considered as a normal response of pain matrix to noxious stimuli. However, with the extension of model establishment time, significant changes in the brain functional network occur, and the remodeled brain network has a specific topology. The vast majority of changes in long-term functional connections (97%) occurred within the edge system, and between the edge system and the nociceptive network, while there were no functional connection changes in the nociceptive network [38]. The limbic system neural network adjusts the reward and punishment, appetite, aversion, etc. to generate emotions and behaviors that can adapt to the pain state, so that the brain network gradually adapts to this pain state and the pain tends to be chronic.

### **3.3 Hyperalgesia and allodynia**

The concept of hyperalgesia and allodynia is often confused, but in fact their formation mechanisms are different. Hyperalgesia refers to a phenomenon in which the pain threshold caused by tissue damage is reduced and the response to noxious stimulation is abnormally enhanced and prolonged. Maihofner et al. found that mechanical pain sensitivity led to abnormal activation of S1, S2, parietal association cortex (PA), insular, superior frontal cortex (SFC), and inferior frontal cortex (IFC) [39], whereas patients with hyperalgesia will have abnormal activation of S1, S2, PA, medial frontal cortex (MFC), ACC, and contralateral SFC and IFC [40]. Zambreau et al. found that in resting state, patients with no spontaneous pain but hyperalgesia would have abnormal functional activities in multiple regions of the midbrain reticular formation in the brainstem region, namely, nucleus cuneiformis (NCF), rostral superior colliculi (SC), and PAG [41]. The resting-state fMRI of the SNI rat model showed a significant increase in the functional connection between the hippocampus and the striatum, and the intensity was inversely correlated with the mechanical pain threshold of SNI rats.

The clinical manifestation of allodynia is that non-noxious stimuli (such as light touch, mild rubbing, non-noxious cold stimuli) can cause pain, which is a manifestation of “misreading” of somatosensory information. Peripheral sensory nerves are classified into three types: A $\beta$ , A $\delta$ , and C fibers. Normally, the tactile signal is transmitted through the A $\beta$  fiber to the mechanical stimulation zone of the spinal cord. However, in neuropathic pain, A $\beta$  fibers may be abnormally linked to the pain transmission pathway, leading to symptoms such as allodynia [42, 43]. Task-state fMRI is the ideal tool for studying allodynia. Localization and functional connectivity of brain regions associated with allodynia can be achieved by comparing the states of no stimulation, stimulating pain hypersensitivity, and stimulating the same part of the contralateral body. Clinical studies have shown that somatic stimulation signals are amplified by the thalamic and thalamic-parietal circuits, causing excessive activation of the lateral pain sensory system and attention network (posterior parietal lobe). Unlike the response of the thalamic-parietal system,

the role of ACC and medial prefrontal lobe in allodynia is more complicated. First, different parts of ACC respond differently to nociceptive stimuli. The central part of ACC was significantly activated during peripheral nerve injury-induced allodynia, whereas there was no significant change in the degree of activation in pain hypersensitivity caused by Wallenberg's lateral infarction. This may be due to the fact that the central part of ACC receives signals from the spinal thalamus bundle and Wallenberg's syndrome causes damage to the spinal thalamic bundle; nevertheless peripheral neuropathic pain does not. However, in most neuropathic pains, whether peripheral or central, the axons of ACC are shown to have a reduced degree of activation when allodynia is induced. The brain regions activated by different stimulating components are also different. Cold and mechanical stimulation can cause significant activation of the prefrontal cortex (PFC) and basal ganglia, and the degree of activation is related to the functional status of ACC [33], and insula signal significantly enhances during stimulation [44].

A similar phenomenon was also found in fMRI study of the SNI animal model by Komaki et al. According to the physiological characteristics of each nerve fiber, the A $\beta$  fiber can be selectively excited by a current of 2000 Hz, 2.2 mA. When the hind paws of normal rats were administered with 2000 Hz, 2.2 mA DC stimulation, it caused only significant activation of the S1 region; however, when the same intensity of current was used to stimulate the pain-sensing hypersensitivity zone of SNI rats, it was found that not only S1, ACC, and thalamus were also significant activated [45].

### **3.4 Spontaneous pain**

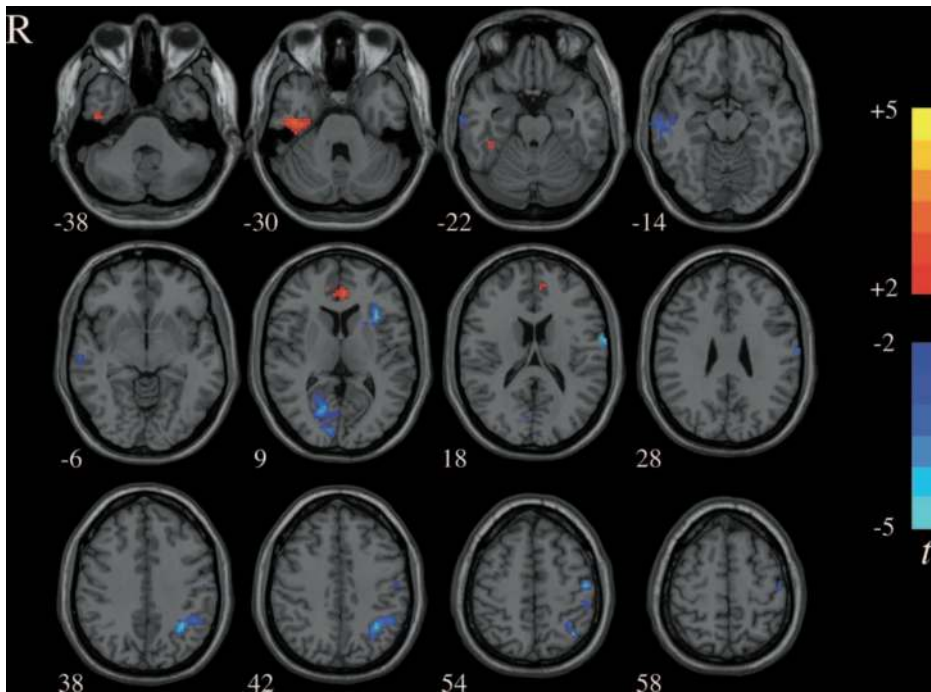
Spontaneous pain is generally difficult to study with fMRI. Because it is difficult to obtain a comparison of pain and painlessness in the same patient under clinical conditions, this type of clinical study is still rare. A few studies include spinal cordectomy for cancer pain [46], persistent neuropathic pain before and after local anesthesia [47], and central pain before and after motor cortex stimulation [48]. A common finding of these studies is the reduction in local blood flow in the thalamus, that is, the decrease in thalamic activity, which is restored after pain relief. This depression of lateral thalamic function is found both in peripheral and central neuropathic pain [49].

In the study of trigeminal neuralgia and sphenopalatine neuralgia with typical spontaneous pain characteristics, it was found that the functional connection between the ipsilateral hypothalamus and the contralateral S1 and the ipsilateral wedge was weakened during the pain attack and remission. However, compared with the pain relief period, the functional connection between the hypothalamus and the S1, anterior wedge, and cerebellum is much less during the onset of pain [50].

### **3.5 Characteristic changes of brain function in different types of neuropathic pain**

In addition to the common changes in neuropathic pains, different types of neuropathic pain also have characteristic changes. By studying these changes, it is helpful to clarify its pathogenesis, and it is also possible to screen out specific neuroimaging markers for the diagnosis and evaluation of diseases (**Figure 2**).

Neurovascular compression has long been considered to be the cause of primary trigeminal neuralgia. The 3D TOF MRA and 3D FIESTA sequences can clearly show the positional relationship between the nerves and blood vessels in the root enter zone (REZ) [52–54]. However, nerve compression is not the direct



**Figure 2.**  
*Characteristic ROIs of trigeminal neuralgia [51].*

cause of trigeminal neuralgia. There are also many individuals in the population who have neurological compression but no clinical symptoms of trigeminal neuralgia [55]. Lin et al. found that there were no damage and functional changes in the white matter fibrin myelin or axons in patients with nerve compression but asymptomatic in their DTI study [56]. DeSouza found that the fractional anisotropy (FA) of REZ in patients with trigeminal neuralgia was 22% lower than that of the healthy side and 27% lower than that of healthy controls. Other white matter microstructural measurements of patients such as radial diffusivity (RD), axial diffusivity (AD), and mean diffusivity (MD) were higher than those of healthy controls, indicating demyelinating lesions without axonal injury may be an important factor in the pathogenesis of trigeminal neuralgia [57]. They then compared changes in white matter fiber connections in the REZ region before and after microvascular decompression. It is found that FA, MD, RD, and AD all recovered in the normal direction after treatment and the degree of recovery was proportional to the degree of pain relief [58]. It is suggested that nerve compression by blood vessels is only the inducement of trigeminal neuralgia, and the occurrence and maintenance of pain may be related to abnormal white matter fibers at REZ.

The task-state fMRI conducted by Moisset initially explored the effect of the trigger point of patients with trigeminal neuralgia on brain functional activity. They found that when the pain was onset, spinal trigeminal nucleus (SpV), thalamus, S1, S2, ACC, insular, premotor cortex, motor cortex, frontal nucleus, putamen, etc. were clearly activated in patients with trigger points. In patients without trigger points, the brain regions abovementioned were also activated except SpV, brainstem, and ACC. It can be considered that the structural or functional changes at these three regions may be related to the formation of the trigger point [59]. There are still a small number of studies on resting-state fMRI in patients with trigeminal neuralgia. Athinoula et al. found a weaker functional connection between amygdala and insula and S2 in a comparative study of migraine and trigeminal neuralgia [60].



Wang et al.'s study showed a significant reduction in local consistency activity in the amygdala, hippocampus, and cerebellum in patients with trigeminal neuralgia [61].

The cause of residual limb pain or phantom pain after amputation has been controversial. Some people think that the sudden introduction of nerve afferents from the limbs will cause the expansion or displacement of the sensory cortex, which is called the incompatible remodeling of the cortex [62, 63]. This theory has been proposed for more than 20 years, but it is difficult to be verified before the rise of fMRI technology [64, 65]. Lotze et al. conducted a task-state fMRI study and found that cortical remodeling in patients with phantom limb pain is not limited to S1 but also includes some auxiliary sports areas [66]. For example, when the lips move, the activation degree of the representative region of the broken limb in M1 is also significantly enhanced, indicating that the lip represents region expands and displaces to the cortex of broken limb [67]. Moreover, the degree of displacement of the cortex to the representative area of the isolated limb is positively correlated with the degree of pain [68]. After mirror therapy, cortical displacement can be partially restored, and the pain intensity can be reduced [69].

Cauda et al. found that the functional connections between the ventral posterior nucleus (VP) and the medial dorsal nucleus (MD) and the cerebral cortex were weakened in patients with diabetic peripheral neuropathy [70]. Cifre observed a weakened connection between resting thalamus and insula in patients with fibromyalgia [71]. In patients with postherpetic neuralgia, the reward circuit consisting of the striatum, prefrontal cortex, amygdala, and hippocampus and the circuits composed of striatum, thalamus, and insular leaves have very close functional connection [72]. With the advancement of fMRI data analysis methods and machine learning techniques, these seemingly cluttered functional connectivity features are highly likely to be used as neuroimaging markers for the diagnosis of neuropathic pain. In other studies of nervous system diseases, some scholars have successfully used fMRI technology to construct a resting brain functional network model for patients with Alzheimer's disease. And with the using of multimode variable analysis method, the sensitivity and specificity of early screening of Alzheimer's disease in the general population is up to 90% [73].

#### **4. The value of fMRI in the clinical treatment of neuropathic pain**

In the past, the examination and evaluation of neuropathic pain relied mainly on medical history, symptoms, and signs and lacked tools for quantitative assessment. Even with the von Frey fiber test, the same stimulation site and strength often result in a lack of consistency [74]. The reason is that the activity of the nerve is disturbed by many factors. Inclusion of peripheral and central sensitization, genetics, cognition, and emotional response during testing will affect the signal transmission of noxious stimuli to the painful sensation area of the brain [75]. In addition, the subjective tendencies of participants and examiners may also cause serious bias. However, fMRI technology may provide us with qualitative and quantitative observations [76]. For example, PoCG's corresponding somatosensory representative area can help clinicians determine the pain site, and the degree of activation can also reflect the intensity of pain [51]. The local activity consistency of rostral anterior part of ACC in patients with postherpetic neuralgia was significantly correlated with the anxiety and depression scores [77, 78].

fMRI can also be used to observe the effects of treatments on brain function or to assess the therapeutic effects of neuropathic pain. For example, after the application of opioids to achieve pain relief, an increase in ACC activation can be found. Thalamic electrical stimulation can significantly increase the activation of

the rostral anterior part of ACC and the basal part of frontal cortex. These two sites are generally in a state of functional inhibition in patients with chronic neuropathic pain. A study of drug therapy for trigeminal neuralgia has shown that lamotrigine can reduce the pain level of patients by reducing the excitability of the prefrontal, parietal, and temporal lobe and inhibit allodynia [79].

As a method for treating neuropathic pain, neuromodulation technology has been applied for decades. However, whether it is invasive spinal cord electrical stimulation, deep brain stimulation, or noninvasive transcranial magnetic stimulation, there is a problem of inefficiency. The reason may be due to individual differences in the effects of disease on the brain functional network. fMRI can accurately capture the brain regions with abnormal functions and combine the analysis of functional connections in the brain to determine the regions of interest for neuromodulation, which is used to guide the target area of transcranial magnetic stimulation or the placement of epidural stimulation electrodes [80, 81]. It is helpful to improve the efficacy of neuromodulation techniques.

## **5. Limitations and future direction of fMRI research in NP**

Most of the previous studies were limited by the fMRI data analysis method. They can only analyze for a single factor, or only focus on brain regions or functional connections with significant differences, while ignoring the complexity and synergy of the brain function network as a whole structure. And the conclusions drawn lack clinical utility and provide limited assistance in the diagnosis and prediction of diseases.

In recent years, with the increasing maturity of machine learning technology, machine learning and pattern recognition technology are being used more and more for fMRI data analysis. By using machine learning technology to process the massive characteristic data generated by fMRI, multiple dimensions such as gray matter volume, diffusion of water molecules, and functional connectivity can be used simultaneously [82]. In the future, this research method of overall analysis of brain function networks can realize pattern recognition of different disease states. It can make fMRI technology better serve the clinic and provide assistance for the diagnosis and prognosis analysis of neuropathic pain.

## **6. Conclusion**

A large number of brain regions associated with neuropathic pain have been discovered by fMRI technology, and there has been some data accumulation for changes in functional connectivity between brain regions. However, how to analyze and process these fMRI data and make a reasonable explanation for better understanding the underlying disease mechanism as well as treatment improvement is the key to further expand the value of fMRI application in the future.

## **Author details**

Zhi Dou\* and Liqiang Yang

Department of Pain Management, Xuanwu Hospital, Capital Medical University,  
Beijing, China

\*Address all correspondence to: [douzhi@xwhosp.org](mailto:douzhi@xwhosp.org)

## **IntechOpen**

---

© 2019 The Author(s). Licensee IntechOpen. This chapter is distributed under the terms of the Creative Commons Attribution License (<http://creativecommons.org/licenses/by/3.0>), which permits unrestricted use, distribution, and reproduction in any medium, provided the original work is properly cited. 

## References

- [1] Jensen TS, Gottrup H, Sindrup SH, et al. The clinical picture of neuropathic pain. *European Journal of Pharmacology*. 2001;**429**(1-3):1-11
- [2] Chong MS, Bajwa ZH. Diagnosis and treatment of neuropathic pain. *Journal of Pain and Symptom Management*. 2003;**25**(5 Suppl):S4-S11
- [3] Vranken JH. Elucidation of pathophysiology and treatment of neuropathic pain. *Central Nervous System Agents in Medicinal Chemistry*. 2012;**12**(4):304-314
- [4] Henry DE, Chiodo AE, Yang W. Central nervous system reorganization in a variety of chronic pain states: A review. *PM & R : The Journal of Injury, Function, and Rehabilitation*. 2011;**3**(12):1116-1125
- [5] Cao S, Qin B, Zhang Y, et al. Herpes zoster chronification to postherpetic neuralgia induces brain activity and grey matter volume change. *American Journal of Translational Research*. 2018;**10**(1):184-199
- [6] Wang Y, Cao DY, Remeniuk B, et al. Altered brain structure and function associated with sensory and affective components of classic trigeminal neuralgia. *Pain*. 2017;**158**(8):1561-1570
- [7] Li M, Yan J, Li S, et al. Reduced volume of gray matter in patients with trigeminal neuralgia. *Brain Imaging and Behavior*. 2017;**11**(2):486-492
- [8] Chai W, You C, Zhang W, et al. Diffusion tensor imaging of microstructural alterations in the trigeminal nerve due to neurovascular contact/compression. *Acta Neurochirurgica*. 2019;**161**(7):1407-1413
- [9] Willsey MS, Collins KL, Conrad EC, et al. Diffusion tensor imaging reveals microstructural differences between subtypes of trigeminal neuralgia. *Journal of Neurosurgery*. 2019;**6**(19):1-7
- [10] Chen F, Chen F, Shang Z, et al. White matter microstructure degenerates in patients with postherpetic neuralgia. *Neuroscience Letters*. 2017;**656**:152-157
- [11] Ogawa S, Lee TM, Nayak AS, et al. Oxygenation-sensitive contrast in magnetic resonance image of rodent brain at high magnetic fields. *Magnetic Resonance in Medicine*. 1990;**14**(1):68-78
- [12] Logothetis NK. The neural basis of the blood-oxygen-level-dependent functional magnetic resonance imaging signal. *Philosophical Transactions of the Royal Society of London. Series B, Biological Sciences*. 2002;**357**(1424):1003-1037
- [13] Ogawa S, Lee TM, Kay AR, et al. Brain magnetic resonance imaging with contrast dependent on blood oxygenation. *Proceedings of the National Academy of Sciences of the United States of America*. 1990;**87**(24):9868-9872
- [14] Ogawa S, Menon RS, Tank DW, et al. Functional brain mapping by blood oxygenation level-dependent contrast magnetic resonance imaging. A comparison of signal characteristics with a biophysical model. *Biophysical Journal*. 1993;**64**(3):803-812
- [15] Lu H, Yuping N. When neuroscience meets network thinking: A new perspective on brain disorders. *Chinese Journal of Neuromedicines*. 2014, 2014;**13**(12):1292-1296
- [16] Dezhong Y, Luo C, Xu L, et al. Neuroimaging and brain connectome. *Chinese Journal of Biomedical Engineering*. 2011;**30**(1):6-10

- [17] Rubinov M, Sporns O. Weight-conserving characterization of complex functional brain networks. *NeuroImage*. 2011;**56**(4):2068-2079
- [18] Bassett DS, Bullmore ET. Human brain networks in health and disease. *Current Opinion in Neurology*. 2009;**22**(4):340-347
- [19] Melzack R. Evolution of the neuromatrix theory of pain. The Prithvi Raj lecture: Presented at the third World Congress of World Institute of Pain, Barcelona 2004. *Pain Practice*. 2005;**5**(2):85-94
- [20] Wager TD, Atlas LY, Lindquist MA, et al. An fMRI-based neurologic signature of physical pain. *The New England Journal of Medicine*. 2013;**368**(15):1388-1397
- [21] Davis KD, Taylor SJ, Crawley AP, et al. Functional MRI of pain- and attention-related activations in the human cingulate cortex. *Journal of Neurophysiology*. 1997;**77**(6):3370-3380
- [22] Nakao A, Takahashi Y, Nagase M, et al. Role of capsaicin-sensitive C-fiber afferents in neuropathic pain-induced synaptic potentiation in the nociceptive amygdala. *Molecular Pain*. 2012;**8**:51
- [23] Thompson SJ, Bushnell MC. Rodent functional and anatomical imaging of pain. *Neuroscience Letters*. 2012;**520**(2):131-139
- [24] Zhao P, Waxman SG, Hains BC. Modulation of thalamic nociceptive processing after spinal cord injury through remote activation of thalamic microglia by cysteine cysteine chemokine ligand 21. *The Journal of Neuroscience*. 2007;**27**(33):8893-8902
- [25] Wei XH, Zang Y, Wu CY, et al. Peri-sciatic administration of recombinant rat TNF- $\alpha$  induces mechanical allodynia via upregulation of TNF- $\alpha$  in dorsal root ganglia and in spinal dorsal horn: The role of NF-kappa B pathway. *Experimental Neurology*. 2007;**205**(2):471-484
- [26] Maihofner C, Nickel FT, Seifert F. Neuropathic pain and neuroplasticity in functional imaging studies. *Schmerz*. 2010;**24**(2):137-145
- [27] Baabor MG, Perez-Limonte L. Percutaneous balloon compression of the gasserian ganglion for the treatment of trigeminal neuralgia: Personal experience of 206 patients. *Acta Neurochirurgica. Supplement*. 2011;**108**:251-254
- [28] Bird GC, Lash LL, Han JS, et al. Protein kinase A-dependent enhanced NMDA receptor function in pain-related synaptic plasticity in rat amygdala neurones. *The Journal of Physiology*. 2005;**564**(3):907-921
- [29] Hashmi JA, Baliki MN, Huang L, et al. Shape shifting pain: Chronification of back pain shifts brain representation from nociceptive to emotional circuits. *Brain*. 2013;**136**(9):2751-2768
- [30] Apkarian AV, Baliki MN, Geha PY. Towards a theory of chronic pain. *Progress in Neurobiology*. 2009;**87**(2):81-97
- [31] Hua Z, Hao W, Duoduo L, et al. Default mode network altered in chronic pain caused by cervical spondylosis. *Chinese Journal of Rehabilitation Theory and Practice*. 2015;**21**(1):69-73
- [32] Chang PC, Pollema-Mays SL, Centeno MV, et al. Role of nucleus accumbens in neuropathic pain: Linked multi-scale evidence in the rat transitioning to neuropathic pain. *Pain*. 2014;**155**(6):1128-1139
- [33] Hubbard CS, Khan SA, Xu S, et al. Behavioral, metabolic and functional brain changes in a rat model of chronic neuropathic pain: A longitudinal MRI study. *NeuroImage*. 2015;**107**:333-344

- [34] Maarrawi J, Mertens P, Peyron R, et al. Functional exploration for neuropathic pain. *Advances and Technical Standards in Neurosurgery*. 2011;**37**:25-63
- [35] Davis KD, Taylor KS, Anastakis DJ. Nerve injury triggers changes in the brain. *The Neuroscientist*. 2011;**17**(4):407-422
- [36] Vertes RP. Interactions among the medial prefrontal cortex, hippocampus and midline thalamus in emotional and cognitive processing in the rat. *Neuroscience*. 2006;**142**(1):1-20
- [37] Berger SE, Baria AT, Baliki MN, et al. Risky monetary behavior in chronic back pain is associated with altered modular connectivity of the nucleus accumbens. *BMC Research Notes*. 2014;**7**:739
- [38] Baliki MN, Chang PC, Baria AT, et al. Resting-state functional reorganization of the rat limbic system following neuropathic injury. *Scientific Reports*. 2014;**4**:6186
- [39] Maihofner C, Schmelz M, Forster C, et al. Neural activation during experimental allodynia: A functional magnetic resonance imaging study. *The European Journal of Neuroscience*. 2004;**19**(12):3211-3218
- [40] Maihofner C, Handwerker HO. Differential coding of hyperalgesia in the human brain: A functional MRI study. *NeuroImage*. 2005;**28**(4):996-1006
- [41] Zambreanu L, Wise RG, Brooks JC, et al. A role for the brainstem in central sensitisation in humans. Evidence from functional magnetic resonance imaging. *Pain*. 2005;**114**(3):397-407
- [42] Komori K, Nonaka T, Okada A, et al. Absence of mechanical allodynia and Abeta-fiber sprouting after sciatic nerve injury in mice lacking membrane-type 5 matrix metalloproteinase. *FEBS Letters*. 2004;**557**(1-3):125-128
- [43] Ji RR, Kohno T, Moore KA, et al. Central sensitization and LTP: Do pain and memory share similar mechanisms? *Trends in Neurosciences*. 2003;**26**(12):696-705
- [44] Becerra L, Morris S, Bazes S, et al. Trigeminal neuropathic pain alters responses in CNS circuits to mechanical (brush) and thermal (cold and heat) stimuli. *The Journal of Neuroscience*. 2006;**26**(42):10646-10657
- [45] Komaki Y, Hikishima K, Shibata S, et al. Functional brain mapping using specific sensory-circuit stimulation and a theoretical graph network analysis in mice with neuropathic allodynia. *Scientific Reports*. 2016;**6**:37802
- [46] Di Piero V, Jones AK, Iannotti F, et al. Chronic pain: A PET study of the central effects of percutaneous high cervical cordotomy. *Pain*. 1991;**46**(1):9-12
- [47] Hsieh JC, Belfrage M, Stone-Elander S, et al. Central representation of chronic ongoing neuropathic pain studied by positron emission tomography. *Pain*. 1995;**63**(2):225-236
- [48] Garcia-Larrea L, Peyron R, Mertens P, et al. Electrical stimulation of motor cortex for pain control: A combined PET-scan and electrophysiological study. *Pain*. 1999;**83**(2):259-273
- [49] Peyron R, Garcia-Larrea L, Gregoire MC, et al. Haemodynamic brain responses to acute pain in humans: Sensory and attentional networks. *Brain*. 1999;**122**(Pt 9):1765-1780
- [50] Yang FC, Chou KH, Fuh JL, et al. Altered hypothalamic functional connectivity in cluster headache: A longitudinal resting-state functional

- MRI study. *Journal of Neurology, Neurosurgery, and Psychiatry*. 2015;**86**(4):437-445
- [51] Dou Z, Zhang X, Yang L, et al. Alternation of regional homogeneity in trigeminal neuralgia after percutaneous radiofrequency thermocoagulation: A resting state fMRI study. *Medicine (Baltimore)*. 2016;**95**(42):e5193
- [52] Montano N, Conforti G, Di Bonaventura R, et al. Advances in diagnosis and treatment of trigeminal neuralgia. *Therapeutics and Clinical Risk Management*. 2015;**11**:289-299
- [53] Maarbjerg S, Wolfram F, Gozalov A, et al. Significance of neurovascular contact in classical trigeminal neuralgia. *Brain*. 2015;**138**(2):311-319
- [54] Docampo J, Gonzalez N, Munoz A, et al. Neurovascular study of the trigeminal nerve at 3 t MRI. *The Neuroradiology Journal*. 2015;**28**(1):28-35
- [55] Zakrzewska JM, Linskey ME. Trigeminal neuralgia. *BMJ*. 2014;**348**:474-483
- [56] Lin W, Chen YL, Zhang QW. Vascular compression of the trigeminal nerve in asymptomatic individuals: A voxel-wise analysis of axial and radial diffusivity. *Acta Neurochirurgica*. 2014;**156**(3):577-580
- [57] DeSouza DD, Hodaie M, Davis KD. Abnormal trigeminal nerve microstructure and brain white matter in idiopathic trigeminal neuralgia. *Pain*. 2014;**155**(1):37-44
- [58] DeSouza DD, Davis KD, Hodaie M. Reversal of insular and microstructural nerve abnormalities following effective surgical treatment for trigeminal neuralgia. *Pain*. 2015;**156**(6):1112-1123
- [59] Moisset X, Villain N, Ducreux D, et al. Functional brain imaging of trigeminal neuralgia. *European Journal of Pain*. 2011;**15**(2):124-131
- [60] Hadjikhani N, Ward N, Boshyan J, et al. The missing link: Enhanced functional connectivity between amygdala and viscerosensitive cortex in migraine. *Cephalalgia*. 2013;**33**(15):1264-1268
- [61] Wang Y, Zhang X, Guan Q, et al. Altered regional homogeneity of spontaneous brain activity in idiopathic trigeminal neuralgia. *Neuropsychiatric Disease and Treatment*. 2015;**11**:2659-2666
- [62] Flor H. Cortical reorganisation and chronic pain: Implications for rehabilitation. *Journal of Rehabilitation Medicine*. 2003;**5**(41):66-72
- [63] Foell J, Bekrater-Bodmann R, Diers M, et al. Mirror therapy for phantom limb pain: Brain changes and the role of body representation. *European Journal of Pain*. 2014;**18**(5):729-739
- [64] Flor H, Elbert T, Knecht S, et al. Phantom-limb pain as a perceptual correlate of cortical reorganization following arm amputation. *Nature*. 1995;**375**(6531):482-484
- [65] Jutzeler CR, Curt A, Kramer JL. Relationship between chronic pain and brain reorganization after deafferentation: A systematic review of functional MRI findings. *NeuroImage. Clinical*. 2015;**9**:599-606
- [66] Dettmers C, Adler T, Rzanny R, et al. Increased excitability in the primary motor cortex and supplementary motor area in patients with phantom limb pain after upper limb amputation. *Neuroscience Letters*. 2001;**307**(2):109-112
- [67] Lotze M, Flor H, Grodd W, et al. Phantom movements and pain. An fMRI

study in upper limb amputees. *Brain*. 2001;**124**(11):2268-2277

[68] Gustin SM, Wrigley PJ, Henderson LA, et al. Brain circuitry underlying pain in response to imagined movement in people with spinal cord injury. *Pain*. 2010;**148**(3):438-445

[69] Diers M, Christmann C, Koeppe C, et al. Mirrored, imagined and executed movements differentially activate sensorimotor cortex in amputees with and without phantom limb pain. *Pain*. 2010;**149**(2):296-304

[70] Cauda F, Sacco K, D'Agata F, et al. Low-frequency BOLD fluctuations demonstrate altered thalamocortical connectivity in diabetic neuropathic pain. *BMC Neuroscience*. 2009;**10**:138

[71] Cifre I, Sitges C, Fraiman D, et al. Disrupted functional connectivity of the pain network in fibromyalgia. *Psychosomatic Medicine*. 2012;**74**(1):55-62

[72] Liu J, Hao Y, Du M, et al. Quantitative cerebral blood flow mapping and functional connectivity of postherpetic neuralgia pain: A perfusion fMRI study. *Pain*. 2013;**154**(1):110-118

[73] Craddock RC, Holtzheimer PE, Hu XP, et al. Disease state prediction from resting state functional connectivity. *Magnetic Resonance in Medicine*. 2009;**62**(6):1619-1628

[74] Tracey I. Getting the pain you expect: Mechanisms of placebo, nocebo and reappraisal effects in humans. *Nature Medicine*. 2010;**16**(11):1277-1283

[75] Basbaum AI, Bautista DM, Scherrer G, et al. Cellular and molecular mechanisms of pain. *Cell*. 2009;**139**(2):267-284

[76] Bosshard SC, Baltes C, Wyss MT, et al. Assessment of brain responses

to innocuous and noxious electrical forepaw stimulation in mice using BOLD fMRI. *Pain*. 2010;**151**(3):655-663

[77] Vogt BA, Finch DM, Olson CR. Functional heterogeneity in cingulate cortex: The anterior executive and posterior evaluative regions. *Cerebral Cortex*. 1992;**2**(6):435-443

[78] Vogt BA, Sikes RW. The medial pain system, cingulate cortex, and parallel processing of nociceptive information. *Progress in Brain Research*. 2000;**122**:223-235

[79] Scrivani S, Wallin D, Moulton EA, et al. A fMRI evaluation of lamotrigine for the treatment of trigeminal neuropathic pain: Pilot study. *Pain Medicine*. 2010;**11**(6):920-941

[80] De Ridder D, Vanneste S, Van Laere K, et al. Chasing map plasticity in neuropathic pain. *World Neurosurgery*. 2013;**80**(6):901-905

[81] De Ridder D, Elgoyhen AB, Romo R, et al. Phantom percepts: Tinnitus and pain as persisting aversive memory networks. *Proceedings of the National Academy of Sciences of the United States of America*. 2011;**108**(20):8075-8080

[82] Glasser MF, Coalson TS, Robinson EC, et al. A multi-modal parcellation of human cerebral cortex. *Nature*. 2016;**536**(7615):171-178