
Initial Clinical Evaluation of Observer Performance Using a Tablet Computer with a 4K High-Resolution Display for Detection of Breast Cancer by Digital Mammography

Ryusuke Murakami, Nachiko Uchiyama,
Hitomi Tani and Shinichiro Kumita

Additional information is available at the end of the chapter

<http://dx.doi.org/10.5772/intechopen.69074>

Abstract

Purpose: To compare observer performance using medical-purpose 5-megapixel liquid crystal display monitors (5-MP LCDs) and a tablet PC with a 4K high-resolution display for detection of breast cancer by digital mammography. **Materials and methods:** Mammograms from 40 patients with primary breast cancer (18 mass, 16 microcalcifications, 3 artificial distortions, and 3 focal asymmetries) and 60 control patients were consecutively collected. Four experienced radiologists assessed 100 mammograms to rate using the BI-RADS lexicon. The BI-RADS assessments were subjected to receiver operating characteristic (ROC) curve analysis. Also, the observers assessed the image quality in terms of brightness, contrast, sharpness, and noise using 5-step Likert scale. **Results:** The average under the curve (AUC) values for use of the 5-MP LCDs and 4K monitors were 0.921 and 0.936; the difference between them was small and not significant. In terms of image quality, the 4K was rated better for brightness, contrast, and sharpness. **Conclusion:** Observer performance for detecting breast cancer on a 4K tablet PC with a high-resolution display is similar to that using a 5-MP LCD. This appears adequate for displaying mammograms of diagnostic quality and could be useful for patient consultations, clinical demonstrations, or educational and teaching purposes.

Keywords: breast cancer, mammography, soft-copy, tablet PC, 4K

1. Introduction

Since the introduction of the Apple iPad in April 2010, the use of the mobile tablet PC has increased rapidly and such devices now comprise a major portion of the PC market.

With new developments in technology, opportunities for the use of tablet PCs in hospitals for management or diagnosis have increased because of the great advantages they have in terms of portability and applications for teleradiology [1–4]. An increasing number of reports have compared the use of mobile device screens with liquid-crystal displays (LCDs) for diagnosis, and the accuracy of the former is now considered to be almost equal to that of the latter, or at least acceptable, for MRI diagnosis of spinal injury, radiography and CT diagnosis of intracranial hemorrhage and orthopedic injury, and CT diagnosis of pulmonary embolism [5–8].

The viewing of digital mammograms using a soft-copy reading device has many advantages in terms of image display, better handling, postprocessing capability, computer-assisted diagnosis, archiving of image information, and image data transmission [9]. High-grade (so-called medical purpose) LCDs, such as the 5-megapixel (MP) LCD, are recommended for soft-copy reading in digital mammography [10–12].

Recently, a high-resolution 4K color display has also been developed and is commercially available. 4K resolution refers to a display device or content having a horizontal resolution in the order of 4000 pixels. Several examples of 4K resolution exist in the fields of digital television and digital cinematography. To our knowledge, however, there is no definite consensus as to whether a 4K high-resolution display monitor would be acceptable for reading of mammograms. In terms of access, portability and cost effectiveness, it would be useful to clarify whether 4K images actually afford better diagnostic accuracy.

The purpose of this study was to assess the observer performance of 4K tablet PCs with a high-resolution calibrated grayscale display monitor for detection of breast cancers on digital mammograms, in comparison with 5-MP LCDs.

2. Methods and materials

2.1. Mammogram selection

The study cohort included 40 cases surgically verified and pathologically proven breast cancers (mean age, 51.2 years; age range, 29–83 years). Histologic analysis demonstrated invasive ductal carcinoma in 25 cases, ductal carcinoma *in situ* in 10, and special type in 5. The median size of the lesions revealed by pathologic examination was 18.3 mm (range 3–45 mm). In addition, 60 cases (mean age, 48.4 years; age range, 28–82 years) including 48 with normal breast findings and 12 with benign conditions (mastopathy in 6; cyst in 3; fibroadenoma in 2; papilloma in 1) were selected. Mention this in abstract as well. Finally, 100 cases (48 normal, 40 with cancer, and 12 with benign lesions) were examined. ACR BI-RADS for density, a predetermined breast density distribution was followed when selecting the cases: 10 were for cases with extremely dense breasts, 55 with heterogeneously dense breasts, 30 with scattered fibroglandular tissue, and 5 with entirely fatty breasts.

2.2. Image acquisition and display

Mammograms were acquired using a flat-panel digital mammography system (Senographe DS LaVerite; GE Healthcare). The spatial resolution was 100 μm per pixel (pixel dimension: 1800 \times 2304) and the contrast resolution was 14 bits.

The images were displayed on two types of display: (i) two monochrome 5-MP LCDs (MFGD5621HD, 2048 \times 2560 pixels, 21.3 inch; BARCO); and (ii) two commercially available 4K tablet PCs with high-resolution color monitors (4K UT-MA6, 2560 \times 3840 pixels, 20.8 inch; Panasonic) (**Figures 1 and 2**).

The physical properties of the two types of monitors are shown in **Table 1**.

The displays run with the PACS software (We VIEW Z; HITACHI) and viewing software specialized for MGs (Plissimo MG, Panasonic). The luminance of both monitors was calibrated as recommended by the suppliers and at the start of the reading test.

2.3. Image interpretation

Four board-certified radiologists assessed the mammograms in a dark environment (<10 lux). Each of the observers independently assessed 200 images (100 patients \times 2 sides; MLO and CC views). The observers were asked to rate the images on the level of confidence using the BI-RADS lexicon: 1, negative; 2, benign; 3, probably benign; 4, suspicious; and 5, highly suggestive of malignancy.

In addition, on another occasion, the observers assessed the image quality in terms of brightness, contrast, sharpness, and noise, side-by-side for the 5-MP LCDs versus the 4K tablet PCs (5-step Likert scale, -2 = 5-MP definitely better and +2 = 4K definitely better).



Figure 1. 4k UT-MA6 (TOUGHPAD) 20.8 inches; Panasonic.

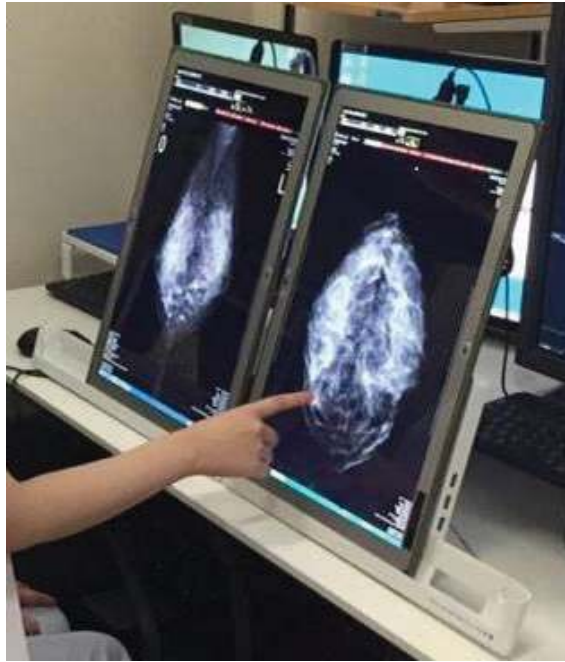

Figure 2. Two sets of 4K tablet PCs with high-resolution color monitors (4K UT-MA6, 2560 × 3840 pixels, 20.8 inch; Panasonic).

	Screen size	Matrix size	Color	Maximum luminance (cd/m ²)	Contrast ratio	Product name (manufacturer)
4K tablet PC	20.8 (inches)	2560 × 3840	Color	300	850:1	UT-MA6 (Panasonic)
5-MP LCD	21.3 (inches)	2048 × 2560	Monochrome	450	800:1	MFGD5621HD (Barco)

Table 1. The physical properties of the 5-MP LCDs and 4K display monitors used in comparison with observer performance.

2.4. Data and statistical analysis

The observers' detection performance was evaluated using receiver operating characteristic (ROC) curve analysis. The confidence level results were used to construct ROC curves. This allowed to obtain the sensitivity, specificity, positive predictive value (PPV), negative predictive value (NPV), and accuracy of each monitor. Image quality ratings were tabulated for each reader and summarized across all readers. The confidence interval (CI) for the proportion of 4K ratings as similar (0), slightly better (± 1), or better (± 2) was obtained, considering the side-by-side comparison to be a single test condition. In the statistical analysis, differences at $P < 0.05$ were considered to be statistically significant.

3. Results

Table 2 and **Figure 3** show the average under the curve (AUC) values and ROC curves for detection of breast cancers using the 5-MP LCDs and the 4K tablet PCs, respectively. The mean AUC values for use of the 5-MP LCDs and the 4K tablet PCs were 0.921 and 0.936, respectively. The difference was not statistically significant ($P = 0.27$). Sensitivity, specificity, positive and negative predictive values, and accuracy were comparable (**Table 3**).

	BI-LADS	
	5-MP LCD	4K
Reader 1	0.858	0.903
Reader 2	0.932	0.954
Reader 3	0.945	0.945
Reader 4	0.949	0.958
Mean	0.921	0.936

Table 2. The area under the ROC curve for the 5-MP and 4K in BI-RADS scores.

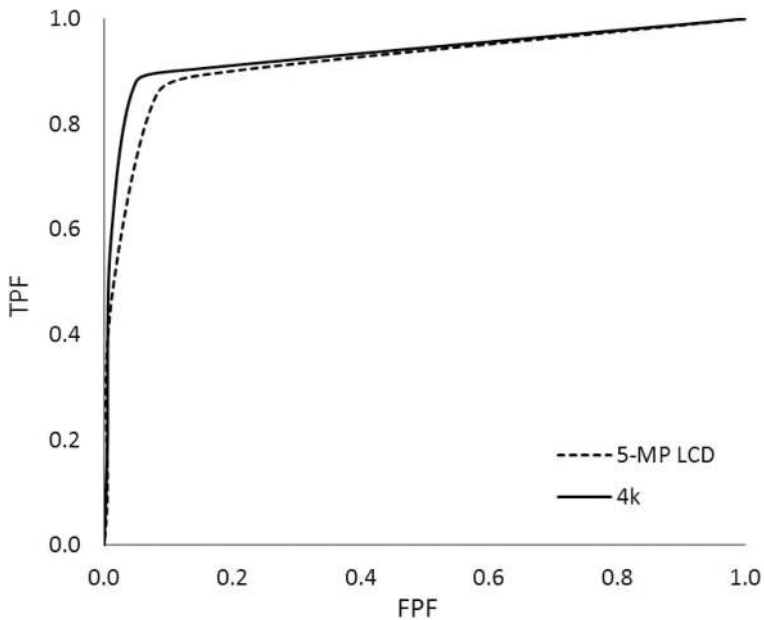


Figure 3. ROC curves for the detection of breast cancers. FPF, false positive fraction; TPF, true positive fraction. The thick line shows the ROC curve for a set of 4K tablet PC with high-resolution color monitors and the dashed line shows the ROC curve for a set of 5-MP LCDs. There was no significant difference between the two types of display modes ($P = 0.27$).

	5-MP LCD	4K
Sensitivity	0.857 (0.863/0.956)	0.881 (0.788/0.937)
Specificity	0.918 (0.889/0.936)	0.963 (0.939/0.978)
PPV	0.735 (0.643/0.794)	0.860 (0.769/0.915)
NPV	0.960 (0.931/0.980)	0.969 (0.945/0.984)
Accuracy	0.905 (0.860/0.934)	0.946 (0.908/0.969)

Table 3. Sensitivity, specificity, positive and negative predictive values and accuracy with the 5-MP and 4K.

With regard to image quality, brightness for the 4K tablet PC was rated as similar to that of the 5-MP LCD in 12% of the study readings, slightly better in 54%, and better in 27%. Contrast for the 4K tablet PC was rated as similar to that of the 5-MP LCD in 26% of the study readings, slightly better in 40%, and better in 15%. Sharpness for the 4K tablet PC was rated as similar to that of the 5-MP LCD in 38% of the study readings, slightly better in 26%, and better in 12%. Noise for the 4K tablet PC was rated as similar to that of the 5-MP LCD in 85% of the study readings, and slightly better in 5% (Table 4 and Figure 4). Figures 5–8 demonstrated breast cancers displayed on 5-MP and 4K monitors.

	4K better (+2)	4K slightly better (+1)	Similar (0)	5-MP slightly better (-1)	5-MP better (-2)	Mean	Lower 95% CL	Upper 95% CL
Brightness	27	54	12	7	0	1.00	0.84	1.16
Contrast	15	40	26	19	0	0.51	0.32	0.70
Sharpness	12	26	38	24	0	0.26	0.07	0.45
Noise	0	5	85	10	0	-0.05	-0.13	0.03

Table 4. Image quality on the basis of brightness, contrast, sharpness and noise, for side-by-side feature visibility rating with 5-MP versus 4K. Values are presented as numbers (also percentages). Mean is average preference by percentage. Positive numbers indicate a preference for 4K and negative numbers indicate a preference for 5-MP. CL; confidence limits.

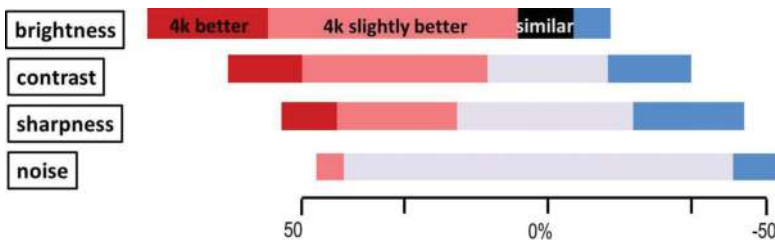


Figure 4. Likert scale scores (n = 100 eligible patients). Image quality on the basis of brightness, contrast, sharpness, and noise, for side-by-side feature visibility rating with 4K and 5-MP LCD. Values are presented as percentages.

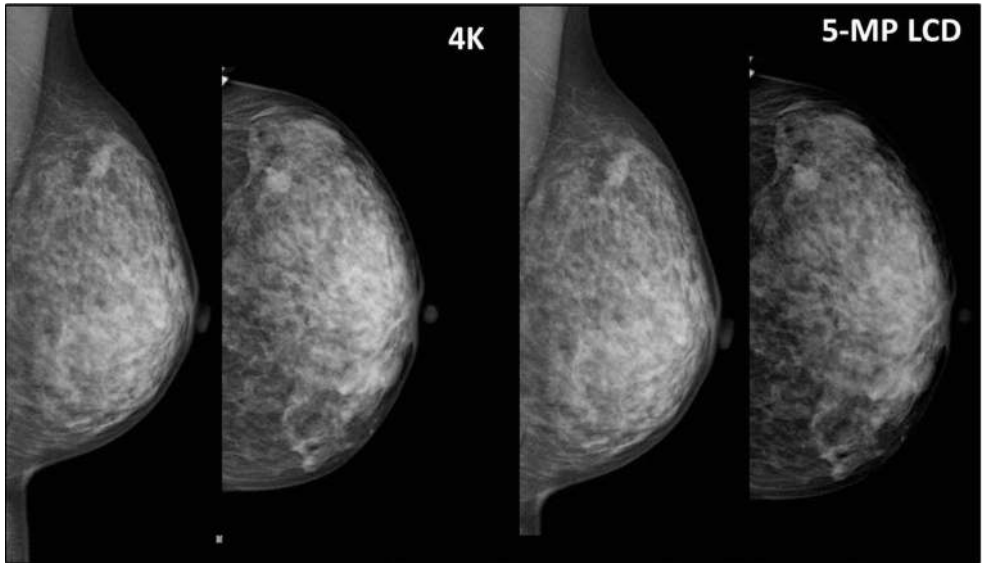


Figure 5. Microlobulated mass in the left upper area *captured images.

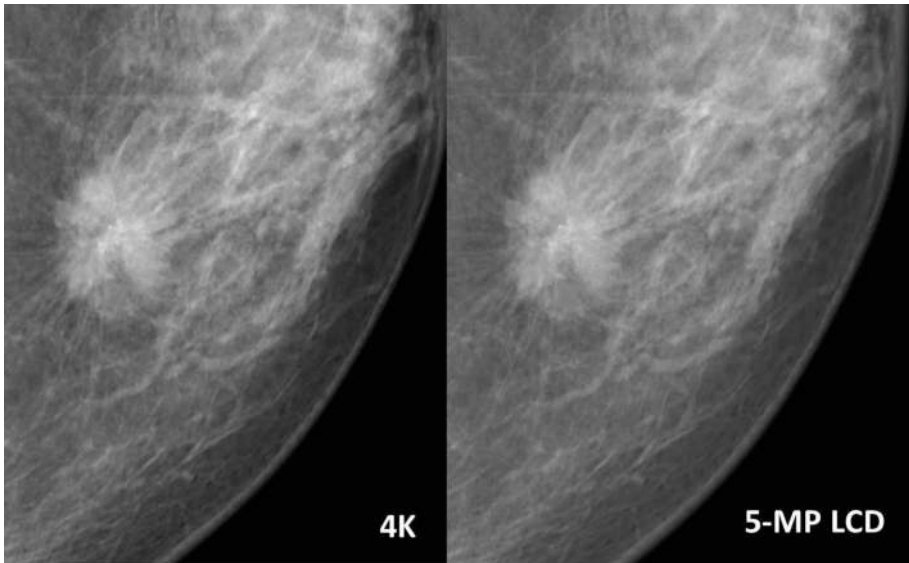


Figure 6. Spiculated mass *captured images.

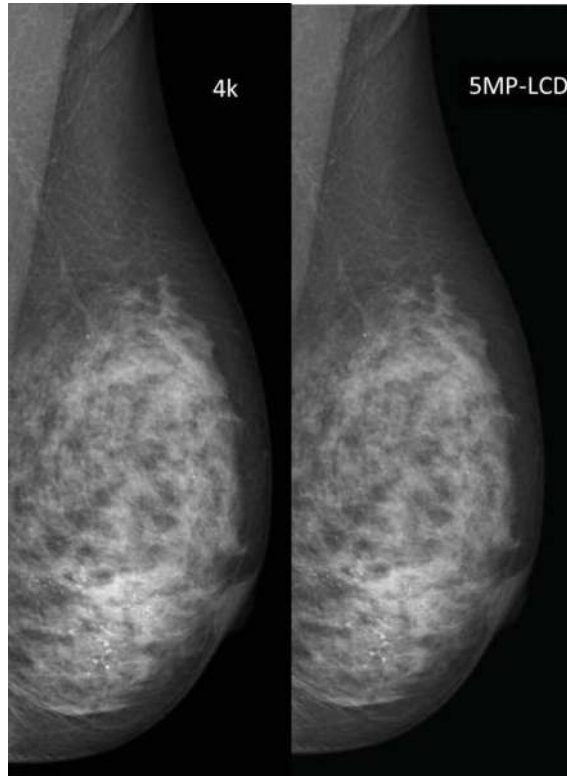


Figure 7. Finelinear branching calcifications in the left lower area *captured images.

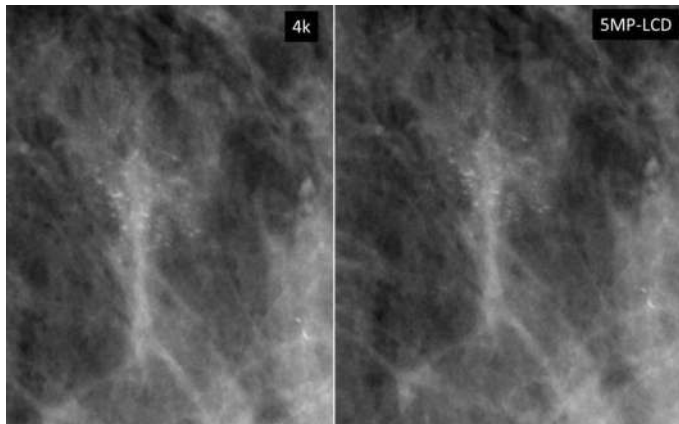


Figure 8. Amorphous grouped calcifications *captured images.

4. Discussion

The purpose of the present study using images from actual patients was to obtain initial data to indicate whether or not the newer tablet PCs with a 4K high-resolution color display monitor could be deployed for mammographic imaging. Only one previous study has evaluated the display quality of tablet PCs [13]. This study represented the first attempt to evaluate the display quality of tablet PCs (iPad 2 and 3) with a dedicated 10-MP LCD using a standardized CDMAM phantom. It was concluded that the evaluated iPads, especially version 3, would likely be adequate for display of diagnostic-quality mammograms [13].

Our present study found no significant difference between the performances of the 5-MP LCDs and the 4K tablet PCs for detecting breast cancers on mammograms. Moreover, in terms of the image quality, 4K tablet PCs were rated as having better brightness, contrast, and sharpness. This is the first confirmation that observer performance for detection of breast cancers using soft-copy readings on digital mammograms is comparable between the current standard 5-MP LCDs and 4K tablet PCs with a high-resolution display monitor. The 4K tablet PC seems suitable for displaying mammograms in a variety of tasks such as patient consultation, clinical demonstrations, or educational and teaching purposes, and its large high-resolution screen seems to meet the legal requirements. As many patients are interested in taking a look at their images, one of the most promising applications of tablet PC-based mammographic display would be patient consultation. This would give patients a clearer idea of their disease and might have a positive impact on patient compliance.

The greatest benefits of the 4K tablet PC with a high-resolution display monitor are its low cost and possible application for multiple purposes, such as reporting systems and referencing of color images including endoscopic, PET/CT, and SPECT/CT images. In addition, the performance of 4K high-resolution color display monitors has recently improved, and they now have high-resolution (5-MP or more) capability, as is the case for medical LCDs. However, the development of tablet PCs is progressing rapidly; the 4K display used in the present study might now be considered a relatively old model. If the 4K display is suitable for medical display purposes, the cost would increase.

5. Conclusion

Our findings suggest that observer performance for detection of breast cancers on digital mammograms using 4K tablet PCs with a high-resolution display monitor is comparable to that obtained using 5-MP LCDs. Therefore, 4K tablet PCs, as a result of the advanced technology, might be adequate for diagnostic-quality mammogram display and could be useful for patient consultation, clinical demonstration, or educational and teaching purposes. Because of the promising potential advantages of tablet PCs, such as their portability, further assessments of their potential clinical use are warranted.

Author details

Ryusuke Murakami^{1*}, Nachiko Uchiyama², Hitomi Tani¹ and Shinichiro Kumita¹

*Address all correspondence to: rywakana@nms.ac.jp

1 Department of Radiology, Nippon Medical School, Tokyo, Japan

2 Department of Radiology, National Cancer Center, Tokyo, Japan

References

- [1] Volonté F, Robert JH, Ratib O, Triponez F. A lung segmentectomy performed with 3D reconstruction images available on the operating table with an iPad. *Interactive CardioVascular and Thoracic Surgery*. 2011;**12**:1066-1068
- [2] Mc Laughlin P, Neill SO, Fanning N, Mc Garrigle AM, Connor OJ, Wyse G, Maher MM. Emergency CT brain: Preliminary interpretation with a tablet device—Image quality and diagnostic performance of the Apple iPad. *Emergency Radiology*. 2012;**19**:127-133
- [3] Takao H, Murayama Y, Ishibashi T, Karagiozov KL, Abe T. A new support system using a mobile device (smartphone) for diagnostic image display and treatment of stroke. *Stroke*. 2012;**43**:236-239
- [4] Yoshimura K, Nihashi T, Ikeda M, Ando Y, Kawai H, Kawakami K, Kimura R, Okada Y, Okochi Y, Ota N, Tsuchiya K, Naganawa S. Comparison of liquid crystal display monitors calibrated with gray-scale standard display function and with γ 2.2 and iPad: Observer performance in detection of cerebral infarction on brain CT. *American Journal of Roentgenology*. 2013;**200**:1304-1309
- [5] John S, Poh AC, Lim TC, Chan EH, Chong LR. The iPad tablet computer for mobile on-call radiology diagnosis? Auditing discrepancy in CT and MRI reporting. *Journal of Digital Imaging*. 2012;**25**:628-634
- [6] McNulty JP, Ryan JT, Evanoff MG, Rainford LA. Flexible image evaluation: iPad versus secondary-class monitors for review of MR spinal emergency cases—A comparative study. *Academic Radiology*. 2012;**19**:1023-1028
- [7] Toomey RJ, Ryan JT, McEntee MF, Evanoff MG, Chakraborty DP, McNulty JP, Manning DJ, Thomas EM, Brennan PC. Diagnostic efficacy of handheld devices for emergency radiology consultation. *American Journal of Roentgenology*. 2010;**194**:469-474
- [8] Johnson PT1, Zimmerman SL, Heath D, Eng J, Horton KM, Scott WW, Fishman EK. The iPad as a mobile device for CT display and interpretation: Diagnostic accuracy for identification of pulmonary embolism. *Emergency Radiology*. 2012;**19**:323-327
- [9] Kamitani T, Yabuuchi H, Matsuo Y, Setoguchi T, Sakai S, Okafuji T, Sunami S, Hatakenaka M, Ishii N, Kubo M, Tokunaga E, Yamamoto H, Honda H. Diagnostic performance in

- differentiation of breast lesion on digital mammograms: Comparison among hard-copy film, 3-megapixel LCD monitor, and 5-megapixel LCD monitor. *Clinical Imaging*. 2011;**35**:341-345
- [10] Yamada T, Suzuki A, Uchiyama N, Ohuchi N, Takahashi S. Diagnostic performance of detecting breast cancer on computed radiology (CR) mammograms: Comparison of hard copy film, 3-megapixel liquid-crystal-display (LCD) monitor and 5-megapixel LCD monitor. *European Radiology*. 2008;**18**:2363-2369
- [11] Schueller G, Schueller-Weidekamm C, Pinker K, Memarsadeghi M, Weber M, Helbich TH. Comparison of 5-megapixel cathode ray tube monitors and 5-megapixel liquid crystal monitors for soft-copy reading in full-field digital mammography. *European Journal of Radiology*. 2010;**76**:68-72
- [12] Yabuuchi H, Kawanami S, Kamitani T, Matsumura T, Yamasaki Y, Morishita J, Honda H. Detectability of BI-RADS category 3 or higher breast lesions and reading time on mammography: Comparison between 5-MP and 8-MP LCD monitors. *Acta Radiologica*. 2017;**58**:403-407
- [13] Hammon M, Schlechtweg PM, Schulz-Wendtland R, Uder M, Schwab SA. iPads in breast imaging—A phantom study. *Geburtshilfe Frauenheilkd*. 2014;**74**:152-156

