
Canine Visceral Leishmaniasis in Brazil

Marcia Almeida de Melo, Raizza Barros Sousa Silva,
Laysa Freire Franco e Silva,
Beatriz Maria de Almeida Braz,
Jaqueline Maria dos Santos,
Saul José Semião Santos and
Paulo Paes de Andrade

Additional information is available at the end of the chapter

<http://dx.doi.org/10.5772/65956>

Abstract

Visceral leishmaniasis (VL) is a disease caused by a protozoon belonging to the genus *Leishmania*, and it is transmitted through the bite of sand flies. Endemic regions have widened, and canine visceral leishmaniasis (CVL) occurs mainly in the Mediterranean region and South America. There is no consensus on the risk factors associated with CVL, as results differ between the studied regions and countries. This chapter describes the main aspects of epidemiology, immunology, clinical signs, diagnosis treatment, and control of canine visceral leishmaniasis with emphasis on Brazil.

Keywords: neglected diseases, risk factors, zoonosis

1. Introduction

Leishmaniasis is a disease caused by protozoan intracellular parasites called *Leishmania*, members of Trypanosomatidae family, and are endemics in 98 countries and territories.

More than 20 parasite species are involved in the three different clinical manifestation diseases in human beings: cutaneous leishmaniasis, mucosal leishmaniasis, and visceral leishmaniasis (kala-azar). Post-kala-azar dermal leishmaniasis (PKDL) is a complication of visceral leishmaniasis in a patient who has recovered from the disease. The vectors are sand flies, insects of medical and veterinary relevance, and different species involved in its transmission.

According to Pan American Health Organization (PAHO) and World Health Organization (WHO), there are more than 12 million people infected with leishmaniasis, and 350 million are at risk in the world. Cutaneous leishmaniasis are concentrated in ten countries, four of which are in the Americas: Brazil, Colombia, Peru, and Nicaragua. Ninety percent of visceral leishmaniasis cases occur in Brazil, Ethiopia, India, Bangladesh, Sudan, and South Sudan. In the Americas, an average 60,000 cases of cutaneous and mucosal leishmaniasis and 4000 cases of visceral leishmaniasis are diagnosed annually, with a fatality rate of 7% (**Figure 1**) [1].

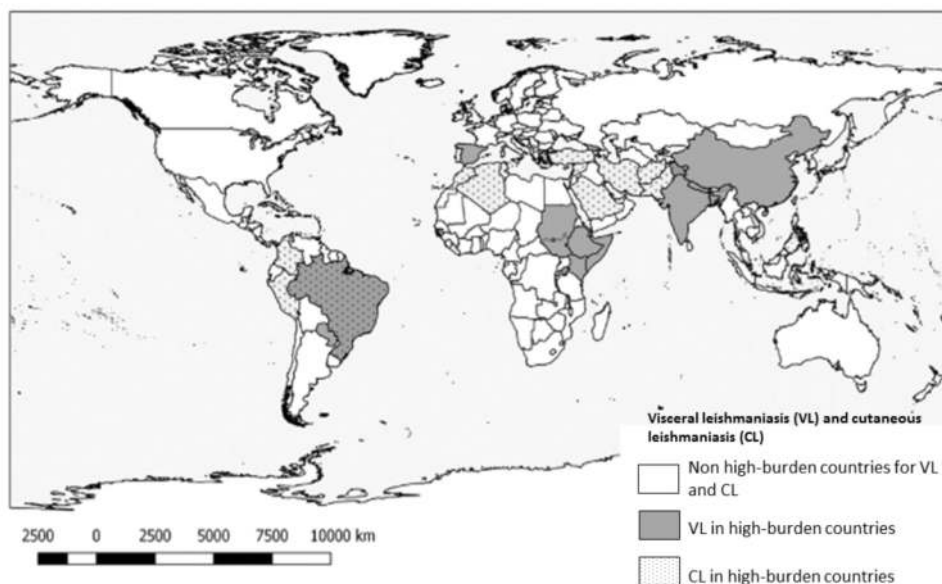


Figure 1. High-burden countries for both visceral and cutaneous leishmaniasis [2].

The aim of this chapter is to describe the main aspects of canine visceral leishmaniasis (CVL) with emphasis in Brazil.

2. Epidemiology

Visceral leishmaniasis (VL), also known as kala-azar, is a disease caused by an obligate intracellular protozoan belonging to the family Trypanosomatidae, genus *Leishmania*. It is transmitted through the bite of infected female sand flies and is widely distributed throughout the world (**Figure 2**). Currently, the World Health Organization considers VL as a neglected disease. An estimated 500,000 new cases of human VL occur per year [2]. Its epidemiology is extremely complex and depends on social and environmental variables, the species of *Leishmania* and the vector involved, and the behavior of reservoirs and hosts (**Table 1**).

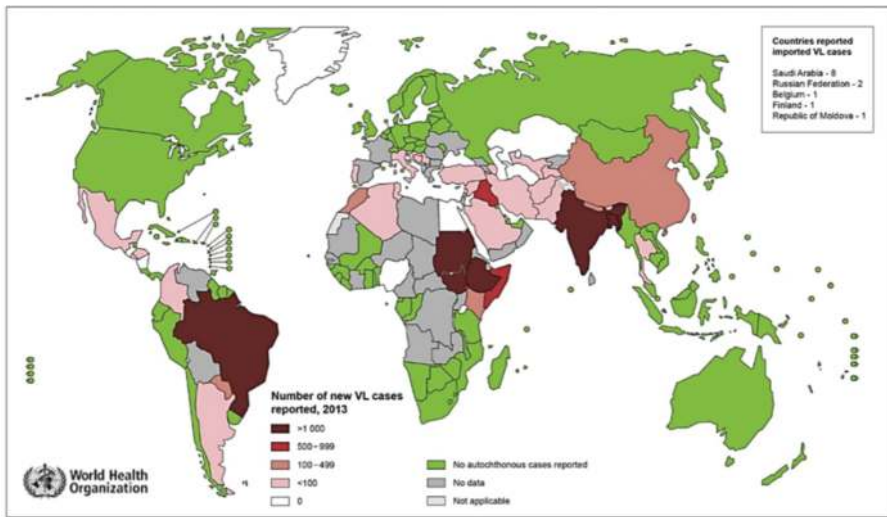


Figure 2. World distribution of human visceral leishmaniasis, 2013 [3].

Species	Region	Vector	Host/reservoir
<i>Leishmania (L.) infantum</i>	Old World:	<i>Phlebotomus perniciosus</i>	Humans
	Europe	<i>P. ariasi</i>	Dogs
	Asia		Wild canids
	Africa		
<i>Leishmania (L.) donovani</i>	Old World:	<i>P. argentipes</i>	Humans
	Asia	<i>P. orientalis</i>	
	Africa		
<i>Leishmania (L.) infantum</i> (syn. of <i>L. chagasi</i>)	New World:	<i>Lutzomyia longipalpis</i>	Humans
	South, Central, and North America	<i>Lu. cruzi</i>	Dogs
		<i>Lu. forattinii</i>	Wild canids
		<i>Lu. evansi</i>	Felines Marsupials

Adapted with permission from Refs. [4–6].

Table 1. Visceral leishmaniasis: species, region of occurrence, vectors, reservoirs, and mammal hosts.

2.1. Biological cycle

The life cycle of *L. infantum* is heteroxenic, that is, the parasite develops in two types of hosts: in the intermediate host, or the vector, the promastigote form develops in the insect gut; once in the definitive host, the amastigote develops as an obligate intracellular parasite in macrophages. During blood meals, vectors ingest macrophages containing *Leishmania* amastigotes,

which will then multiply by binary division and differentiate into promastigotes. Promastigotes bind to the epithelium of the sand fly's esophagus or pharynx by the flagellum and then differentiate into metacyclic promastigotes, which is the infectious stage, unable to divide or bind to the midgut, remaining free in the digestive tract lumen [5, 7, 8].

Transmission occurs when the infected vector does a new blood meal and inoculates the infective form of *Leishmania* in the host. The sand fly regurgitates around 1000 metacyclics into the wound caused on the skin of a mammal [9]. When inoculated into the host organism, the parasite is phagocytized by the cells of mononuclear phagocytic system and loses the flagella. Next, it multiplies intensively by binary division, to the point of rupturing the host cell and releasing amastigotes, which then will be phagocytized by other cells and spread via blood and lymph to other tissues and organs [5, 7, 8].

2.2. Vector

VL vectors belong to the order Diptera, family Psychodidae, subfamily Phlebotominae, genus *Lutzomyia* in the new world, and *Phlebotomus* in the Old World. They can be found in tropical and subtropical regions of the planet and are popularly known as sand flies [10, 11].

Sand flies are small-sized, light brown-colored insects, with a coat of hair over their body. They measure between 2 and 3 mm [11]. Their flight range reaches about 150–300 m (diameter of 300–600 m), but may be longer depending on the species. They usually fly in small jumps and have crepuscular and nocturnal activity [12].

Hematophagy is a unique habit of females, who require blood for ovary maturation. Hence, they are able to transmit the disease. When females feed on blood, they hold their wings upright. A variety of animals has been identified as dietary hosts of sand flies, which have very eclectic feeding habits. Females lay eggs in moist soil, rich in organic matter [13].

2.3. Transmission

VL caused by *L. infantum* is a zoonosis and can display either wild or domestic transmission cycles depending on the eco-epidemiological conditions.

Leishmaniasis starts from the wild cycle, involving reservoirs such as wild canids and marsupials. As for the domestic cycle, the main reservoir is the domestic dog (*Canis lupus familiaris*) [7]. The link between wild and domestic cycles occurs when humans install dwellings on forest banks [14] and, most likely, because some wild reservoirs have synanthropic habits (**Figure 3**) [15].

Canine visceral leishmaniasis (CVL) is crucial from an epidemiological point of view, as it is more prevalent than human VL. Dogs exhibit high levels of subcutaneous parasites and high sensitivity to vectorial infection [12]. Additionally, between 50 and 60% of infected animals are asymptomatic [16]. It is estimated that three out of five asymptomatic positive dogs transmit the parasite to sand flies, and this transmission rate does not significantly change among symptomatic and asymptomatic groups of animals [17].

Other animals have been pointed as possible reservoirs, such as rodents [14] and cats, or accidental hosts, such as horses [18]. Adaptation of vectors to different animal species would be a favorable factor for VL transmission [19].




Figure 3. Eco-epidemiology of visceral leishmaniasis in Pará, Brazil. *L. infantum* parasite is maintained by a sand fly population (*Lutzomyia longipalpis*) and wild reservoirs (1). House invasion by sand flies near forests allows canine and human infection (2 and 3), where domestic dogs become the main source of the parasite. The same occurs in the urban areas. Solid lines indicate defined routes of transmission, and dashed lines represent possible transmission routes with other wildlife, and possibly with man, serving as a source of infection for sand flies [14].

There are other transmission forms of less epidemiological importance, such as blood transfusion and venereal transmission, apart from vertical transmission, which can be transplacental or transmammary [20–23]. Direct dog-to-dog transmission through bites or wounds has been suggested as responsible for sporadic CVL transmission as well [24, 25].

2.4. Geographic distribution and prevalence

In recent years, endemic regions have widened, and there has been a sharp increase in number of recorded cases of the disease. Still, it is believed that the impact of leishmaniasis on public health has been underestimated, since its notification is only mandatory in 32 of the 88 affected countries [2]. CVL is endemic in over 70 countries and occurs mainly in the Mediterranean region and South America [26]. Moreno and Alvar concluded that at least 2.5 million dogs are infected in only four countries in Southeastern portion of Western Europe, representing 16.7% of the canine population [27].

Franco et al. [28] developed a database of publications on the prevalence of LVC in Europe between the years 1971 and 2006. They found an overall prevalence of 23.2% and average of 10%, the highest taking place in Italy (17.7%), followed by France (8%), Portugal (7.3%), and Spain (5.9%) [28]. In another study, in 18 Portuguese cities with 3974 dogs, the overall

prevalence of CVL was of 6.31% and ranged from 0.88% to 16.16% among cities, with high prevalence in inland regions [29].

In Croatia, seroprevalence of CVL ranges from 0 to 42.85% depending on the studied region [30]. In Cyprus, the seroprevalence of the disease in dogs had a ninefold increase compared to 10 years before, reaching 14.9% in 2010 [31]. The average seropositivity of dogs in Greece is 22.1%, and positive animals were found in 43 of 54 cities [32].

Seroprevalence of CVL in Southern Europe ranges from less than 5% to over 50% depending on the geographic region [33]. However, the prevalence of infection is significantly higher than both seroprevalence and apparent disease, due to sensitivity of serological techniques and because clinical signs usually only appear in less than half of the population, as in all endemic areas of the world [34].

Recent expansion to areas not previously endemic has been recorded in some parts of Europe, as northern Italy [35], in Germany [36], and in northern Spain [37]. The expansion of the CVL is associated with adjacent territories and often with global warming, which favors vector transmission, or with import of infected dogs to non-endemic areas, such as the United Kingdom and Poland [26, 33].

In Africa, VL transmission areas are located near forests [12]. Most of the information published in Africa have often been reports of human cases during epidemic situations, but information on the reservoirs are scarce [38]. In Algeria, the number of cases of CVL is on the rise, with a frequency of 35%, with 25% of positive dogs being asymptomatic [39]. Coastal regions of Northern Morocco are known to be endemic for canine and human VL. Moreover, several cases of CVL caused by *L. tropica* have been reported in areas where it is normally caused by *L. infantum* [40].

CVL exists in some Asian countries. It is endemic in Iran, with an average prevalence of 14.2%, and variations according to the region: 18.2% in northeast, 12.3% in the central region, and 4.4% in Southeastern Iran [41]. Another study, restricted to southwestern Iran, found a prevalence of 15.4% [42]. In China, VL is an anthroponosis which completes its life cycle in dogs, raccoons, coatis, and children [12]. The presence of *L. infantum* DNA in dogs, in Southwest China, ranged from 23.5 to 28.2% [43]. In the Western region, 51.9% of the dogs were positive in PCR, but only 36.8% of the dogs reacted in serology [44].

CVL has been expanding over the Americas. It currently occurs from southern Canada [45] and the United States [46, 47] to northern Argentina [48, 49]. In North America, it was first reported on hunting kennels of Foxhound dogs in New York, in 1999 [46]. Since then, CVL has been spreading and has so far been diagnosed in 18 North American and two Canadian states, totaling 58 kennels with positive Foxhounds, but with no reports of human cases. Isozyme characterization showed that the isolated agents from 46 Foxhounds are *Leishmania infantum* (MON1) [45]. High mortality and transmissibility rates associate with these foci in North America. It is believed that the disease was imported from Southern Europe due to dog travel history between these regions [50]. Direct transmission forms are associated with these outbreaks: from dog to dog, via placenta or during intercourse [22]. *L. infantum*, in these cases,

remains capable of infecting sand flies and subsequently moving into a vertebrate host, which highlights the risk of vector-based transmission to humans [47].

There are few studies on CVL in Mexico, but human VL cases are constant. Rosete-Ortiz et al. analyzed skin lesions of 25 dogs by immunohistochemistry and PCR in a region where *Lutzomyia longipalpis* has been described and found *Leishmania* sp. in 60% of samples [51].

In Latin America, VL occurs in 12 countries, with 90% of cases concentrated in Brazil [11], distributed in all states of the Northeastern, Midwestern, and Southeastern regions, plus in Roraima, Tocantins, and Pará states, in the Northern region [14]. Among Brazilian cities and states, variation in prevalence of CVL is huge, ranging from 0.7% in Salvador, in the state of Bahia [52], to 51.6% in São Luis Island, Maranhão state [53], both in Northeast, where the disease is most prevalent.

CVL urbanization correlates with increasing global mobility [54] associated with demographic and ecological factors. In Latin America, especially in Brazil, Colombia, and Venezuela, migration and urbanization have contributed to the increase in American VL. In Brazil, one example is the rural exodus from the Northeast fields, causing thousands of people to migrate to cities like Fortaleza, Jacobina, João Pessoa, Natal, Petrolina, St. Louis, Sobral, Teresina, and Salvador. They then proceed to live in suburban areas with unsanitary conditions and malnutrition. Migrants often bring along their dogs and raise chicken and pigs around their homes, all ultimately serving as a feed source for the vector. According to Moreno et al., in urban areas, some factors favor the spread of *L. infantum*, such as the presence of waste and degraded areas around houses, lack of vector recognition by locals, and increased exposure to sand fly, especially in the early evening [55]. Thus, "ruralization" of the outskirts of the Northeastern cities has been identified as the cause of epidemics detected in the region [56], although this same process may not be necessary for entry of visceral leishmaniasis in other cities, as happened in the Southeast of the country.

The state of Rio Grande do Sul, Brazil, was considered CVL-free until 2008, when a case of an autochthonous canine was reported in São Borja [57]. In the same year, *Lutzomyia longipalpis* was found in urban areas of San Borja, a species not previously reported in the Southern region [58]. Since then, new cases were reported: 24 in dogs and 10 in humans between 2008 and 2014. Of these 34 reports, 20 were autochthonous, showing that it is an emerging zoonosis in the state [59]. It is believed that the disease has entered the state via Santo Tomé city in Argentina, which borders San Borja and already had reports of the disease [57, 59].

Prevalence of CVL in the world varies widely, and such variation also applies to different locations within the same city, suggesting that different ecosystems favor maintenance of vectors in different manners [60]. As noted by Azevedo et al. [61] and Belo et al. [62], results of studies on prevalence are influenced by various factors such as the region and population studied, the diagnostic method, as well as the sample used.

Migration of humans and their pets, disorderly occupation, poor living conditions, deforestation, and climate change associated with vector-adaptive capacity are some of the causes of the global urbanization of leishmaniasis [54].

The best example of the phenomenon of urbanization of zoonotic visceral leishmaniasis is happening in Brazil [54, 63]. VL has invaded urban centers and large capitals with no previous record of autochthonous cases [12]. Epidemiological data show the suburbanization and urbanization of visceral leishmaniasis, highlighting the outbreaks in Rio de Janeiro (RJ), Belo Horizonte (MG), Aracatuba (SP), Santarém (PA), Corumbá (MS), Teresina (PI), Natal (RN), São Luís (MA), Fortaleza (CE), Camaçari (BA), and more recently, occurrence of epidemics in the municipalities of Três Lagoas (MS), Campo Grande (MS), and Palmas (TO) [11].

The prevalence of human VL caused by *L. infantum* has decreased where living standards improved [2], showing that one of the most important interventions may be socioeconomic development and improved nutrition of children [8], but CVL cases have increased.

2.5. Risk factors

There is no consensus on the risk factors associated with CVL, as results differ between the studied Brazilian regions and between countries.

In Croatia, risk factors were sex (male), age (the two most prevalent groups comprise dogs between 3 and 4 years old and between 6 and 7 years old), and location (dogs in some cities are more likely to acquire the disease) [30]. In Spain, seroprevalence was also found to have bimodal age distribution, but the age groups were between 1 and 2 years and between 7 and 8 years; infection is also related to outdoor rearing [64]. In Portugal, risk factors are outdoor rearing, age (over two years), short fur, pure breeds, and location (dogs in the hinterlands are more likely to be affected) [29].

In Brazil, Belo et al. [62] conducted a systematic review of the literature on risk factors associated with CVL, and the variables that showed significant association with infection were short hair, pure breed, rearing restricted to house surroundings, and the presence of green areas adjacent to the house. The occurrence of CVL was also associated with the presence of poultry in domestic environment, free-living dogs, sex (male), and age greater than 1 or 2 years, although these associations were not statistically significant [62].

Another study in Brazil defined risk factors as outdoor rearing, contact with poultry, dogs living in rural areas, the presence of organic matter, the absence of environmental management, and proximity to forests [65]. As for dogs in the countryside, in an endemic area of Northeastern Brazil, the only identified risk factor found was sex, as male dogs were twice as likely to develop the disease [66].

3. Immunology

The components of the immune system act in a complex and coordinated manner to prevent entry and survival of foreign agents in the body. The first line of defense is the innate immunity, which responds immediately and unspecifically to a range of pathogens, and further presents them to the constituents of adaptive immunity when needed. Adaptive immunity will then generate a specific response and develop memory cells against such antigen. Performance of

these defense mechanisms can control infection and ensure the least possible damage to host tissues.

In visceral leishmaniasis, the result of the relationship between parasite and host is determined by complex factors involving saliva components of the vector insect, agent-secreted surface proteins, and different responses produced by the host [67]. Leishmaniasis can be considered an immune-mediated disease, considering the parasite's ability to alter the immune system [68]. It ultimately promotes inhibition of immune response by either stimulating the development of regulatory T cells [69] or exerting some degree of control over the complement system, exploring its opsonic properties to facilitate adherence with phagocytic cells and preventing their lytic effects through the action of gp63 glycoprotein expressed on the parasite surface [70]. Thus, infection outcome depends on the parasite's capacity of developing evasion mechanisms to escape from host responses and remain unharmed in the cytoplasm of phagocytic cells.

It has been documented that resistance to infection by *L. infantum* in dogs is characterized by the absence of clinical signs, low levels of anti-*Leishmania* antibodies, in vitro lymphocyte proliferative response, and delayed hypersensitivity response to skin antigens. Progression of the infection, however, relates to exaggerated humoral response and cellular immune depression, consequently bringing up an onset of clinical signs [71–74]. Asymptomatic animals also exhibit lower parasitism, whereas the symptomatic generally carry high parasite load in different tissues such as the skin, bone marrow, spleen, liver, and lymph node [73–76].

3.1. Innate response

Through antigen presentation, the cells of innate immunity stimulate the acquired response. Antigen-presenting cells have receptors that recognize pathogen-associated molecular patterns (PAMPs) expressed by the parasite. Among these, the Toll-like receptor (TLR) is one of the most studied. Stimulation of these receptors culminates with the activation of signaling pathways in infected cells, which results in induction of antimicrobial genes and inflammatory cytokines (IL-12, TNF) while increasing the ability of cells to present antigen. Thus, pathogen recognition by TLR receptors helps conducting adaptive immune response against the presented antigen [77].

Expression of TLR genes in dogs infected with *L. infantum* varies according to the different tissues and stages of infection. As the disease progresses, there is a significant decrease in transcription for TLR3, TLR4, TLR9, IL-17, IL-22, and FoxP3 in lymph nodes. In spleen samples, decreased transcription for TLR4 and IL-22 has been observed when infected groups were compared with controls. In the skin, upregulation was observed only for TLR9 and FoxP3 in early stages of infection, as well as downregulation for TLR3 and TLR9 in later stages. Decrease in transcription of TLRs, Th17, and FoxP3 cytokines is suggestive of silent establishment of infection [78]. In peripheral blood samples from infected dogs, the highest expression of TLR2 and its receptor CD11b (CR3) by monocytes correlates with reduced parasitic load and higher resistance to leishmaniasis [79].

Studies have shown that both inlet and survival of *Leishmania* spp. within macrophages can occur from prior infection of neutrophils, which are recruited as a normal response to insect

bites. The agent reaches the interior of macrophages when they phagocytose apoptotic bodies of previously infected neutrophils, where it can survive and multiply. This parasite escape mechanism is called “Trojan Horse” [80].

The main effector mechanism involved in protective immune response against *Leishmania* spp. is the activation of macrophages by IFN- γ and tumor necrosis factor alpha (TNF- α) stimulation, with consequent stimulation of nitric oxide synthesis, which is required for effective destruction of the pathogen and for controlling the spread of infection in dogs [81–83].

3.2. Acquired response

3.2.1. Lymphocytes

The major subpopulations of lymphocytes are CD4+ T cells (Th1, producing IFN- γ and TNF- α ; Th2, secreting IL-4, IL-5, and IL-13; and Th17, producing IL-17 and IL-22) and CD8+ T cells. Antigen-presenting cells submit *Leishmania* spp. antigens to CD4+ T cells via MHC class II, and because the agent is an intracellular parasite, there may be presentation via MHC class I with activation of CD8+ T cells as well [69].

The role of CD4+ T cells in the response to visceral leishmaniasis (VL) has not been fully elucidated. Research carried out so far points to a mixed response (Th1/Th2) during infection [84, 85]. It is reported, however, that control of infection depends on Th1 cells that activate macrophages, promoting elimination of intracellular parasites [86], whereas Th2 cells direct the immune system toward humoral response and negatively regulate cellular immunity, promoting Th1 cell anergy [87].

CD8+ cells constitute a significant population in cellular immunity against canine visceral leishmaniasis (CVL), outnumbering CD4+ cells in the dermis [87]. They play an important role in resistance to infection. Guerra et al. [88] associated phenotypic changes with tissue parasitism in the spleen and skin of infected dogs. They noticed that the high frequency of CD8+ circulating lymphocytes is directly related to low splenic parasitism and that there is a negative correlation between CD8+ T cells with skin parasite density, indicating that this cell type relates to resistance against LVC [88].

The regulatory role of FOXP3+ CD4+ T cells in canine VL has not been fully elucidated; however, reduction of Treg cell percentage in peripheral blood of infected dogs has been observed [89]. Silva et al. [90] reported increased production of IL-10 by splenic Treg cells of dogs with LV, along with decrease in the total number of T cells when compared to healthy dogs. The findings suggest that Treg cells are a major source of IL-10 in the spleen and participate in the modulation of immune response, while a small percentage of these cells in infected dogs may be related to persistent immune activation [90].

T-cell exhaustion (CD4+ and CD8+ cells) in peripheral blood of dogs with LV, followed by reduction of the expression of cytokines (such as IFN- γ), was recently demonstrated. This phenomenon, called cell exhaustion, is mainly mediated by high expression of programmed death protein (“programmed cell death 1,” PD-1) and may be related to the strong immuno-

suppression observed in advanced stages of the disease, corresponding to increase in symptomatology of VL [86].

The role of B cells in CVL is unclear. However, increases in CD21+ B cell, CD4+ T cell, and CD8+ T cell levels are frequently reported, as for the clinical asymptomatic form. Lower frequency of B cells and monocytes in the bloodstream is an important marker of severe disease, while increased levels of CD8 + T cells appear to be the most important phenotypic feature for asymptomatic clinical presentation [74]. Among symptomatic animals, decrease in CD21+ B-cell count associates with decreased CD4+ T cells, which does not occur with asymptomatic or disease-free control animals, suggesting that the decay of immunity in leishmaniasis may be related to decrease in the CD4+ T-cell population [91].

Although the relationship between a pattern of anti-*Leishmania* humoral response and resistance or susceptibility to LV is not well defined [92], immunoglobulin profile may appear as a biomarker for monitoring clinical prognosis and tissue parasitic density, as it is associated with the progression of clinical signs and increase of parasites in lymphoid organs [73]. Reis et al. reported increase in IgG1 levels associated with the asymptomatic clinical presentation and poor tissue parasitic load, while the symptomatic clinical form would be characterized by high parasitic load and high levels of anti-*Leishmania* IgG, IgG2, IgM, IgA, and IgE [73, 74]. Teixeira-Neto et al. reported similar results, with symptomatic dogs demonstrating high levels of anti-*Leishmania* IgG2 antibodies, whereas the asymptomatic showed higher IgG1 titles, when compared to IgG2 [93]. Production of IFN- γ is associated with the production of IgG1 [94], which may indicate a Th1 response profile.

3.2.2. Cytokines and chemokines

Cytokine patterns for CVL have not been well established. Studies are inconclusive, so the pattern of immune response associated with resistance or susceptibility in infected animals is yet to be established.

One of the first studies on cytokine profiling in CVL was performed by Pinelli et al. [71], who observed high levels of IL-2 and tumor necrosis factor alpha (TNF- α) in asymptomatic dogs, compared with symptomatic ones, which suggests a role of these cytokines in resistance to *L. infantum* in dogs naturally or experimentally infected. Since then, much research has been done in order to elucidate the cytokine profiles found in various tissue compartments of infected dogs. They revealed contrasting cytokine profiles among different tissues, indicating that the immune response in LVC occurs in an organ-specific manner [71].

Profile of cytokines in peripheral blood mononuclear cells (PBMC) culture from asymptomatic dogs experimentally infected with *L. infantum* shows a predominantly Th1 response, mediated by expression of IL-2, IFN- γ , and IL-18 and very low IL-4 expression [95]. De Lima [96] dosed IL-6 and TNF- α in serum of symptomatic dogs naturally infected with *L. infantum* and uninfected control dogs. TNF- α was found in similar levels in dogs of both groups, yet IL-6 showed statistically higher levels in dogs with active VL than healthy dogs, thus demonstrating to be a good indicator for the disease [96].

After evaluating expression of cytokines in spleen cells from dogs naturally infected with *L. infantum*, Lage et al. suggested that CVL is characterized by a mixed response: with production of cytokines types I and II; involvement of IFN- γ and IL-10 and a positive correlation between IL-10 levels and progression of parasitic load or clinical manifestations of the disease; and correlation between IFN- γ and increased parasitic intensity of the spleen [84]. In whole blood, the increase of IL-10 has been associated with detection of parasite DNA [97]. Do Nascimento et al., in accordance, state that in CVL there is increase in expression of pro-inflammatory cytokines IFN- γ and TNF- α in dogs with low splenic parasitism, while dogs with higher parasitic load show an increase in IL-10 [98].

Souza [99] states that asymptomatic dogs have low dermal parasitism and exhibit a mixed pattern of immune response, with simultaneous increase of type I (IFN- γ and TNF- α) and type II (IL-5 and IL-13) cytokines, but predominance of type I response. According to the author, increased and simultaneous expression of IFN- γ and TNF- α in the skin of infected dogs enables the speculation that these mediators are closely involved with protection mechanisms during CVL, since these cytokines increased in the skin of animals with the asymptomatic clinical form. Increased expression of IL-5 and IL-13 in the skin of healthy dogs and negative correlation of the latter with clinical disease progression were also observed. Furthermore, high simultaneous expression of IFN- γ and IL-13 was found in asymptomatic dogs, indicating the role of IL-13 in establishing milder clinical forms [99].

Regarding cytokine profile in the bone marrow, Quinnell et al. [94] reported that expression of mRNA for IL-10, IL-4, and IL-18 was not elevated in infected dogs. However, some infected dogs had detectable expression of mRNA for IL-4 significantly correlated with more severe clinical signs. Moreover, expression of mRNA for IL-13 was not detected either in control or in infected dogs, and unlike in human infection, immunosuppressive activity of IL-10 was not observed in CVL [94].

Dogs infected with *L. infantum* exhibit significant decrease in expression of mRNAs for IL-10, IL-17, TNF- α , IFN- γ , and iNOS in liver tissue. Deficiency in IL-17 mRNA expression was evident in the symptomatic dogs compared to the asymptomatic. Reduction in cytokine expression results in decreased iNOS expression and therefore higher parasite load. The increase in IL-17 expression in the liver of asymptomatic dogs and its correlation with elevated expression of iNOS indicates a protective role of that cytokine in canine infection by *L. infantum* [67]. However, Michelin et al. [100] reported increased TNF- α , IL-4, and IL-10 levels in the liver of infected dogs compared to healthy dogs. In addition, the association between TNF- α levels and an increase in parasitic load in the spleen suggests its importance in the evolution of the infection process [100].

Another subject lacking clarification is the participation of chemokines and their receptors in resistance or susceptibility to LVC. Knowledge surrounding the role of these modulators in response to *L. infantum* infection is critical, considering that the interaction between cytokines and chemokines may regulate the immune response against the parasite, activating and recruiting immune cells to areas of infection.

Menezes-Souza et al. [101] analyzed the expression of CCL2, CCL4, CCL5, CCL13, CCL17, CCL21, CCL24, and CXCL8 chemokines in the skin of 35 dogs naturally infected by *L. infantum*, comparing cutaneous parasitism and clinical manifestations of the disease. Increase of the parasitic load correlated with increased expression of CCL2, CCL4, CCL5, CCL21, and CXCL8. On the other hand, CCL24 expression negatively correlated with parasitism [101].

After connecting clinical findings in naturally infected dogs with liver and spleen parasitism and expression levels for cytokines, chemokines, and their receptors, Albuquerque [67] showed that symptomatic dogs exhibit low expression of these modulators, alongside lower inflammatory response, and higher parasite load—primarily in the liver—than asymptomatic animals. CXCL10 was the only chemokine found at a much higher concentration in both the liver and the spleen of symptomatic animals. It also positively correlated with clinical score. The author indicates that expression profiles of hepatic and splenic chemokines and their receptors are essential for induction of correct cell inflammatory profile, as it has potential to contain the infection and the disease. Impaired cell migration facilitates replication of the parasite and development of CVL symptoms [67].

Understanding of the immune response in canine visceral leishmaniasis may reveal the factors involved with the onset and severity of clinical signs and the damage to host tissues. Additionally, it takes place as an indispensable tool for development of an effective vaccine.

4. Clinical signs and symptoms

Canine visceral leishmaniasis presents a clinical picture ranging from asymptomatic to classical symptomatic cases (**Figure 4**). Infected animals without clinical signs comprise an



Figure 4. Classical symptomatic case with emaciation, thickened skin, cutaneous lesions, exfoliative dermatitis, fur loss, and cutaneous ulcers.

alarming 40–80% of all cases, for asymptomatic dogs are a major source of infection for sand flies, and owners naturally resist to elimination of their animals [102].

At first, kala-azar signals can be rather discrete and easily confused with other diseases. Animals may have discrete lesions on the edge of the ears and slight changes in blood profile (mild anemia and/or thrombocytopenia).

Clinical leishmaniasis may appear quickly after infection or within two years. Classic canine kala-azar is characterized by thickened skin, cutaneous lesions, intermittent fever, appearance shift and fur loss, periorbital alopecia, hepatosplenomegaly, akinesia, diarrhea, onychogryphosis (nail growth; **Figure 5**), and nosebleeding. Partial paralysis of hindquarters is often seen in the final stage of the disease.




Figure 5. Onychogryphosis.

The most common skin lesions in dogs with kala-azar are exfoliative dermatitis (generalized, regional, or localized); ulcerative dermatitis, onychogryphosis, and papular dermatitis.

Cutaneous ulcers are usually located on the ear margins and have been attributed to local trauma and/or vasculitis, pressure points (**Figure 6**), limbs, and mucocutaneous junctions. Focal or multifocal nodular forms have a high amastigote load and may indicate either inefficient or strong cellular immunity by the host [101, 103–105].

Ocular disease occurs in CVL, with anterior uveitis being the most common ocular manifestation, characterized by conjunctivitis, blepharitis, periorbital alopecia, exophthalmia, keratitis, keratoconjunctivitis sicca, anterior uveitis, glaucoma, and retinal detachment [106].

The nosebleeding (epistaxis) occurs due to thrombocytopenia and is often confused with ehrlichiosis, a bacterial disease transmitted by ticks, which in many cases might associate with leishmaniasis. In endemic areas, it is advisable that any diagnosis of ehrlichia or anaplasma in dogs must be accompanied by differential diagnosis of kala-azar.

In general, dogs in endemic areas are poly-infected and malnourished, particularly stray dogs or those who frequently wander on the streets, leading to a plurality of overlapping clinical pictures. Among other conditions, furfuraceous flaking due to scabies, weight loss as

consequence of other infections or lymphomas, and autoimmune diseases, such as systemic lupus erythematosus, often confuse diagnosis since clinical signs are usually not pathognomonic. Therefore, differential diagnosis must be a concern for the small animal clinician [107, 108].

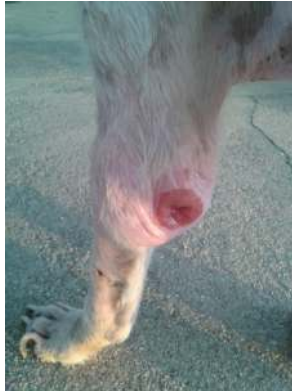

Figure 6. Cutaneous ulcer located on a pressure point.

5. Treatment

Treating seropositive dogs for canine visceral leishmaniasis (CVL) is a controversial practice in Brazil and, above all, not recommended by the World Health Organization, mainly because it does not lessen the importance of the dog as a reservoir, and utilizes drugs used in human treatment of visceral leishmaniasis (VL) [109]. Nevertheless, European countries legally established treatment since the twentieth century [110].

Frequent usage of these drugs in veterinary clinics may select resistant parasites due to variation in sensitivity of leishmania species, in addition to providing low parasiticide effect, thus interfering negatively in human treatment [111]. The lack of success for parasitological cure occurs mainly because it is an intracellular parasite and is located in less vascularized tissues where it can be difficult to obtain therapeutic doses, such as the vitreous body [112].

Many studies have been conducted in order to find an effective treatment for CVL, but drugs currently available are still inefficient, only allowing temporary remission of clinical signs. Besides, some have a high cost and produce toxic effects. Pentavalent antimonies (glucamine antimoniate—Glucontime[®] or sodium stibogluconate—Pentostam[®]) are widely used in CVL therapy protocols because they usually produce faster clinical remission but are often combined with allopurinol, since they do not prevent relapses [34]. A variety of drugs, such as amphotericin B, pentamidine isethionate, ketoconazole, fluconazole, miconazole, itraconazole, has been used either isolated or in combination and produced different results [111].

5.1. Chemotherapy

Due to the possibility of parasitic resistance to first-choice drugs, chemotherapeutic treatment options are limited. In addition, due to the high cost and long-term use, chemotherapy becomes an undesirable option for owners.

In veterinary medicine, the first choice as chemotherapy for treatment of CVL is allopurinol, a leishmanostatic drug that acts by inhibiting leishmania growth through DNA modification. It has low cost, but parasite resistance to it remains unknown. Allopurinol is however the only drug recommended by the World Health Organization, especially since it is little used for treatment of human leishmaniasis [113].

Antimonials are leishmanicidal drugs that hinder promastigote metabolism by inhibiting glycolytic activity. These are drugs of choice for human treatment of VL but are chemically similar to those that have been used in therapeutic protocols in dogs. Their toxicity and efficacy are related to the antimony content [113].

When assessing the therapeutic efficacy of Glucantime alone or associated with an antigenic extract of *L. braziliensis* in experimentally infected asymptomatic dogs, reduction in parasite burden and antibody levels decreased, but actual cure was not achieved. Yet, upon using meglumine antimoniate and allopurinol—alone and in combination—in dogs naturally infected by *L. infantum*, symptomatic animals showed remission of clinical signs about 60 days after the treatment, accompanied by restoring of normal urinary and hematologic profiles. Despite clinical improvement of treated animals, however, the combination was not able to eliminate the parasite in all dogs. Thus, this protocol is not recommended, since treated dogs would go on as a source of infection for humans and other dogs, similar to results obtained using antimoniate, which promoted hematologic normalization and bone marrow recovery, but not parasitological cure, and to findings from another study wherein dogs showed increased parasitic load in lymph nodes [114–117].

In accordance with Ikeda-Garcia et al. [116], Manna et al. [118] monitored leishmania DNA load in infected dogs through real-time PCR, using a similar treatment protocol. Therapy resulted in clinical improvement accompanied by reduction in parasite burden, but even after a long period of treatment with allopurinol alone, parasites remained in tissues [116, 118].

Miltefosine is another drug used in human treatment that has been evaluated for canine treatment in recent years. It is a phospholipid antibiotic of broad spectrum with leishmanicide effect that improves the activation of both macrophages and T cells [119]. After evaluating efficacy of three treatment protocols for dogs naturally infected with *L. infantum*, significant clinical improvement was observed and later progressed to full recovery and humoral stimulation, but did not assure cure, on the contrary, progressively increased parasite load. Hence, miltefosine alone is not recommended for treatment. The study also investigated the profile of major cytokines involved in CVL healing process, and findings showed an increase of IFN- γ within 90 days after treatment, when the parasite load in bone marrow aspirates also decreased. There was a decrease of IL-4, indicating possible resolution of the infection and efficacy of the treatment, since this cytokine is a good marker for the occurrence of active disease [112, 120].

Some studies seek to associate chemotherapeutic treatment to immunomodulatory drugs, which plays a role in therapeutic protocols by controlling clinical signs and in prevention protocols by enhancing the immune cell-mediated response through activation of macrophages via helper T cells, in order to destroy phagocytized microorganisms. Domperidone is a receptor antagonist of dopamine D2 that has been used as well. When orally given to naturally infected dogs, results showed a reduction of clinical signs and titers of anti-leishmania antibodies [121]. In Spain, Sabaté et al. [122] used a treatment protocol with domperidone in seronegative dogs in an area with high prevalence of *L. infantum* and later exposed the animals to the vector. After 21 days of treatment, the treated group had lower antibody titer, confirming that implementation of treatment with this drug reduces the risk of developing CVL [122]. Nevertheless, further clinical trials are needed to determine the optimal dose, as well as posttreatment investigations to check for parasitological cure, since the drug is a good choice for infected animals with kidney failure due to its route of administration, and it is a low-cost option [121].

Amphotericin B is a broad-spectrum macrolide antibiotic produced by actinomycete *Streptomyces nodosus* [123], available for usage in VL treatment. It has a powerful leishmanicide effect and works by binding to esters on the parasite's plasma membrane [111]. According to Solano-Gallego et al., this drug has disadvantages concerning its route of administration (IV) and its nephrotoxic potential; however, its use results in less failures and recurrences [34]. Additionally, it is frequently used in the treatment of both human and canine VL for being inexpensive.

Athanasίου et al. [124] investigated the effectiveness of aminosidine sulfate, a leishmanicide antibiotic of the aminoglycoside class, in the treatment of dogs naturally infected. They observed reduction in clinical signs and parasite density, in antibody titers through indirect immunofluorescence, and in prevalence of positive dogs using PCR 3 months after the end of the experiment. These findings can be explained by direct action of the drug as well as activation of cellular immunity. However, more studies are required to prove its therapeutic efficacy for CVL, especially considering its affordable price to owners and market availability [124].

Despite the research on efficacy of different classes of medications for CVL treatment, no great progress has been done regarding toxicity or parasitological cure, highlighting the necessity for evaluation of new formulations and medicaments to be used exclusively for treatment of CVL.

5.2. Immunochemotherapy

Immunotherapy can be an effective addition to chemotherapy, as it induces effector immune response faster than the isolated use of chemotherapeutic drugs [125]. In a trial, the combination of N-methyl meglumine antimoniate (Glucantime®) and lyophilized recombinant vaccine Leish-110f®, together with adjuvant monophosphoryl lipid A plus (MPL-SE®) to treat symptomatic animals naturally infected with *L. infantum*, was effective in reducing parasitic load. This combination enables reduction of chemotherapy doses, consequently lowering the risks of toxicity and death. However, the use of multiple recombinant antigens could provide better results [126].

Borja-Cabrera et al. [127] evaluated the efficacy of immunotherapeutic vaccine Leishmune® administered alone, both in commercial formulation enriched with saponin and in laboratory formulation, compared to its use in combination with amphotericin B and allopurinol, in dogs naturally infected with *L. infantum*, but found no significant differences between the vaccine formulations tested. As for the type of treatment, the group submitted to immunochemotherapy with saponin-enriched Leishmune® vaccine abolished, not only the symptoms but also the latent infection condition, curing the dogs [127].

Joshi et al. [128] used Balb/c mice in order to verify in vivo therapeutic potential of the first generation of vaccines with dead *L. donovani* antigen (KDL) combined with adjuvant (MPL-A) and leishmanicidal chemotherapy such as cisplatin and sodium stibogluconate (SSG) and then compared those to isolated chemotherapy and immunotherapy. In animals treated with vaccine associated to SSG, there was a 98.50% reduction in serum parasitic levels, but the study also noted that the use of any of the chemotherapeutic associated with vaccination resulted in direct parasite elimination by drug activity and activation of the immune cell-mediated response. They concluded that immunochemotherapy protocols may be effective, but further studies are needed in different animal models in order to better understand the immune response [128].

5.3. Immunotherapy

Immunotherapy is often considered for CVL prevention and control as a preferable alternative to euthanasia, due to the absence of a low-toxicity chemotherapy treatment and increasing resistance. According to Grandoni [129], vaccines are regarded as the best tool for eradication of the disease, particularly because it reduces the incidence of new cases, considering that the immune system fails to efficiently control the infection as it mediates a weak protective cell response. This relates to a dichotomy between the trigger of a Th1 response related to resistance and a Th2 response associated with susceptibility to infection, increased parasitic load, and strong but ineffective humoral immune response [129].

According to Joshi et al., an effective vaccine must induce a strong and long-lasting Th1 response as to prevent the initial establishment of infection: by definition, a prophylactic vaccine [128]. However, when it comes to a disease caused by an obligate intracellular protozoan, the aim is to at least control progression to severe disease and prevent transmission from host to vector, hindering maintenance of the epidemiological cycle.

So far, vaccines formulated for CVL include dead parasites, protein components or parasite subunits, purified cell fractions, vector salivary recombinant proteins, and viral particles that encode parasite's virulence factors and plasmid DNA [130]. Leishmune® (Zoetis Animal Health) was the first vaccine approved for commercial use in Brazil, in 2003. However, in 2014 the Ministry of Agriculture, Livestock, and Supply (MALS) halted manufacturing and marketing licenses due to problems in phase III. It consists of a glycoprotein antigen that binds recombinant fucose mannose which was able to stimulate good cellular immune response, decreasing IL-4, and activate CD4+ T cells, producing TNF- α and IFN- γ , important cytokines in resistance [131, 132]. Accordingly, a study done by Borja-Cabrera et al. found that the vaccine

induced a long-lasting protective effect of humoral and cellular immunity, along with disappearance of clinical signs and parasitemia [133].

Leish-Tec® (Hertape), a vaccine comprising recombinant protein A2 as antigen in adjuvant saponin QuilA, continues to be marketed in Brazil since 2008, when it was recorded by the MALS. It has been demonstrated to offer partial protection against *L. infantum* in Beagle dogs, producing good humoral and cellular immune responses, high levels of anti-protein A2 IgG and IgG2, and IFN- γ [134, 135].

Despite increasing progress in production of vaccines against CVL in Brazil and worldwide, there is much to be improved regarding the induction of durable and efficient cellular and humoral immune response. Moreover, new affordable vaccines ought to be produced for the population, since those available in the market so far are expensive and not viable for use in public health.

6. Diagnosis

The clinical diagnosis of CVL is challenging, as signs are usually not specific for the disease; laboratory assays are therefore of paramount importance. Moreover, as the dog is considered to be the major reservoir in Brazil, serological assays constitute the basis to identify infected dogs and to direct public health actions aiming the disease control.

The indirect immunofluorescence antibody test (IFAT) was established as the standard serodiagnosis in public health programs more than 40 years ago. It was later substituted by an ELISA based on crude leishmania antigens [111] and more recently by a recombinant ELISA and an immunochromatographic rapid test for detecting K26/K39-reactive antibodies in canine sera [136, 137]. According to the recommendation from the Brazilian Ministry of Health, sera collected from dogs in seroepidemiologic surveys as part of the Leishmaniasis Control Program are first screened using the fast immunochromatographic assay (known as dual-path platform (DPP)), and the positive samples are retested in the recombinant ELISA. The approach undoubtedly speeds up the screening [138], but due to the DPP low sensitivity in cases of sera from asymptomatic dogs [137, 139, 140], a sizable set of infected dogs possibly remains in the endemic areas, jeopardizing the effectiveness of control actions.

Private laboratories used to rely in a single result obtained by the use of a commercial recombinant ELISA kit (ELISA S7) registered at the Brazilian Ministry of Agriculture, Livestock, and Supply for the diagnosis of CVL (www.biogene.ind.br). More recently, some fast immunochromatographic assays started to be used, such as the Alere assay [141], but high costs preclude their adoption in the routine diagnosis. A recombinant K39-based ELISA developed for research use only (<http://www.inbios.com/kalazar-detect-elisa-system-for-visceral-leishmaniasis-intl/>) has also seen some use in routine commercial CVL diagnosis.

The official recombinant ELISA assay and the ELISA S7 have similar sensitivity and specificity indexes and perform equally well in the identification of seropositive, supposedly infected dogs. They also do not display significant rates of positive reactions in cases of

vaccinated dogs. Other serological assays, e.g., the direct agglutination (DAT), are not easily available in Brazil and were never adopted in private or public labs. Although new antigens have been described in the last years (e.g., [142]), their commercial use in serodiagnosis is still uncertain. Although available as commercial kits (http://www.genesig.com/products/9332?gclid=CNXfgtXc_c4CFcoHkQodMm4Ctw), PCR assays are seldom used and have limited application for the routine diagnosis.

As the existing recombinant ELISA assays have high sensitivity and specificity even in the serodiagnosis of CVL in asymptomatic dogs, one could argue against the need of new laboratory tests. However, claims of cross reactions with babesiosis and other common canine infectious diseases [138] continue to stir dissatisfaction.

In conclusion, no diagnostic breakthroughs have been described and no innovative technology was introduced in the market in the last years, and there are no evidences that this scenario will be changed in the near future.

7. Epidemiological surveillance, preventive, and control measures

Visceral leishmaniasis control activities focus on reducing morbidity and mortality through early diagnosis and treatment of human cases, monitoring and euthanasia of seropositive dogs and sand fly population control via entomological surveillance such as chemical control. Additionally, they include education and health activities that involve joint actions aiming to improve population's quality of life, such as provision of basic sanitation and proper trash disposal [143].

In Brazil, the Visceral Leishmaniasis Control Program (VLCP) recommends surveillance, preventive and control measures of human and canine visceral leishmaniasis [11]. Epidemiological surveillance aims to reduce mortality and morbidity rates through early diagnosis and treatment of human cases and to reduce the risk of transmission by controlling reservoirs and vector populations. Surveillance comprises entomological surveillance of human and canine cases. What is set at national level for epidemiological surveillance of VL, emphasizing canine population, is described in the following paragraphs.

Through epidemiological analysis of VL in the state or municipality, transmission areas are classified in areas with VL cases or silent areas (without cases). Areas with cases are those with record of a first confirmed case, those with sporadic, moderate, and intense transmission and those undergoing outbreaks. Silent areas or areas without cases are classified as vulnerable (receptive and unreceptive) or not vulnerable.

Entomological surveillance aims to gather quantitative and qualitative information about *L. longipalpis* and/or *L. cruzi* vectors. This is a task for the state and/or municipal health departments, which must work integratedly in order to optimize resources and effectiveness of sand fly control activities.

In regard to dogs, surveillance focuses on suspect canine cases (symptomatic animals in endemic or outbreak areas) and on those confirmed by (a) laboratory criteria, symptomatic

and positive in serological and/or parasitological test; (b) clinical and epidemiological criteria, symptomatic from endemic or outbreak areas without diagnostic confirmation; and (c) infected dogs, asymptomatic and positive in serological and/or parasitological test. When a canine case is identified, delimitation of the area to be investigated is among the surveillance actions to be taken. In those areas, active search for symptomatic dogs must be carried out for parasitological examination, and if the agent is found, serological survey of all animals in the area must be done in order to evaluate local prevalence and to implement appropriate measurements.

Sample and census serosurveys must be performed as monitoring activity. The sample serological survey must be carried out in silent and receptive municipalities with *L. Longipalpis* and in those with moderate and intense transmission. The census serological survey must be performed in urban areas of silent and receptive municipalities with canine population smaller than 500 animals, in urban areas of moderate or intense transmission and rural areas in any transmission situation. The aim of a census survey is to control disease by identification of infected dogs in order to perform euthanasia and assess prevalence. It must be performed annually for at least three consecutive years, even without notification of new confirmed human cases.

Preventive measures regarding canine population are (a) control of errant canine population, (b) donation of dogs after performing negative serological tests, (c) vaccination against CVL, (d) the use of fine mesh screen at individual or collective kennels, and (e) the use of collars impregnated with deltamethrin 4%.

Canine reservoir control measures consist in euthanasia of seropositive dogs and/or positive in parasitological tests, besides disposal of the bodies in accordance with the provisions of RDC Resolution No. 33, of February 25, 2003, from the National Agency for Health Surveillance.

In Brazil, since 2000, as part of the decentralization process undergone by the National Health Foundation (FUNASA), the states' federal district and municipalities became responsible for operating assistance, epidemiology, and disease control activities. They now receive almost all movable property, allocated in all federal units and more than 26,000 servers, and resources for maintenance of the transferred responsibilities [144]. However, despite the decentralization and recommendations by VLCP, the action taken toward canine reservoirs have been mainly restricted to areas of human case occurrences, that is, after a human case confirmation, canine serological survey follows in the surrounding area, and later, euthanasia of animals found seropositive in screening (DPP®) and confirmatory (EIE-Biomanguinhos) tests. Individual preventive measures such as vaccination, coverage of kennel doors and windows with mesh screen, and collars impregnated with deltamethrin 4% are restricted to animals whose owners have relatively high economic standard.

Several factors hinder the fulfillment of activities imposed by VLCP. Some of them are the lack of federal funding; insufficient staff to perform activities related to VL and other endemic diseases; prioritization for control of other endemic diseases such as dengue, Zika, and chikungunya; expansion of transmission areas; and interference of veterinarians, animal owners; and nongovernmental organizations (NGOs) regarding euthanasia of reservoirs, as

such procedure generates controversy regarding its control efficacy, although recommended in Brazil [145].

Acknowledgements

Funding provided by The National Science Center (Poland) grant No. 2014/13/B/NZ4/03832.

Author details

Marcia Almeida de Melo^{1,2*}, Raizza Barros Sousa Silva², Laysa Freire Franco e Silva², Beatriz Maria de Almeida Braz², Jaqueline Maria dos Santos³, Saul José Semião Santos⁴ and Paulo Paes de Andrade⁵

*Address all correspondence to: marcia.melo@pq.cnpq.br

1 Federal University of Campina Grande (UFCG), Patos, Brazil

2 Postgraduate Program Veterinary Medicine/UFCG, Patos, Brazil

3 Postgraduate Program in Animal and Tropical Science/Federal Rural University of Pernambuco (UFRPE), Recife, Brazil

4 Tiradentes University, Aracaju, Brazil

5 Federal University of Pernambuco (UFPE), Recife, Brazil

References

- [1] PAHO/WHO. Key facts on Neglected Infectious Diseases. Leishmaniasis [Internet]. 2014. Available from: file:///D:/Pessoal/Downloads/2014-cha-leishmaniasis-factsheet.pdf [Accessed: 2016-07-17]
- [2] WHO. Leishmaniasis [Internet]. 2016. Available from: <http://www.who.int/mediacentre/factsheets/fs375/en/> [Accessed: 2016-07-17]
- [3] WHO. Status of endemicity of visceral leishmaniasis, worldwide, 2013 [Internet]. 2015. Available from: file:///D:/Pessoal/Downloads/Leishmaniasis_Burden_distribution_VL_CL_2013.pdf [Accessed: 2016-07-17]
- [4] Pita-Pereira D, Cardoso MAB, Alves CR, Brazil RP, Britto C. Detection of natural infection in *Lutzomyia cruzi* and *Lutzomyia forattinii* (Diptera: Psychodidae: Phlebotominae) by *Leishmania infantum chagasi* in an endemic area of visceral leishmaniasis in

- Brazil using a PCR multiplex assay. *Acta Tropica*. 2008; 107:66–69. DOI: 10.1016/j.actatropica.2008.04.015
- [5] Carreira JCA, Magalhães MAFM, Silva AVM. The geospatial approach on eco-epidemiological studies of leishmaniasis. In: Claborn DM. (Ed.) *Leishmaniasis—trends in epidemiology, diagnosis and treatment*. InTech; 2014. p. 125–145. DOI: 10.5772/57067
- [6] Akhoundi M, Kuhls K, Cannet A, Votýpka J, Marty P, Delaunay P, Sereno D. A historical overview of the classification, evolution, and dispersion of leishmania parasites and sandflies. *PLoS Negl Trop Dis*. 2016; 10(3):1–40. DOI: 10.1371/journal.pntd.0004349
- [7] Harhay MO, Olliaro PL, Costa DL, Costa CHN. Urban parasitology: visceral leishmaniasis in Brazil. *Trends Parasitol*. 2011; 27(9):403–409. DOI:10.1016/j.pt.2011.04.001
- [8] Ready PD. Epidemiology of visceral leishmaniasis. *Clinical Epidemiology*. 2014; 6:147–154. DOI: 10.2147/CLEP.S44267
- [9] Schlein Y, Warburg A. Phytophagy and the feeding cycle of *Phlebotomus papatasi* (Diptera: Psychodidae) under experimental conditions. *J Med Entomol*. 1986; 23:11–15
- [10] Ready PD. Biology of phlebotomine sand flies as vectors of disease agents. *Annu Rev Entomol*. 2013; 58:227–250. DOI: 10.1146/annurev-ento-120811-153557
- [11] Brasil. Ministério da Saúde. Manual de vigilância e controle da leishmaniose visceral. 1th ed. Brasília (DF): Ministério da Saúde; 2014. 120 p.
- [12] Troncarelli MZ, Carneiro DMVF, Langoni H. Visceral leishmaniasis: an old disease with continuous impact on public health. In: Lorenzo-Morales J. (Ed.) *Zoonosis*. InTech; 2012. p. 263–282. DOI: 10.5772/38680
- [13] Dias FOP, Lorosa ES, Rebêlo JMM. Blood feeding source and peridomiciliation of *Lutzomyia longipalpis* (Lutz ... Neiva, 1912) (Psychodidae, Phlebotominae). *Cad Saúde Pública*. 2003; 19(5):1373–1380. DOI: 10.1590/S0102-311X2003000500015.
- [14] Lainson R, Rangel E. *Lutzomyia longipalpis* and the eco-epidemiology of American visceral leishmaniasis, with particular reference to Brazil—a review. *Mem Inst Oswaldo Cruz*. 2005;100:811–827. DOI: /S0074-02762005000800001
- [15] Gontijo CMF, Melo MN. Visceral leishmaniasis in Brazil: current situation, challenges and perspectives. *Rev Bras Epidemiol*. 2004; 7(3):338–349. DOI: 10.1590/S1415-790X2004000300011
- [16] Alvar J, Cañavate C, Molina R, Moreno J, Nieto J. Canine leishmaniasis. *Adv Parasitol*. 2004; 57:1–88. DOI: 10.1016/S0065-308X(04)57001-X
- [17] Molina R, Amela C, Nieto J, San-Andrés M, González F, Castillo JA, Lucientes J, Alvar J. Infectivity of dogs naturally infected with *Leishmania infantum* to colonized *Phlebotomus perniciosus*. *Trans R Soc Trop Med Hyg*. 1994;88:491–493.

- [18] Gramiccia M. Recent advances in leishmaniosis in pet animals: Epidemiology, diagnostics and anti-vectorial prophylaxis. *Vet Parasitol.* 2011; 181:23–30. DOI: 10.1016/j.vetpar.2011.04.019
- [19] Dantas-Torres F, de Brito ME, Brandão-Filho SP. Seroepidemiological survey on canine leishmaniasis among dogs from an urban area of Brazil. *Vet Parasitol.* 2006; 140(1–2): 54–60. DOI: 10.1016/j.vetpar.2006.03.008
- [20] de Freitas E, Melo MN, da Costa-Val AP, Michalick MSM. Transmission of *Leishmania infantum* via blood transfusion in dogs: potential for infection and importance of clinical factors. *Vet Parasitol.* 2006; 137:159–167. DOI: 10.1016/j.vetpar.2005.12.011
- [21] Silva FL, Oliveira RG, Silva TM, Xavier MN, Nascimento EF, Santos RL. Venereal transmission of canine visceral leishmaniasis. *Vet Parasitol.* 2009; 160(1–2):55–59. DOI: 10.1016/j.vetpar.2008.10.079.
- [22] Boggiatto PM, Gibson-Corley KN, Metz K, Gallup JM, Hostetter JM, Mullin K, Petersen CA. Transplacental transmission of *Leishmania infantum* as a means for continued disease incidence in North America. *PLoS Negl Trop Dis.* 2011; 5(4):e1019. DOI: 10.1371/journal.pntd.0001019.
- [23] Oliveira VVG, Alves LC, Silva Junior VA. Transmission routes of visceral leishmaniasis in mammals. *Cienc Rural [online].* 2015; 45(9):1622–1628. DOI: 10.1590/0103-8478cr20141368.
- [24] Schantz PM, Steurer FJ, Duprey ZH, Kurpel KP, Barr SC, Jackson JE, Breitschwerdt EB, Levy MG, Fox JC. Autochthonous visceral leishmaniasis in dogs in North America. *J Am Vet Med Assoc.* 2005; 226:1316–1322.
- [25] Naucke TJ, Amelung S, Lorentz S. First report of transmission of canine leishmaniosis through bite wounds from a naturally infected dog in Germany. *Parasit Vectors.* 2016; 9(1):256. DOI: 10.1186/s13071-016-1551-0.
- [26] Kaszak I, Planellas M, Dworecka-Kaszak B. Canine leishmaniosis—an emerging disease. *Ann Parasitol.* 2015; 61(2):69–76.
- [27] Moreno J, Alvar J. Canine leishmaniasis: epidemiological risk and the experimental model. *Trends Parasitol.* 2002; 18(9):399–405
- [28] Franco AO, Davies CR, Mylne A, Dedet JP, Gállego M, Ballart C, Gramiccia M, Gradoni L, Molina R, Gálvez R, Morillas-Márquez F, Barón-López S, Pires CA, Afonso MO, Ready PD, Cox J. Predicting the distribution of canine leishmaniasis in western Europe based on environmental variables. *Parasitology.* 2011; 138(14):1878–1891. DOI: 10.1017/S003118201100148X
- [29] Cortes S, Vaz Y, Neves R, Maia C, Cardoso L, Campino L. Risk factors for canine leishmaniasis in an endemic Mediterranean region. *Vet Parasitol.* 2012; 189(2–4):189–196. DOI: 10.1016/j.vetpar.2012.04.028

- [30] Zivicnjak T, Martinković F, Marinculić A, Mrljak V, Kucer N, Matijatko V, Mihaljević Z, Barić-Rafaj R. A seroepidemiologic survey of canine visceral leishmaniosis among apparently healthy dogs in Croatia. *Vet Parasitol.* 2005; 131,35–43. DOI: 10.1016/j.vetpar.2005.04.036
- [31] Mazeris A, Soteriadou K, Dedet JP, Haralambous C, Tsatsaris A, Moschandreas J, Messaritakis I, Christodoulou V, Papadopoulos B, Ivovic V, Pralong F, Loucaides F, Antoniou M. Leishmaniasis and the Cyprus paradox. *Am J Trop Med Hyg.* 2010; 82(3): 441–448. DOI: 10.4269/ajtmh.2010.09-0282
- [32] Ntais P, Sifaki-Pistola D, Christodoulou V, Messaritakis I, Pralong F, Poupalos G, Antoniou M. Leishmaniasis in Greece. *Am J Trop Med Hyg.* 2013; 89(5):906–915. DOI: 10.4269/ajtmh.13-0070
- [33] Maia C, Cardoso L. Spread of *Leishmania infantum* in Europe with dog travelling. *Vet Parasitol.* 2015; 213(1–2):2–11. DOI: 10.1016/j.vetpar.2015.05.003
- [34] Solano-Gallego L, Koutinas A, Miró G, Cardoso L, Pennisi MG, Ferrer L, Bourdeau P, Oliva G, Baneth G. Directions for the diagnosis, clinical staging, treatment and prevention of canine leishmaniosis. *Vet Parasitol.* 2009; 165(1–2):1–18. DOI: 10.1016/j.vetpar.2009.05.022
- [35] Maroli M, Rossi L, Baldelli R, Capelli G, Ferroglia E, Genchi C, Gramiccia M, Mortarino M, Pietrobelli M, Gradoni L. The northward spread of leishmaniasis in Italy: evidence from retrospective and ongoing studies on the canine reservoir and phlebotomine vectors. *Trop Med Internat Health.* 2008; 13(2):256–264. DOI: 10.1111/j.1365-3156.2007.01998.x
- [36] Naucke TJ, Menn B, Massberg D, Lorentz S. Sandflies and leishmaniasis in Germany. *Parasitol Res.* 2008; 103(1):S65–S68. DOI: 10.1007/s00436-008-1052-y
- [37] Miró G, Checa R, Montoya A, Hernández L, Dado D, Gálvez R. Current situation of *Leishmania infantum* infection in shelter dogs in northern Spain. *Parasit Vectors.* 2012; 5:60. DOI: 10.1186/1756-3305-5-60
- [38] Boakye DA, Wilson M, Kweku M. A review of leishmaniasis in west Africa. *Ghana Med J.* 2005; 39(3):94–97.
- [39] Harrat Z, Belkaid M. Les leishmanioses dans l'Algérois. Données épidémiologiques. *Bull Soc Pathol Exot.* 2003; 96(3):212–214.
- [40] Rhajaoui M, Nasereddin A, Fellah H, Azmi K, Amarir F, Al-Jawabreh A, Ereqat S, Planer J, Abdeen Z. New clinicoepidemiologic profile of cutaneous leishmaniasis, Morocco. *Emerg Infect Dis.* 2007; 13(9):1358–1360. DOI: 10.3201/eid1309.070946
- [41] Mohebbali M, Hajjaran H, Hamzavi Y, Mobedi I, Arshi S, Zarei Z, Akhoundi B, Naeini KM, Avizeh R, Fakhar M. Epidemiological aspects of canine visceral leishmaniosis in the Islamic Republic of Iran. *Vet Parasitol.* 2005; 129:243–251. DOI: 10.1016/j.vetpar.2005.01.010

- [42] Mahshid M, Baharak A, Iraj S, Sina K, Javad K, Mehdi B. Seroprevalence of canine visceral leishmaniasis in southeast of Iran. *J Parasit Dis.* 2014; 38(2):218–222. DOI: 10.1007/s12639-012-0226-9
- [43] Shang L, Peng W, Jin H, Xu D, Zhong N, Wang W, Wu Y, Liu Q. The prevalence of canine *Leishmania infantum* infection in Sichuan Province, southwestern China detected by real time PCR. *Parasit Vectors* 2011; 4:173. DOI: 10.1186/1756-3305-4-173
- [44] Wang J, Ha Y, Gao C, Wang Y, Yang Y, Chen H. The prevalence of canine *Leishmania infantum* infection in western China detected by PCR and serological tests. *Parasit Vectors.* 2011; 4:69. DOI: 10.1186/1756-3305-4-69
- [45] Duprey ZH, Steurer FJ, Rooney JA, Kirchhoff LV, Jackson JE, Rowton ED, Schantz PM. Canine Visceral Leishmaniasis, United States and Canada, 2000–2003. *Emerg Infect Dis.* 2006; 12(3): 440–446. DOI: 10.3201/eid1205.050811
- [46] Gaskin AA, Schantz P, Jackson J, Birkenheuer A, Tomlinson L, Gramiccia M, Levy M, Steurer F, Kollmar E, Hegarty BC, Ahn A, Breitschwerdt EB. Visceral leishmaniasis in a New York foxhound kennel. *J Vet Intern Med.* 2002;16(1):34–44.
- [47] Schaut RG, Robles-Murguía M, Juelsgaard R, Esch KJ, Bartholomay LC, Ramalho-Ortigao M, Petersen CA. Vectorborne Transmission of *Leishmania infantum* from Hounds, United States. *Emerg Infect Dis.* 2015; 21(12):2209–2212. DOI: 10.3201/eid2112.141167
- [48] Salomón OD, Sinagra A, Nevot MC, Barberian G, Paulin P, Estevez JO, Riarte A, Estevez J. First visceral leishmaniasis focus in Argentina. *Mem Inst Oswaldo Cruz.* 2008; 103(1): 109–111. DOI: 10.1590/S0074-02762008000100018
- [49] Salomón OD, Quintana MG, Bruno MR, Quiriconi RV, Cabral V. Visceral leishmaniasis in border areas: clustered distribution of phlebotomine sand flies in Clorinda, Argentina. *Mem Inst Oswaldo Cruz.* 2009; 104(5):801–804. DOI: 10.1590/S0074-02762009000500024
- [50] Petersen CA, Barr SC. Canine leishmaniasis in North America: emerging or newly recognized? *Vet Clin North Am Small Anim Pract.* 2009; 39(6):1065–1074. DOI: 10.1016/j.cvsm.2009.06.008.
- [51] Rosete-Ortíz D, Berzunza-Cruz MS, Salaiza-Suazo NL, González C, Treviño-Garza N, Ruiz-Remigio A, Gudiño-Zayas ME, Beltrán-Silva S, Romero-Zamora JS, Ugarte-Soto A, Rivas-Sánchez B, Becker I. Canine leishmaniasis in Mexico: the detection of a new focus of canine leishmaniasis in the state of Guerrero correlates with an increase of human cases. *Bol Med Hosp Infant Mex.* 2011; 68(2):88–93.
- [52] Barboza DCPM, Leal DC, Souza BMPS, Carneiro AJB, Gomes Neto CMB, Alcântara ACD, Julião FS, Moura SAB, Peralva LMP, Ferreira F, Franke CR. Canine visceral

- leishmaniasis epidemiological survey in three sanitary districts of Salvador, Bahia State, Brazil, *Rev Bras Saúde Prod Anim.* 2009; 10(2):434–447.
- [53] Silva-Abreu AL, Lima TB, Macedo AA, Moraes-Júnior FJ, Dias EL, Batista ZS, Calabrese KS, Moraes JLP, Rebêlo JMM, Guerra RMSNC. Seroprevalence, clinical and biochemical data of dogs naturally infected by *Leishmania* and phlebotominae sandfly fauna in an endemic area in São Luis Island, Maranhão State, Brazil, *Rev Bras Parasitol Vet.* 2008; 17:197–203.
- [54] WHO. Urbanization: an increasing risk factor for leishmaniasis. *Weekly epidemiological record.* 2002; 44(77):365–370. Available from: <http://www.who.int/wer> [Accessed: 2016-07-17]
- [55] Moreno EC, Melo MN, Genaro O, Lambertucci JR, Serufo JC, Andrade AS, Antunes CM, Carneiro M. Risk factors for *Leishmania chagasi* infection in an urban area of Minas Gerais State. *Rev Soc Bras Med Trop.* 2005;38(6):456–463. DOI:S0037-86822005000600002
- [56] Cesse EAP, Carvalho EF, Andrade PP, Ramalho WM, Luna LKS. The organization of urban areas and expansion of kala-azar. *Revista Brasileira de Saúde Materno Infantil.* 2001; 1(2):167–176.
- [57] Azevedo JSC, Esmeraldino AT, Ávila VPF, Witz MI, Fischer CDB, Tartarotti AL. Autochthonous canine visceral leishmaniasis in the municipality of São Borja, Rio Grande do Sul, Brazil: a case report. *Veterinária em Foco.* 2009; 7(1):52–61.
- [58] Souza GD, Santos ES, Andrade Filho JD. The first report of the main vector of visceral leishmaniasis in America, *Lutzomyia longipalpis* (Lutz & Neiva) (Diptera: Phlebotominae), in the state of Rio Grande do Sul, Brazil, *Mem Inst Oswaldo Cruz.* 2009; 104(8):1181–1182. DOI: 10.1590/S0074-02762009000800017
- [59] Souza APL, Jesus JR, Teixeira MC. Retrospective study of visceral leishmaniasis epidemiology in Rio Grande do Sul: a literature review. *Veterinária em Foco.* 2014; 11(2): 112–118.
- [60] França-Silva JC, Costa RT, Siqueira AM, Machado-Coelho GLL, Costa CA, Mayrink W, Vieira EP, Costa JS, Genaro O, Nascimento E. Epidemiology of canine visceral leishmaniasis in the endemic área of Montes Claros Municipality, Minas Gerais state, Brazil, *Vet Parasitol.* 2003; 111:161–173. DOI: 10.1016/S0304-4017(02)00351-5
- [61] Azevedo MAA, Dias AKK, Paula HB, Perri SHV, Nunes CM. 2008. Evaluation of canine visceral leishmaniasis in Poxoréu, Mato Grosso, Brazil. *Rev Bras Parasitol Vet.* 17(3): 123–127. DOI: 10.1590/S1984-29612008000300001
- [62] Belo VS, Struchiner CJ, Werneck GL, Barbosa DS, Oliveira RB, Neto RGT, Silva ES. A systematic review and meta-analysis of the factors associated with *Leishmania infantum*

- infection in dogs in Brazil. *PLoS Negl Trop Dis*. 2013; 7(4):e2182. DOI: 10.1371/journal.pntd.0002182
- [63] Costa CHN. Characterization and speculations on the urbanization of visceral leishmaniasis in Brazil. *Cad Saúde Pública*. 2008; 24(12):2959–2963. DOI: 10.1590/S0102-311X2008001200027
- [64] Gálvez R, Miró G, Descalzo MA, Nieto J, Dado D, Martín O, Cubero E, Molina R. Emerging trends in the seroprevalence of canine leishmaniasis in the Madrid region (central Spain). *Vet Parasitol*. 2010; 169:327–334. DOI: 10.1016/j.vetpar.2009.11.025
- [65] Costa AP, Costa FB, Soares HS, Ramirez DG, Araújo AC, Ferreira JGS, Tonhosolo R, Dias RA, Gennari SM, Marcili A. Environmental Factors and Ecosystems Associated with Canine Visceral Leishmaniasis in Northeastern Brazil. *Vector Borne Zoonotic Dis*. 2015; 15(12):765–774. DOI: 10.1089/vbz.2015.1866
- [66] Silva RBS, Mendes RS, Santana VL, Souza HC, Ramos CPS, Souza AP, Andrade PP, Melo MA. Epidemiological aspects of canine visceral leishmaniasis in the semi-arid region of Paraíba and analysis of diagnostic techniques. *Pesq Vet Bras*. 2016;36(7):625–629.
- [67] Albuquerque TDR. Correlation between immune response and the clinical manifestations of Canine Visceral Leishmaniasis. Natal: UFRN; 2013.
- [68] Barbieri CL. Immunology of canine leishmaniasis. *Parasite Imunol*. 2006; 28:329–337. DOI: 10.1111/j.1365-3024.2006.00840.x
- [69] Abbas AK, Lichtman AH, Pillai S. *Imunologia celular e molecular*. 7th ed. Rio de Janeiro: Elsevier Editora Ltda; 2011.592 p. DOI: 10.1084/gen.20090209
- [70] Brittingham A, Morrison CJ, McMaster WR, McGuire BS, Chang KP, Mosser DM. Role of the *Leishmania* surface protease gp63 in complement fixation, cell adhesion, and resistance to complement-mediated lysis. *J Immunol*. 1995; 155(6):3102–3111. DOI: 10.1016/0169-4758(95)80054-9
- [71] Pinelli E, Killick-Kendrick R, Wagenaar J, Bernadina W, Real G, Ruitenbergh J. Cellular and humoral immune responses in dogs experimentally and naturally infected with *Leishmania infantum*. *Infect Immun*. 1994; 62(1):229–235.
- [72] Santos-Gomes GM, Rosa R, Leandro C, Cortes S, Romão P, Silveira H. Cytokine expression during the outcome of canine experimental infection by *Leishmania infantum*. *Vet Immunol Immunopathol*. 2002; 88(1–2):21–30. DOI: 10.1016/S0165-2427(02)00134-4
- [73] Reis AB, Teixeira-Carvalho A, Vale AM, Marques MJ, Giunchetti RC, Mayrink W, Guerra LL, Andrade RA, Corrêa-Oliveira R, Martins-Filho OA. Isotype patterns of immunoglobulins: hallmarks for clinical status and tissue parasite density in Brazilian dogs naturally infected by *Leishmania (Leishmania) chagasi*. *Vet Immunol Immunopathol*. 2006; 112(3–4):102–116. DOI: 10.1016/j.vetimm.2006.02.001

- [74] Reis AB, Martins-Filho OA, Teixeira-Carvalho A, Giunchetti RC, Carneiro CM, Mayrink W, Tafuri WL, Corrêa-Oliveira R. Systemic and compartmentalized immune response in canine visceral leishmaniasis. *Vet Immunol Immunopathol.* 2009; 128(1-3):87–95. DOI: 10.1016/j.vetimm.2008.10.307
- [75] Giunchetti RC, Martins-Filho OA, Carneiro CM, Mayrink W, Marques MJ, Tafuri WL, Corrêa-Oliveira R, Reis AB. Histopathology, parasite density and cell phenotypes of the popliteal lymph node in canine visceral leishmaniasis. *Vet Immunol Immunopathol.* 2008; 121(1-2):23–33. DOI: 10.1016/j.vetimm.2007.07.009
- [76] Giunchetti RC, Mayrink W, Carneiro CM, Corrêa-Oliveira R, Martins-Filho OA, Marques MJ, Tafuri WL, Reis AB. Histopathological and immunohistochemical investigations of the hepatic compartment associated with parasitism and serum biochemical changes in canine visceral leishmaniasis. *Res Vet Sci.* 2008; 84(2):269–277. DOI: 10.1016/j.rvsc.2007.04.020
- [77] Janeway CA, Medzhitov R. Innate immune recognition. *Annu Rev Immunol.* 2002; 20:197–216. DOI: 10.1146/annurev.immunol.20.083001.084359
- [78] Hosein S, Rodríguez-Cortés A, Blake DP, Allenspach K, Alberola J, Solano-Gallego L. Transcription of toll-like receptors 2, 3, 4 and 9, FoxP3 and Th17 cytokines in a susceptible experimental model of canine *Leishmania infantum* infection. *PLoS ONE.* 2015;10(10). DOI: 10.1371/journal.pone.0140325
- [79] Amorim IF, Silva SM, Figueiredo MM, Moura EP, Castro RS, Lima TK, Gontijo Nde F, Michalick MS, Gollob KJ, Tafuri WL. Toll receptors type-2 and CR3 expression of canine monocytes and its correlation with immunohistochemistry and xenodiagnosis in visceral leishmaniasis. *PLoS ONE.* 2011; 6(11). DOI: 10.1371/journal.pone.0027679
- [80] Laskay T, Van Zandbergen G, Solbach W. Neutrophil granulocytes as host cells and transport vehicles for intracellular pathogens: apoptosis as infection-promoting factor. *Immunobiology.* 2008; 213(3–4):183–191. DOI: 10.1016/j.imbio.2007.11.010
- [81] Liew FY, Wei XQ, Proudfoot L. Cytokines and nitric oxide as ejector molecules against parasitic infections. *Philos Trans R Soc Lond B.* 1997; 352:1311–1315. DOI: 10.1098/rstb.1997.0115
- [82] Vouldoukis I, Drapier JC, Nüssler AK, Tselentis Y, Da Silva OA, Gentilini M, Mossalayi DM, Monjour L, Dugas B. Canine visceral leishmaniasis: successful chemotherapy induces macrophage antileishmanial activity via the l-arginine nitric oxide pathway. *Antimicrob Agents Chemother.* 1996; 40(1):253–256.
- [83] Zafra R, Jaber JR, Pérez-Ecija RA, Barragán A, Martínez-Moreno A, Pérez J. High iNOS expression in macrophages in canine leishmaniasis is associated with low intracellular parasite burden. *Vet Immunol Immunopathol.* 2008; 123(3–4):353–359. DOI: 10.1016/j.vetimm.2008.02.022
- [84] Lage RS, Oliveira GC, Busek SU, Guerra LL, Giunchetti RC, Corrêa-Oliveira R, Reis AB. Analysis of the cytokine profile in spleen cells from dogs naturally infected by

- Leishmania chagasi*. Vet Immunol Immunopathol. 2007; 115(1–2):135–145. DOI: 10.1016/j.vetimm.2006.10.001
- [85] Strauss-Ayali D, Baneth G, Jaffe CL. Splenic immune responses during canine visceral leishmaniasis. Vet Res. 2007; 38(4):547–564. DOI: 10.1051/vetres:2007015
- [86] Esch KJ, Juelsingaard R, Martinez PA, Jones DE, Petersen CA. PD-1-mediated T cell exhaustion during visceral leishmaniasis impairs phagocyte function. J Immunol. 2013; 191(11):5542–5550. DOI: 10.4049/jimmunol.1301810
- [87] Papadogiannakis EI, Koutinas AF. Cutaneous immune mechanisms in canine leishmaniasis due to *Leishmania infantum*. Vet Immunol Immunopathol. 2015; 163(3–4):94–102. DOI: 10.1016/j.vetimm.2014.11.011
- [88] Guerra LL, Teixeira-Carvalho A, Giunchetti RC, Martins-Filho OA, Reis AB, Corrêa-Oliveira R. Evaluation of the influence of tissue parasite density on hematological and phenotypic cellular parameters of circulating leukocytes and splenocytes during ongoing canine visceral leishmaniasis. Parasitol Res, 2009; 104(3):611–622. DOI: 10.1007/s00436-008-1237-4
- [89] Cortese L, Annunziatella M, Palatucci AT, Rubino V, Piantedosi D, Di Loria A, Ruggiero G, Ciaramella P, Terrazzano G. Regulatory T cells, cytotoxic T lymphocytes and a TH1 cytokine profile in dogs naturally infected by *Leishmania infantum*. Res Vet Sci. 2013; 95(3):942–949. DOI: 10.1016/j.rvsc.2013.08.005
- [90] Silva KL, de Andrade MM, Melo LM, Perosso J, Vasconcelos RO, Munari DP, Lima VM. CD4+FOXP3+ cells produce IL-10 in the spleens of dogs with visceral leishmaniasis. Vet Parasitol. 2014; 202(3–4):313–318. DOI: 10.1016/j.vetpar.2014.03.010
- [91] Bourdoiseau G, Marchal T, Magnol JP. Immunohistochemical detection of *Leishmania infantum* in formalin-fixed, paraffin-embedded sections of canine skin and lymph nodes. J Vet Diagn Invest. 1997; 9(4):439–440.
- [92] Day MJ. Immunoglobulin G subclass distribution in canine leishmaniasis: a review and analysis of pitfalls in interpretation. Vet Parasitol. 2007; 147(1–2):2–8. DOI: 10.1016/j.vetpar.2007.03.037
- [93] Teixeira-Neto RG, Giunchetti RC, Carneiro CM, Vitor RW, Coura-Vital W, Quaresma PF, Ker HG, de Melo LA, Gontijo CM, Reis AB. Relationship of Leishmania-specific IgG levels and IgG avidity with parasite density and clinical signs in canine leishmaniasis. Vet Parasitol. 2010; 169(3–4):248–257. DOI: 10.1016/j.vetpar.2010.01.023
- [94] Quinnell RJ, Courtenay O, Shaw MA, Day MJ, Garcez LM, Dye C, Kaye PM. Tissue cytokine responses in canine visceral leishmaniasis. J Infect Dis. 2001; 183(9):1421–1424. DOI: 10.1086/319869

- [95] Chamizo C, Moreno J, Alvar J. Semi-quantitative analysis of cytokine expression in asymptomatic canine leishmaniasis. *Vet Immunol Immunopathol.* 2005; 103(1–2):67–75. DOI: 10.1016/j.vetimm.2004.08.010
- [96] de Lima VM, Peiro JR, Vasconcelos RO. IL-6 and TNF- α production during active canine visceral leishmaniasis. *Vet Immunol Immunopathol.* 2007; 115(1–2):189–193. DOI: 10.1016/j.vetimm.2006.10.003
- [97] Boggiatto PM, Ramer-Tait AE, Metz K, Kramer EE, Gibson-Corley K, Mullin K, Hostetter JM, Gallup JM, Jones DE, Petersen CA. Immunologic Indicators of clinical progression during canine *Leishmania infantum* infection. *Clin Vaccine Immunol.* 2010; 17(2):267–273. DOI: 10.1128/CVI.00456-09
- [98] do Nascimento PR, Martins DR, Monteiro GR, Queiroz PV, Freire-Neto FP, Queiroz JW, Morais Lima AL, Jeronimo SM. Association of pro-inflammatory cytokines and iron regulatory protein 2 (IRP2) with *Leishmania* burden in canine visceral leishmaniasis. *PLoS ONE.* 2013; 8(10):e73873. DOI: 10.1371/journal.pone.0073873
- [99] Souza DM. The role of cytokines, chemokines and transcription factors in the immunopathology of skin in dogs naturally infected with *Leishmania (Leishmania) chagasi*, people with different clinical forms and cutaneous parasite densities. Belo Horizonte: Fundação Oswaldo Cruz, 2009.
- [100] Michelin AF, Perri SH, De Lima VM. Evaluation of TNF- α , IL-4, and IL-10 and parasite density in spleen and liver of *L. (L.) chagasi* naturally infected dogs. *Ann Trop Med Parasitol.* 2011; 105(5):373–383. DOI: 10.1179/1364859411Y.0000000027.
- [101] Menezes-Souza D, Guerra-Sá R, Carneiro CM, Vitoriano-Souza J, Giunchetti RC, Teixeira-Carvalho A, Silveira-Lemos D, Oliveira GC, Corrêa-Oliveira R, Reis AB. Higher expression of CCL2, CCL4, CCL5, CCL21, and CXCL8 chemokines in the skin associated with parasite density in canine visceral leishmaniasis. *PLoS Negl Trop Dis.* 2012; 6:e1566. DOI:10.1371/journal.pntd.0001566
- [102] Madeira MF, Schubach AO, Schubach TM, Leal CA, Marzochi MCA. Identification of *Leishmania (Leishmania) chagasi* isolated from healthy skin of symptomatic and asymptomatic dogs seropositive for leishmaniasis in the municipality of Rio de Janeiro, Brazil. *Braz J Infect Dis* 2004; 8:440–444. DOI: 10.1590/S1413-86702004000600008
- [103] Cavalcanti A, Lobo R, Cupolillo E, Bustamante F, Porrozzi R. Canine cutaneous leishmaniasis is caused by neotropical *Leishmania infantum* despite of systemic disease: a case report. *Parasitol Int.* 2012; 61:738–740. DOI: 10.1016/j.parint.2012.05.002.
- [104] Moura EP, Ribeiro RR, Sampaio WM, Lima WG, Alves CF, Melo FA, Melo MN, Tafuri WL, Tafuri WL, Michalick MSM. Histopathological and parasitological analysis of skin tissues biopsies from two distinct anatomical areas of the ears of dogs naturally infected with *Leishmania (Leishmania) chagasi*. *Braz J Vet Pathol.* 2008; 1:10–15.

- [105] Levy E, Mylonakis ME, Saridomichelakis MN, Polizopoulou ZS, Psychogios V, Koutinas AF. Nasal and oral masses in a dog. *Vet Clin Pathol.* 2006; 35:115–118.
- [106] Peña MT, Naranjo C, Klauss G, Fondevila D, Leiva M, Roura X, Davidson MG, Dubielzig RR. Histopathological features of ocular leishmaniasis in the dog. *J Comp Pathol.* 2008; 138(1):32–39.
- [107] Cafarchia C, Gallo S, Danesi P, Capelli G, Paradies P, Traversa D, Gasser RB, Otranto D. Assessing the relationship between *Malassezia* and leishmaniasis in dogs with or without skin lesions. *Acta Trop.* 2008;107:25–29. DOI: 10.1016/j.actatropica.2008.04.008
- [108] Tarantino C, Rossi G, Kramer LH, Perrucci S, Cringoli G, Macchioni G. *Leishmania infantum* and *Neospora caninum* simultaneous skin infection in a young dog in Italy. *Vet Parasitol.* 2001; 102:77–83.
- [109] WHO. Control of the leishmaniasis. Geneva: WHO. (Technical Report, Series 793), 1990.
- [110] Tesh RB. Control of zoonotic visceral leishmaniasis: is it time to change strategies? *Am J Trop Med Hyg.* 1995;52:287–292.
- [111] Brasil. Ministério da Saúde. Manual de vigilância e controle da leishmaniose visceral, 1th ed. Brasília (DF): Ministério da Saúde; 2006. 120 p.
- [112] Ciaramella P, Corona M. Canine Leishmaniasis: clinical and diagnostic aspects. *Comp Cont Educ Pract Vet.* 2003; 25:358–368.
- [113] WHO. Control of Leishmaniasis. Geneva: WHO. (Technical Report Series 949), 2010.
- [114] Melo MA, França-Silva JC, Azevedo EO, Tabosa IM, Costa RT, Genaro O, Mayrink W, Costa JO. Clinical Trial on the efficacy of the N-methyl glucamine associated to immunotherapy in dogs, experimentally infected with *Leishmania (Leishmania) chagasi*. *Revue de Médecine Vétérinaire.* 2002;153(2):75–84.
- [115] Ikeda-Garcia FA, Augusta F, Lopes RS, Marques FJ, Ciarlini PC, Lima VMF, Morinishi CK, Zanette MF, Perri SHV, Marcondes M. Clinical and parasitological evaluation of dogs naturally infected by *Leishmania (Leishmania) chagasi* submitted to treatment with meglumine antimoniate. *Vet Parasitol.* 2007; 143(3–4):254–259. DOI: 10.1016/j.vetpar.2006.08.019
- [116] Ikeda-Garcia FA, Lopes RS, Marques FJ, de Lima VM, Morinishi CK, Bonello FL, Zanette MF, Perri SH, Feitosa MM. Clinical and parasitological evaluation of dogs naturally infected by *Leishmania (Leishmania) chagasi* submitted to treatment with meglumine antimoniate and allopurinol. *Braz J Vet Res Anim Sci.* 2010; 47(3):218–223. DOI: 10.526/cab.v11i2.2149
- [117] Manna L, Corso R, Galiero G, Cerrone A, Muzj P, Gravino AE. Long-term follow-up of dogs with leishmaniasis treated with meglumine antimoniate plus allopurinol versus miltefosine plus allopurinol. *Parasit Vectors.* 2015;8:289. DOI: 10.1186/s13071-015-0896-0

- [118] Manna L, Reale S, Vitale F, Picillo E, Pavone LM, Gravino AE. Real-time PCR assay in *Leishmania*-infected dogs treated with meglumine antimoniate and allopurinol. *Vet J*. 2008; 177(2):279–282. DOI: 10.1016/j.tvjl.2007.04.013
- [119] Soto J, Toledo J, Valda L, Balderrama M, Rea I, Parra R, Ardiles J, Soto P, Gomez A, Molleda F, Fuentelsaz C, Anders G, Sindermann H, Engel J, Berman J. Treatment of Bolivian mucosal leishmaniasis with miltefosine. *Clin Infect Dis*. 2007; 44(3):350–356. DOI: 10.1086/510588
- [120] Andrade HM, Toledo VP, Pinheiro MB, Guimarães TM, Oliveira NC, Castro JA, Silva RN, Amorim AC, Brandão RM, Yoko M, Silva AS, Dumont K, Ribeiro ML Jr, Bartchewsky W, Monte SJ. Evaluation of miltefosine for the treatment of dogs naturally infected with *L. infantum* (= *L. chagasi*) in Brazil. *Vet Parasitol*. 2011; 181(2–4):83–90. DOI: 10.1016/j.vetpar.2011.05.009
- [121] Gómez-Ochoa P, Castillo JA, Gascón M, Zarate JJ, Alvarez F, Couto CG. Use of domperidone in the treatment of canine visceral leishmaniasis: a clinical trial. *Vet J*. 2009; 179(2):259–263. DOI: 10.1016/j.tvjl.2007.09.014
- [122] Sabaté D, Llinás J, Homedes J, Sust M, Ferrer L. A single-centre, open-label, controlled, randomized clinical trial to assess the preventive efficacy of a domperidone-based treatment programme against clinical canine leishmaniasis in a high prevalence area. *Prevent Vet Med*. 2014; 115(1–2):56–63. DOI: 10.1016/j.prevetmed.2014.03.010
- [123] Noli C, Auxilia S.T. Treatment of canine Old World visceral leishmaniasis: a systematic review. *Vet Dermatol*. 2005; 16(4):213–232. DOI: 10.1111/j.1365-3164.2005.00460.x
- [124] Athanasiou LV, Saridomichelakis MN, Kontos VI, Spanakos G, Rallis TS. Treatment of canine leishmaniasis with aminosidine at an optimized dosage regimen: a pilot open clinical trial. *Vet Parasitol*. 2013; 192(1–3):91–97. DOI: 10.1016/j.vetpar.2012.10.011
- [125] Musa AM, Noazin S, Khalil EA, Modabber F. Immunological stimulation for the treatment of leishmaniasis: a modality worthy of serious consideration. *Trans R Soc Trop Med Hyg*. 2010; 104(1):1–2. DOI: 10.1016/j.trstmh.2009.07.026
- [126] Miret J, Nascimento E, Sampaio W, França JC, Fujiwara RT, Vale A, Dias ES, Vieira E, Costa RT, Mayrink W, Neto AC, Reed S. Evaluation of an immunochemotherapeutic protocol constituted of N-methyl meglumine antimoniate (Glucantime®) and the recombinant Leish-110F® + MPL-SE® vaccine to treat canine visceral leishmaniasis. *Vaccine*. 2008; 26:1585–1594. DOI: 10.1016/j.vaccine.2008.01.026
- [127] Borja-Cabrera GP, Santos FN, Santos FB, Trivellato FAA, Kawasaki JK, Costa AC, Castro T, Nogueira FS, Moreira MAB, Luvizotto MCR, Palatnik M, Palatnik-de-Sousa CB. Immunotherapy with the saponin enriched-Leishmune® vaccine versus immunochemotherapy in dogs with natural canine visceral leishmaniasis. *Vaccine*. 2010; (8):597–603. DOI: 10.1016/j.vaccine.2009.09.071

- [128] Joshi J, Malla N, Kaur S. A comparative evaluation of efficacy of chemotherapy, immunotherapy and immunochemotherapy in visceral leishmaniasis an experimental study. *Parasitol Int.* 2014; 63(4):612–620. DOI: 10.1016/j.parint.2014.04.002
- [129] Grandoni L. Canine leishmaniavaccines: still a long way to go. *Vet Parasitol.* 2015; 208(1-2):94–100. DOI: 10.1016/j.vetpar.2015.01.003.
- [130] Palatnik-De-Sousa, C.B. Vaccines for canine leishmaniasis. *Front Immunol.* 2012;3:69. DOI: 10.3389/fimmu.2012.00069
- [131] da Silva VO, Borja-Cabrera GP, Correia Pontes NN, de Souza EP, Luz KG, Palatnik M, Palatnik de Sousa CB. A phase III trial of efficacy of the FML-vaccine against canine kala-azar in an endemic area of Brazil (São Gonçalo do Amarante, RN). *Vaccine.* 2001; 19(9–10):1082–1092. DOI: 10.1016/S0264-410X(00)00339-X
- [132] Costa-Pereira, C, Moreira ML, Soares RP, Marteleto BH, Ribeiro VM, França-Dias MH, Cardoso LM, Viana KF, Giunchetti RC, Martins-Filho OA, Araújo MS. One-year timeline kinetics of cytokine-mediated cellular immunity in dogs vaccinated against visceral leishmaniasis. *BCM Vet Res.* 2015;11:92. DOI: 10.1186/s12917-015-0397-6
- [133] Borja-Cabrera GP, Correia Pontes NN, da Silva VO, Paraguai de Souza E, Santos WR, Gomes EM, Luz KG, Palatnik M, Palatnik-de-Sousa CB. Long lasting protection against canine kala-azar using the FML-QuilAsaponin vaccine in an endemic area of Brazil (São Gonçalo do Amarante, RN). *Vaccine.* 2002; 20(27–28):3277–3284. DOI: 10.1016/S0264-410X(02)00294-3
- [134] Fernandes AP, Costa MM, Coelho EA, Michalick MS, de Freitas E, Melo MN, Luiz Tafuri W, Resende DM, Hermont V, Abrantes CF, Gazzinelli RT. Protective immunity against challenge with *Leishmania (Leishmania) chagasi* in beagle dogs vaccinated with recombinant A2 protein. *Vaccine.* 2008; 26(46):5888–5895. DOI: 10.1016/j.vaccine.2008.05.095
- [135] Testasica MCS, dos Santos MS, Machado LM, Serufo AV, Doro D, Avelar D, Tibúrcio AM, Abrantes Cde F, Machado-Coelho GL, Grimaldi G Jr, Gazzinelli RT, Fernandes AP. Antibody responses induced by Leish-Tec[®], an A2-based vaccine for visceral leishmaniasis, in a heterogeneous canine population. *Vet Parasitol.* 2014;4(3–4):169–176. DOI: 10.1016/j.vetpar.2014.04.025
- [136] Brasil. Ministério da Saúde. Esclarecimento sobre substituição do protocolo diagnóstico da leishmaniose visceral canina. 2011. Nota técnica conjunta nr. 01/2011 -CGDT-CGLAB/DEVIT/SVS/MS.
- [137] Grimaldi G Jr, Teva A, Ferreira AL, dos Santos CB, Pinto Id, de-Azevedo CT, Falqueto A. Evaluation of a novel chromatographic immunoassay based on Dual-Path Platform technology (DPP[®] CVL rapid test) for the serodiagnosis of canine visceral leishmaniasis. *Trans R Soc Trop Med Hyg.* 2012; 106(1):54–59. DOI: 10.1016/j.trstmh.2011.10.001
- [138] Laurenti MD, de Santana Leandro MV Jr, Tomokane TY, De Lucca HR, Aschar M, Souza CS, Silva RM, Marcondes M, da Matta VL. Comparative evaluation of the DPP[®] CVL

- rapid test for canine serodiagnosis in area of visceral leishmaniasis. *VetParasitol.* 2014; 205(3–4):444–450. DOI: 10.1016/j.vetpar.2014.09.002
- [139] Schubach EY, Figueiredo FB, Romero GA. Accuracy and reproducibility of a rapid chromatographic immunoassay for the diagnosis of canine visceral leishmaniasis in Brazil. *Trans R Soc Trop Med Hyg.* 2014; 108(9):568–574. DOI: 10.1093/trstmh/tru109
- [140] Peixoto HM, de Oliveira MR, Romero GA. Serological diagnosis of canine visceral leishmaniasis in Brazil: systematic review and meta-analysis. *Trop Med Int Health.* 2015; 20(3):334–352. DOI: 10.1111/tmi.12429
- [141] Souza Filho JA, Barbosa JR, Figueiredo FB, Mendes AA Jr, Silva SR, Coelho GL, Marcelino AP. Performance of Alere™ immunochromatographic test for the diagnosis of canine visceral leishmaniasis. *Vet Parasitol.* 2016; 225:114–116. DOI: 10.1016/j.vetpar.2016.06.011
- [142] de Oliveira IQ, Silva RA, Sucupira MV, da Silva ED, Reis AB, Grimaldi G Jr, Fraga DB, Veras PS. Multi-antigen print immunoassay (MAPIA)-based evaluation of novel recombinant *Leishmania infantum* antigens for the serodiagnosis of canine visceral leishmaniasis. *Parasit Vectors.* 2015; 8:45. DOI: 10.1186/s13071-015-0651-6
- [143] Organização Panamericana de Saúde. WHO-PAHO Expert Consultation on Visceral Leishmaniasis in The Americas. Consulta de expertos OPS/OMA sobre leishmaniasis visceral em las Américas [Internet]. 2005. Available from: http://bvs1.panaftosa.org.br/local/File/textoc/LEANES_Inf_final_leish_2005.pdf#page=28 [Accessed: 2016-09-01]
- [144] Brasil. Ministério da Saúde. Funasa: 20 years in the heart of Brazil. Brasília: Ministério da Saúde, Fundação Nacional de Saúde, 2011. 52 p.
- [145] Zuben APBV, Donalísio MR. Difficulties in implementing the guidelines of the Brazilian Visceral Leishmaniasis Control Program in large cities. *Cad Saúde Pública.* 2016; 2(6): 1–11. DOI: 10.1590/0102-311X00087415

