

Aortic Root Reconstruction

Salah E. Altarabsheh, Salil V. Deo and Yakov E. Elgudin

Abstract

Aortic root reconstruction represents one of the most complex areas of cardiac surgery as well as one of the most dynamic-major developments in understanding of the aortic root anatomy and physiology, improvements in imaging and surgical technique allowed for development and acceptance into clinical practice of several novel procedures over last couple of decades. From first aortic root replacement reported by Bentall and De Bono in 1968 to aortic root reimplantation (David procedure) and remodeling (Yacoub operation) with multiple contemporary modifications, aortic root reconstruction now is widely used in treatment of chronic aortic aneurysmal disease and acute aortic dissections alike. Basic principles of aortic root structure and function and critical operative strategies for aortic root surgery are reviewed in this chapter.

Keywords: aortic root, aneurysm, replacement, reimplantation, remodeling, dissection

1. Introduction

The technique of aortic root surgery has undergone many improvements during the past decades. These are a direct result of better understanding of the functional hemodynamics of the aortic root coupled with significant improvement in imaging. We present here a brief overview of pathology involving the aortic root with a special focus on the surgical aspects in these operative procedures. Our chapter includes tips on use of mechanical valve conduits, homograft, and stent-less valve prostheses as well as techniques implementing a valve-sparing approach.

2. Anatomy and physiology of the aortic root

Improved imaging and computer simulation has increased our understanding of the aortic root anatomy, structure and function. Aortic root had been described as the vascular tube supporting the aortic valve leaflets and connecting the left ventricular outflow tract inferiorly to the sinotubular junction superiorly [1]. Two thirds of the lower segment (aortic annulus) of the aortic root is attached to the interventricular septum while the remainder is attached to the fibrous part of the anterior mitral valve leaflet [2]. This tubular structure (**Figure 1**) encompasses the aortic valve leaflets, coronary ostia, commissures, interleaflet triangles and the sinuses [1]. All these components link together to act as a single unit. It is now clear, that this is much more than just a passive unit governed by pressure changes across the valve [3, 4]. The geometric relationship of the valve leaflets as well as individual lengths are important for it to work as a single efficient hemodynamic unit [5].

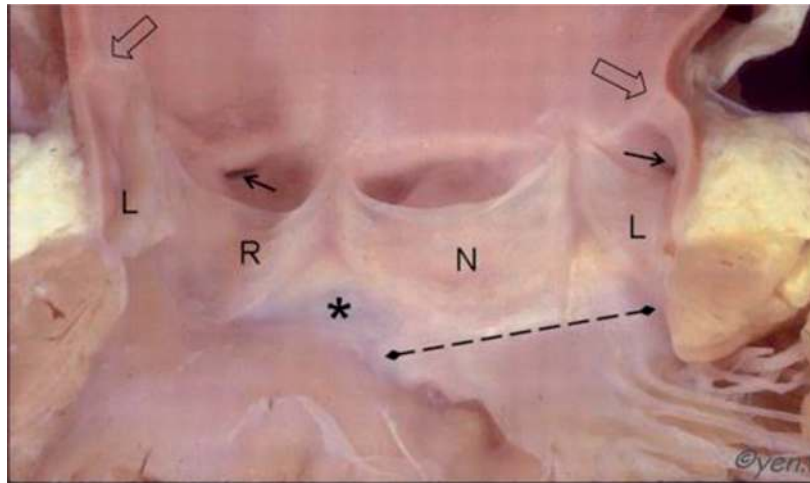


Figure 1. Opened aortic root section. Sinotubular junction is indicated by the open arrows, small arrows indicating the coronary ostia (left and right), broken lines indicating the fibrous skeleton between the aortic and mitral valves. L, R, and N mark the left, right and the non-coronary cusps, respectively [6].

The dilated portion of the aortic wall between the aortic annulus and sino-tubular junction is known as the sinus of Valsalva. These sinuses are named according to the relationship of the origin of the coronary ostia from the root that is left, right or non-coronary sinuses. The sinuses are labelled corresponding to their coronary ostia. One of the important roles provided by these sinuses is preventing obstruction of the coronary ostia during movement of the aortic valve leaflets against the aortic wall, so that coronary blood flow is maintained [5]. An important function is prevention of ostial obstruction during systole when the aortic valve is open [7]. Generation of Eddy currents during early systole prevents the aortic leaflets from touching the aortic wall [8].

The aortic valve leaflets which are inserted at their bases in a semilunar fashion to the aortic annulus. They allow uni-directional flow of blood from the left ventricle to the aorta. Aortic valve leaflets are variable in size and number, the non-coronary cusp being the largest compared to the left or right aortic valve cusps. The most common variation is the bicuspid aortic valve, which consists of a semi-lunar opening due to the presence of two leaflets, and the commonest deviation from the normal tri-leaflet pattern is the known congenital anomaly called bicuspid aortic valve [9]. The attachment of the curved aortic valve leaflets form the triangular space named as the interleaflet triangles, the apices of these triangles is known as the valve commissures which are at the level of the sinotubular junction [10]. Aortic valve competence depends on the overlap between these adjacent free margins of the leaflets.

The aortic valve annulus represents the ventriculo-aortic junction which is a complex structure and universally accepted term as aortic annulus [9]. The basic attachments of the aortic valve leaflets at the aortic annulus comprise muscular and fibrous parts [5]. The right aortic valve leaflet attaches to both the membranous and the interventricular septa, while the non-coronary leaflet attaches to the membranous septum and the fibrous skeleton of the anterior mitral valve leaflet, and the left aortic valve leaflet attaches to the fibrous skeleton of the anterior mitral valve leaflet and partly to the interventricular septum [9]. Connective tissue disorders that involve the fibrous skeleton of the aortic root lead to alteration in normal geometry. Damage begets further damage leading to significant valve distortion and subsequent clinical sequelae [9].

3. Aortic root pathology

3.1 Connective tissue disorders

Connective tissue disorder is among the most common non-infective etiology of aortic root pathology. Marfan's syndrome, Ehlers-Danlos syndrome and Loeys-Dietz syndrome predominantly involve the elastic aortic root [11–13]. Marfan's syndrome is an autosomal dominant disorder characterized by mutation in the gene encoding for fibrillin-1. It leads to cystic medial necrosis and involves all connective tissue containing high percentages of elastin. Disease is multi-systemic; however aortic dissection remains an important cause of mortality [14]. The probability of aortic emergencies increases significantly when transverse aortic diameters is more than 45 mm [15].

Patients with vascular type of the Ehlers-Danlos syndrome are prone to aortic dissection rather than aneurysm, while patients with Loeys-Dietz syndrome are liable to have aortic aneurysm and dissection at younger age [11, 16, 17].

3.2 Bicuspid aortic valve

Bicuspid aortic valve (BAV) is present in 1–2% of the population; almost 40% also have thoracic aortic dilatation at the time of presentation [18].

While the inheritance of BAV is not clearly defined, gene sequence defects leading to aortopathy is more prevalent in this population [19]. Degenerative changes in the tunica media with reduced elastin increases risk of dissection these patients [20, 21].

3.3 Inflammatory etiology

Giant cell arteritis and Takayasu arteritis are rarer causes of aneurysmal dilatation/aortic dissection [22, 23]. While temporal artery involvement is the hallmark of giant cell arteritis, at least 0.15% also had aortic dissection in an autopsy series [22]. Takayasu arteritis on the other hand is an inflammatory disorder that leads to large vessel inflammation characterized by fibrosis and narrowing, which may lead to aneurysmal formation and possible rupture [23]. Corticosteroids are used for acute therapy and surgery is performed once active inflammation subsides [24, 25].

3.4 Cystic medial necrosis

Cystic medial necrosis (CMN) is a pathological term that is characterized by the formation of cyst like lesions in the medial layer of the large arteries with accumulation of basophilic substances [26].

4. Aortic root aneurysm

The American Association of Thoracic Surgeons present following guidelines regarding surgery for the ascending aorta [27]:

- a. Surgical repair should be performed when aortic diameter (root or ascending aorta) is 55 mm or more.
- b. Surgical repair should be performed when aortic diameter (root or ascending aorta) is 50 mm or more in the presence of certain risk factors such as: root

phenotype bicuspid aortic valve, uncontrolled hypertension, history of aortic dissection or sudden death in the family, annual enlargement of 3 mm or more in the size of the aortic aneurysm, or predominantly aortic regurgitation.

c. Surgical repair should be performed when aortic diameter (root or ascending aorta) is 50 mm or more in patients with low operative risk being performed by experienced aortic surgical team in centers with well-established surgical outcomes

d. Surgical repair should be performed when aortic diameter (root or ascending aorta) is 45 mm or more in patients undergoing concomitant other cardiac surgery.

Patients with Marfan's syndrome or Marfanoid habitus should be operated when their aortic root/ascending aorta is larger than 50 mm in maximal transverse diameter [28]. Gott and colleagues [27, 28] reported an improved 30-day survival in a series of 675 patients with Marfan's syndrome who underwent elective compared to urgent or emergency replacement of the aortic root.

If patients have a family history of aortic dissection, demonstrate an annual increase of 3 mm or have significant aortic regurgitation, then aortic root surgery is warranted when diameters exceed 45 mm [29]. Hormonal changes during pregnancy significantly increase risk of aortic dissection. Hence, women of child-bearing age who are keen to have a family are recommended surgery prior to pregnancy. These guidelines are also applicable to patients with Ehlers-Danlos syndrome and Loeys-Dietz syndrome.

5. Sinus of Valsalva aneurysm

Sinus of Valsalva aneurysms are rare; reported in 0.09% of autopsy series [30]. This condition affects commonly the right coronary sinus to a lesser degree the non-coronary sinus; involvement of all three sinuses is reported but exceedingly uncommon [31]. While idiopathic in majority, endocarditis is a rare cause [32]. Surgery is indicated to prevent rupture [32]. Rupture is often into an adjacent heart chamber with high-output failure [33]. Surgery consists of patch closure of the involved sinus. Approach can be from the aorta as well as via the other heart chamber that the fistula opens [30].

6. Aortic dissection

Acute aortic dissection is a high-risk aortic catastrophe which occurs in 5–30/1,000,000 patient annually [37]. Almost 1/5th die before reaching the emergency [38]. The initiating factor is often uncontrolled hypertension. Patients may have an intra-mural hematoma prior to developing dissection.

Aortic dissection is classified according to the time after the start of symptoms, being acute if the time frame between the onset of symptoms and presentation is less than 14 days, and chronic if this period is more than 14 days [34]. Anatomical classification is based on the location and extension of the primary tear (**Figure 2**). Dr. DeBakey and colleagues [35] described a method of classification that differentiates the aortic segments involved into: Type I, when the dissections is involving all the aortic segments, while Type II, when the dissection is confined to the ascending aorta, while Type III, when the dissection process is affecting the descending

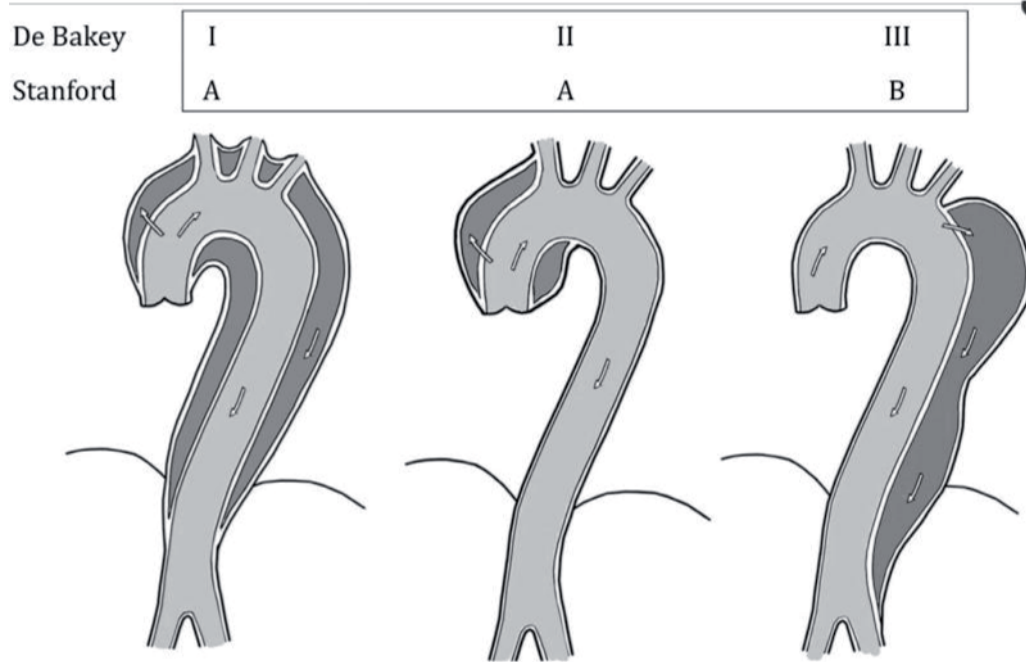


Figure 2. The anatomical classification of aortic dissection according to the location of the primary tear and the extent of the aortic segment involved are illustrated [36].

thoracic aorta. A more functional classification was introduced by the Stanford University; type A if the dissection involves the ascending aorta, type B if it does not [37].

The devastating complications that may occur with aortic dissection including organ malperfusion syndromes, acute aortic regurgitation, pericardial tamponade and stroke [38]. Surgery is currently the gold standard for acute care of type A aortic dissection [38].

7. Bentall procedure

Bentall and de Bono described their technique of aortic root replacement with a synthetic tube graft and contained prosthetic valve [39]. The coronary ostia were implanted in an end to side fashion without coronary mobilization [39]. Bleeding and pseudo-aneurysms were important complications with their procedure [40]. The present method of coronary mobilization and anastomosis was introduced by Nicholas Kouchoukas [14].

Use of improved graft substitutes and local hemostatic agents have made this procedure safer [41]. Results are good in centers performing these procedures in high volume [40].

The Bentall procedure in younger patients is often performed with a mechanical valve conduit. Appropriate anti-coagulation is important to maintain event-free survival [42]. A recent meta-analysis of 7600 [42] patients who had a mechanical valve conduit reported reoperation rates of Bentall procedure using mechanical valve conduits that the annual linearized rate of occurrence of aortic root re-operation 0.45% (0.039–0.59%). Late mortality was 2.02% (1.77–2.31%) and for hemorrhage was 0.64% (0.47–0.87%) During a mean follow up of 6 years.

However, in older patients, or those who refuse/have contraindications for anti-coagulation, a biologic valve substitute can be used [43]. Gaudino and colleagues

demonstrated in a propensity matched cohorts that included patients who underwent aortic root replacement utilizing mechanical valved conduit versus biological valved conduit versus valve sparing procedure that the type of procedure did not influence early or late outcome, however rate of aortic re-operation was 0, 2.4, 7.3% at 5 years for mechanical, biological valved conduits and valve sparing procedure, respectively [43].

8. Aortic root replacement with cryopreserved homograft

Aortic root replacement with cryopreserved homograft tissue is often used for patients with an infected aortic root [44]. The structure of the homograft that includes the muscular part of the left ventricular outflow tract, the anterior mitral leaflet and the aorto-mitral continuity; these provide additional tissue to fill gaps created by aggressive debridement while treating endocarditis [44, 45]. Homograft provide excellent hemodynamics and do not need anti-coagulation. Reports demonstrate improved left ventricular mass regression and ejection fraction after homograft root replacement [46]. However, we would caution their use in young patients. Valve degeneration and subsequent need for re-operation is often inversely proportional to age at implant [44] (**Figure 3**).

We feel that appropriate debridement rather than prosthesis selection determines outcome in patients with aortic root abscess. Jassar et al. reported similar rates of reinfection and reoperation in 134 patients who had aortic root replacement using either cryopreserved homograft, biological or mechanical valved conduits [47].

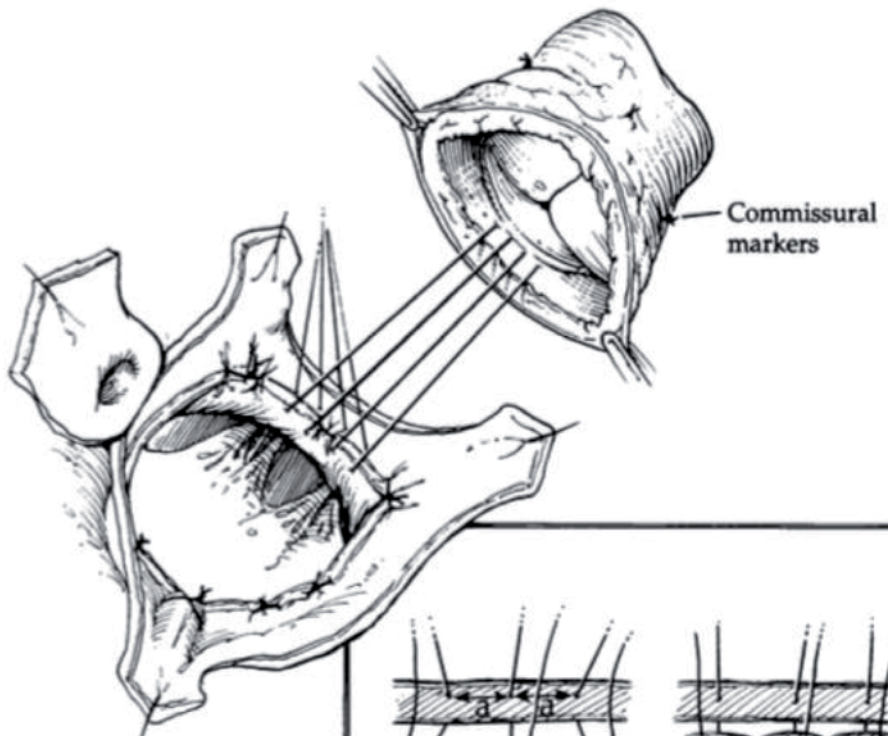


Figure 3.
The insertion of cryopreserved aortic homograft is indicated [48].

9. Aortic root replacement using stentless xenograft

Stent-less valve conduit (Freestyle™ valve conduit, Medtronic Corporation, Minnesota, USA) are commercially easily available when compared to homograft tissue. Thus, in recent years, they are the prosthesis of choice for aortic root replacement in the elderly or those with an infective etiology [49]. Hemodynamics match those of homograft, especially in patients with a small aortic root [50]. The sinus structure of these valves mirrors the native aortic root; an additional benefit when compared to a stented valve conduit [49]. However, unlike stented bio-prostheses, the mechanism of failure of these valves is often leaflet tears [51]. These can occur suddenly leading to acute aortic regurgitation and left heart failure. LeMaire and colleagues demonstrated in 132 patients who had porcine bioprosthesis replacement that there was no structural valve dysfunction in any case during the 5 year follow up period [52] (**Figure 4**).

Here are the relevant steps that we use for our root replacement procedures. These steps remain the same irrespective of the type of prosthesis (mechanical valved-conduit or bioprosthesis):

1. We routinely cannulate the right axillary artery for arterial access in cardiopulmonary bypass in all patients with ascending aortic involvement with aneurysmal disease and certainly in all patients with aortic dissection. Our preferred method is direct cannulation of the axillary artery with a straight cannula (usually 18 or 20Fr); otherwise, an 8 mm vascular graft anastomosed in end-to-side manner to the vessel is used.

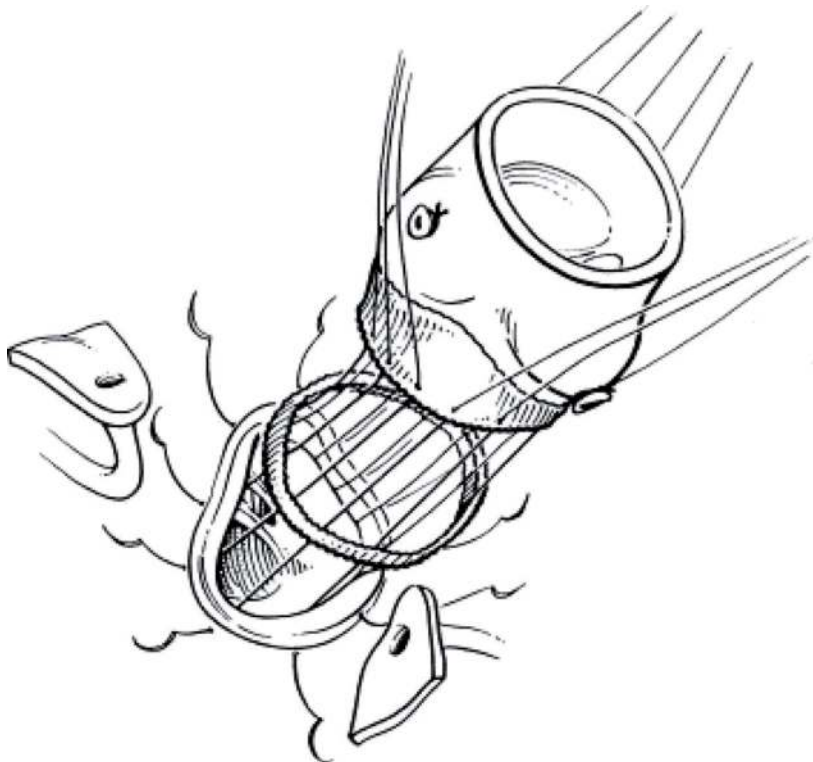


Figure 4.
The free style porcine bioprosthesis with re-implantation of the coronary buttons is demonstrated [53].

2. Upon median sternotomy, pericardium is opened and suspended. Ascending aorta is prepared depending on distal extent of aortic intervention. If feasible, ascending aorta is freed of attachments from the right PA posteriorly and main PA to on the left and taken with an umbilical tape which facilitates further manipulations of the ascending aorta. During this step, it is important to stay close to the aortic wall to avoid injury to the pulmonary artery. For primary aortic root replacement, it is almost always possible to identify and follow such connective tissue plane between the aorta and the pulmonary artery. For a redo operation, it is more difficult and carries some serious risks. We prefer to use cautery dissection rather than scissors or blunt dissection as we feel this technique reduces postoperative bleeding. Small arterial and venous branches are often present between the aorta and pulmonary artery, particularly as one proceeds with dissection more proximally. These are divided between clips. This initial dissection is preferably done prior to full heparinization.
3. Once the ascending aorta is mostly free of attachments and likely looped with an atraumatic tape, we give IV Heparin and cannulate aorta or the right axillary artery and right atrium for cardiopulmonary bypass. We always use retrograde cardioplegia delivered into the coronary sinus and use either a PA or an LV vent inserted via the right superior pulmonary vein.
4. Once aorta is cross-clamped and heart is arrested with a combination of antegrade and retrograde cardioplegia, the aorta is transected in mid portion. Clear identification of the ostium of the right coronary artery (RCA) is required, so that the initial cut through the ascending aorta is placed far enough away from the RCA ostium. It is also important to divide ascending aorta in a way that there is at least a couple of centimeters of the aortic wall above the ostium of the left main coronary artery (LMCA).
5. At this stage we place 4–0 silk stay sutures at the tips of the aortic valve commissures. Aortic valve is then excised, annulus is sized. When a Freestyle valve conduit is used, there is no need to have a cylinder-shaped sizer pass into the LV through the annulus as the prosthetic valve will be fixed in the supra annular position. As such, a larger prosthetic valve can be used. Sizing for a mechanical valve conduit has to be done according to the manufacturer recommendations as most of the mechanical valves are designed for an intra-annular position.
6. At this stage, additional dissection is carried out between the aortic root and pulmonary artery and RVOT. Unlike for a valve sparing aortic root replacement with root re-implantation, this dissection for a Bentall operation is limited to clearing the space for a safe fashioning of the coronary buttons, particularly, for the LMCA. There is no need to dissect deep between the aortic root and the RVOT to expose the aortic annulus from the outside.
7. Preparation of the coronary buttons is similar for any aortic root replacement operation. Normally, we start with the left coronary button. Here are the critical points and pitfalls:
 - Prior to cutting the button out of the corresponding sinus, we recommend marking up the “12 o'clock” point—the top of the button is marked with marker pen or a prolene stitch. This would allow for a precise orientation of the button when re-implanted into a sinus of the valve conduit. Tension or kinking or rotation of the re-implanted button may result in coronary ischemia and create a serious problem at the conclusion of the operation;

- Once the top of the button is marked, we start with cutting the left coronary sinus from the top of the commissure between the left and non-coronary cusps down towards the annulus of the left sinus. Most of the time, the actual opening of the LMCA is kept in the middle of the button on all four aspects of it. In larger root aneurysms, there is occasionally too much tissue in the sinus, so attention should be paid to the size of the button 0.5–1.0 cm off of the edge of the ostium of the LMCA is usually enough for a safe button re-implantation;
 - The initial cut has to keep ~5–7 mm of the sinus tissue in place, so as we come down along the commissure, the tip of the scissors is turned away from the annulus and the cut is curved around the lower edge of the coronary artery ostium;
 - Next, we start the cut from the top of the commissure between the left and right sinuses. It is critical to fully understand the course of the LMCA to avoid injury to it in case of intramural passing in the aortic wall. Large coronary probe can be placed in the lumen to check the direction of the LMCA. The cut is then curved away from the annulus leaving the same 5–7 mm of the sinus tissue in place and completing a “button” by connecting with incision made from the other direction.
 - Great care has to be taken here as to not apply any excessive pulling on any portion of the button while making the cuts as this can lead to distortion and asymmetric fashioning of the button making safe re-implantation difficult;
 - Once the LMCA button is fashioned out, the connective tissue and fat between the lower edge of the button and rim of the sinus remnant and the annulus is divided with cautery to provide just enough mobility for the coronary button to facilitate re-implanting process;
 - Preparation of the RCA button follows the same general principles as described for the LMCA button—marking the top to maintain orientation, avoiding excessive pulling while fashioning the button, maintaining enough sinus tissue on the button itself as well as on the annulus.
8. After both buttons are prepared, inflow suture line is created. For a mechanical prosthesis, we use 2–0 pledgeted stitches with the pledgets placed in a supraannular position. It is important to ensure that the pledgets are lined next to each other without much gap as this will ensure hemostasis. Some use a secondary continuous prolene layer to seal this anastomosis. With Freestyle bioprosthesis, we use simple 2–0 interrupted stitches. A pericardial strip is then gently placed between the loops prior to knotting. The pericardial strip acts as a gusset and also provides additional hemostasis to this layer.
9. Additional important point has to be made for cases when Freestyle conduit is used. Orientation of the valve is of critical importance prior to drawing inflow sutures through the valve. We recommend rotating the valve 120° clockwise from its natural orientation, so that a non-coronary sinus of the valve would now become a left coronary sinus into which LMCA is re-implanted. Such rotation will make left coronary sinus of the valve a new right sinus into which RCA button will be re-implanted. The right button of the Freestyle remains unused and has to be over sawn with 4–0 or 5–0 pledgeted sutures.
10. Once an opening in the new left sinus is made with coronary punch, the coronary button is anastomosed using 5–0 prolene. We use a technique of

plicating the wall of the coronary button. A second layer is then used to ensure further hemostasis. Re-implantation of the right button is performed in a similar fashion. Once the aortic root is replaced and buttons re-implanted, we use local hemostatic glue to provide further sealing of needle holes.

11. Then depending upon the extent of aortic dilatation, the ascending aorta is replaced and attached to the proximal neo-root.
12. Once the patient is off cardiopulmonary bypass, the right axillary artery is carefully repaired between hemostatic clamps. A good Doppler signal is essential after repair.
13. It is important to ensure absolute hemostasis in the operating room prior to transferring the patient to the intensive care unit.

10. Valve sparing aortic root replacement

Sparing the patient's native aortic valve while replacing the aortic root is an alternative option in selected patients [54]. This naturally avoids need for anti-coagulation [9]. After an initial pre-operative trans-esophageal echocardiogram, the valve leaflets should be examined prior to proceeding with valve-sparing approach. Leaflet quality is fundamental to event-free survival in these patients.

10.1 Aortic re-implantation technique

David and Feindel [9] recommend a technique of securing the aortic valve leaflets without the rigid synthetic graft. This technique prevents future annular dilatation. Dr. David et al. report excellent valve competence among 146 Marfan's syndrome patients with valve-sparing aortic root replacement with their technique [55] (**Figure 5**).

All preparatory steps for re-implantation procedure are similar as described above. Below are the critical steps unique for the re-implantation:

- Once coronary buttons are prepared as described above, aortic annulus has to be dissected out so that on all sinuses the annulus can be exposed for precise placement of the sub-annular sutures. We use cautery at low settings to perform this dissection. The most difficult part of this step is to separate the root and the annulus from the RVOT. There is always a connective tissue plane between these structures which allows safe dissection down to the annulus;
- Sizing of the annulus can be done by many previously described methods. We prefer to follow a simple rule that most of the male with BSA of $\sim 2.0\text{--}2.2\text{ m}^2$ should have annulus of 23–25 mm, and so 3–5 mm larger diameter of the vascular graft would be chosen (most commonly, 28 or 30 mm). For a smaller female patient with a BSA of $1.8\text{--}2.0\text{ m}^2$ an annular diameter is 21–23 mm and accordingly 26–28 mm grafts are usually appropriate;
- We prefer “Valsalva” grafts (Vascutek) which we trim on the inflow side leaving 2–3 mm (a couple of rings) of the grafts for the sub-annular sutures to be drawn through;
- We then place sub-annular 2–0 ticon sutures with small pledgetes 2–3 mm below the annulus in the following order: the nadir of the non-coronary sinus; the

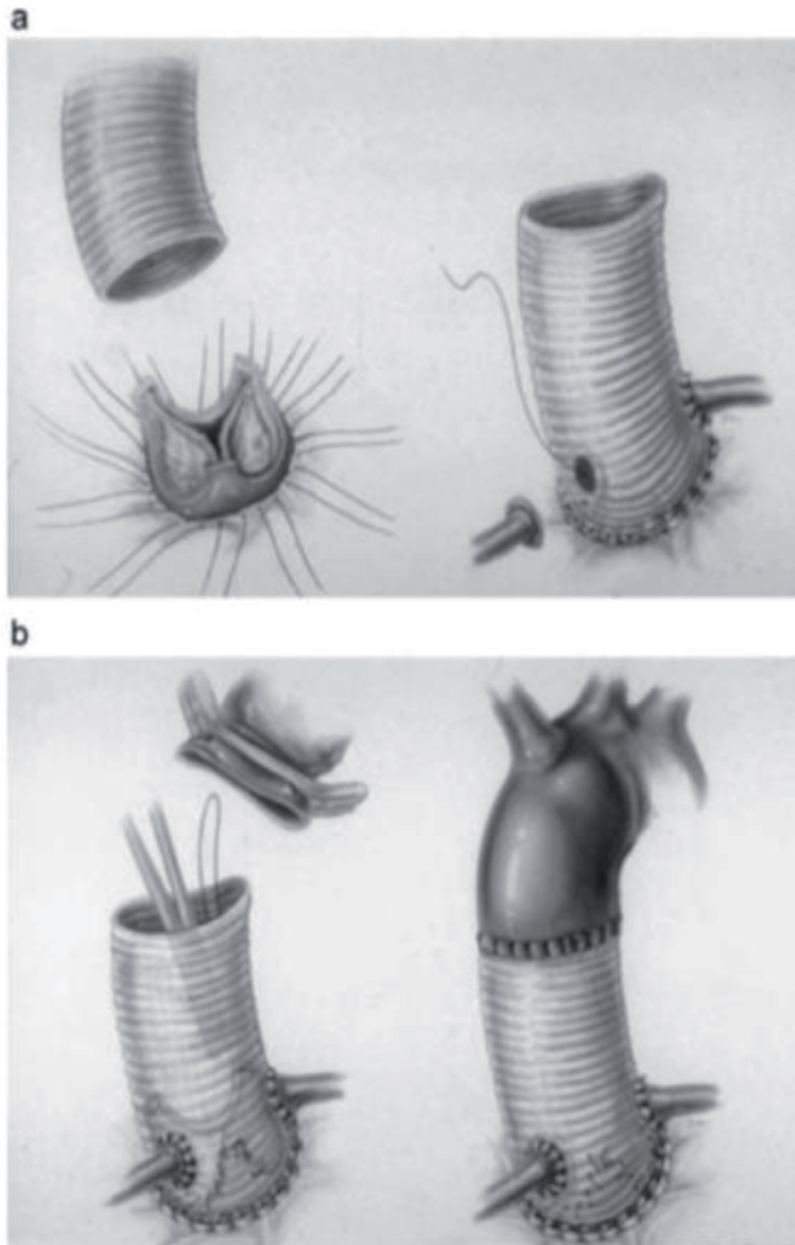


Figure 5. The aortic re-implantation technique is illustrated (a). As demonstrated, the entire aortic annulus, aortic valve and a rim of aortic wall are all secured inside the synthetic graft, with re-implantation of the coronary buttons to the new graft (b). The distal part of the synthetic graft is anastomosed to the ascending aorta [9].

left-to-non commissure; the nadir of the left coronary sinus; the nadir of the right coronary sinus; the right to-non commissure (avoiding membranous septum); extra sutures placed between the ones mentioned above can be added in between the nadirs and the commissural sutures to a total of 6–9 sutures if needed;

- Inflow edge of the Valsalva graft then marked to assure precise positioning of the sub annular sutures on the vascular graft;
- Sub annular sutures are then drawn through the graft according to the markings;
- In re-implantation procedure, instead of silk stay sutures at the tips of the commissures, we use 4–0 prolene with large needles. These stay sutures are brought

inside of the graft at this stage, so that the graft is brought over, seated and fixed over the annulus by tying the sub-annular sutures;

- Prolene sutures from the tips of the commissures are then drawn through the graft at the junction of the horizontal and vertical parts of the Valsalva graft;
- Re-implantation of the aortic root is then started by suturing of the remnant of the coronary sinuses inside of the Valsalva graft. We routinely use double armed 4-0 or 5-0 Prolene and start the suture line just off the bottom of the sinus and proceeding towards the commissure between left and non-coronary sinuses bringing the stitch to the top of the commissure on the outside. The other arm of the suture is then brought up the same way to the top of the left and right commissure;
- Similar technique is then used to re-implant the right and finally the left coronary sinuses;
- All three stay sutures are then tied and cut on top of the commissures followed by “working” sutures brought to the top of the corresponding commissures;
- The valve is then checked for AI by filling the root with cold saline;
- Coronary buttons are then re-implanted into corresponding sinuses as described above.

10.2 Aortic remodeling technique

Yacoub developed his technique of creating three longitudinal neo-sinuses [56]. These are sutured to the aorta and then coronary buttons are re-implanted. This method does not protect against annular dilatation [9]. In this technique the

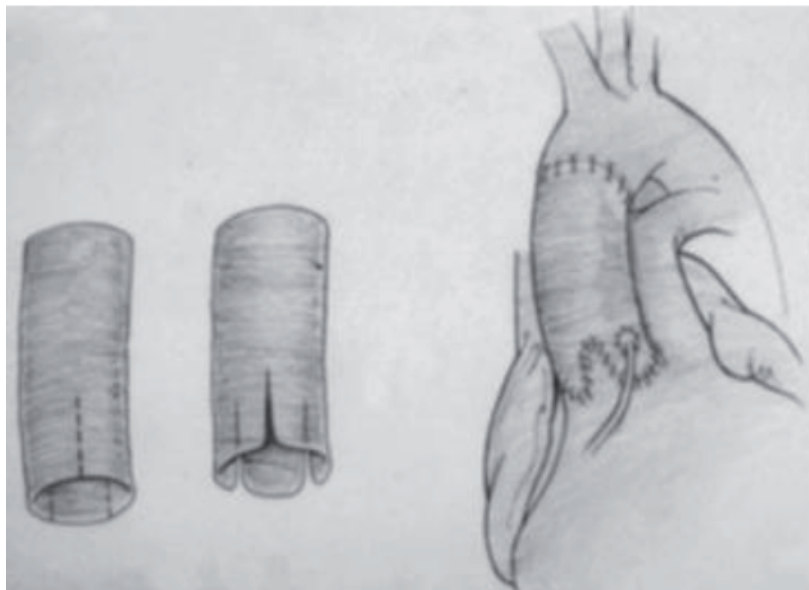


Figure 6.

The aortic remodeling technique is described. As shown, the aortic commissures are sewn to the graft, which is fashioned to form neo sinuses. Then the created tongues are sewn to the rim of the aortic wall. Coronary buttons re-implantation follows, then distal anastomosis between the graft and the ascending aorta is performed [9].

synthetic graft is fashioned into three longitudinal neo sinuses, then after securing the valve commissures to the neo graft, the margins of the neo sinuses are anastomosed to the rim of the aortic wall. Coronary button re-implantation to the neo sinuses follows, and distal anastomosis of the neo graft to the ascending aorta completed the procedure (**Figure 6**).

11. Summary

Aortic root operations reflect complex anatomic relations and physiologic interactions between the left ventricle and components of the aortic root—ventriculo-arterial junction (aortic annulus), sinuses of Valsalva, leaflets of the aortic valve, and sino-tubular junction. Whether a surgeon contemplates classic aortic root replacement with mechanical or tissue valve conduits or any of the valve sparing root reconstructions, close familiarity with the structure and function of the aortic root is necessary. Dreaded complications of such complex procedures (bleeding, most importantly) can be avoided by meticulous surgical technique in combination with intimate knowledge of the anatomical details of the aortic root and surrounding structures.

Disclaimer

The views expressed are those of the authors and do not necessarily reflect the position or policy of the Department of Veteran Affairs or the United States Government.

Author details


Salah E. Altarabsheh¹, Salil V. Deo² and Yakov E. Elgudin^{2*}

¹ Department of Cardiac Surgery, Queen Alia Heart Institute, Amman, Jordan

² Division of Cardiothoracic Surgery, Louis Stokes Cleveland VA Medical Center, Cleveland, Ohio, USA

*Address all correspondence to: yakov.elgudin@uhhospitals.org

IntechOpen

© 2019 The Author(s). Licensee IntechOpen. This chapter is distributed under the terms of the Creative Commons Attribution License (<http://creativecommons.org/licenses/by/3.0>), which permits unrestricted use, distribution, and reproduction in any medium, provided the original work is properly cited. 

References

- [1] Sutton JP 3rd, Ho SY, Anderson RH. The forgotten interleaflet triangles: A review of the surgical anatomy of the aortic valve. *The Annals of Thoracic Surgery*. 1995;**59**(2):419-427
- [2] Anderson RH et al. The myth of the aortic annulus: The anatomy of the subaortic outflow tract. *The Annals of Thoracic Surgery*. 1991;**52**(3):640-646
- [3] Brewer RJ et al. The dynamic aortic root. Its role in aortic valve function. *The Journal of Thoracic and Cardiovascular Surgery*. 1976;**72**(3):413-417
- [4] David TE. An anatomic and physiologic approach to acquired heart disease. 8th Annual Meeting of the European Cardio-thoracic Association, The Hague, Netherlands, September 25-28, 1994. *European Journal of Cardio-Thoracic Surgery*. 1995;**9**(4):175-180
- [5] Underwood MJ et al. The aortic root: Structure, function, and surgical reconstruction. *Heart*. 2000;**83**(4):376-380
- [6] Ho SY. Structure and anatomy of the aortic root. *European Journal of Echocardiography*. 2009;**10**(1):i3-i10
- [7] Charitos EI, Sievers HH. Anatomy of the aortic root: Implications for valve-sparing surgery. *Annals Cardiothorac Surgery*. 2013;**2**(1):53-56
- [8] Thubrikar MJ et al. Stress sharing between the sinus and leaflets of canine aortic valve. *The Annals of Thoracic Surgery*. 1986;**42**(4):434-440
- [9] Feindel CM, David TE. Aortic valve sparing operations: Basic concepts. *International Journal of Cardiology*. 2004;**97**(Suppl 1):61-66
- [10] Becker DG et al. Clinical study of alar anatomy and surgery of the alar base. *Archives of Otolaryngology-Head and Neck Surgery*. 1997;**123**(8):789-795
- [11] Cannata A, Russo CF, Vitali E. Bicuspid aortic valve: About natural history of ascending aorta aneurysms. *The Annals of Thoracic Surgery*. 2008;**85**(1):362-363
- [12] David TE, Maganti M, Armstrong S. Aortic root aneurysm: Principles of repair and long-term follow-up. *The Journal of Thoracic and Cardiovascular Surgery*. 2010;**140**(6 Suppl):S14-S19; discussion S45-51
- [13] Augoustides JG, Plappert T, Bavaria JE. Aortic decision-making in the Loeys-Dietz syndrome: Aortic root aneurysm and a normal-caliber ascending aorta and aortic arch. *The Journal of Thoracic and Cardiovascular Surgery*. 2009;**138**(2):502-503
- [14] Coselli JS. It's time to get to the root of things. *The Journal of Thoracic and Cardiovascular Surgery*. 2016;**151**(2):291-293
- [15] Song HK et al. Long-term implications of emergency versus elective proximal aortic surgery in patients with Marfan syndrome in the genetically triggered thoracic aortic aneurysms and cardiovascular conditions consortium registry. *The Journal of Thoracic and Cardiovascular Surgery*. 2012;**143**(2):282-286
- [16] Loeys BL et al. A syndrome of altered cardiovascular, craniofacial, neurocognitive and skeletal development caused by mutations in TGFBR1 or TGFBR2. *Nature Genetics*. 2005;**37**(3):275-281

- [17] Atzinger CL et al. Cross-sectional and longitudinal assessment of aortic root dilation and valvular anomalies in hypermobile and classic Ehlers-Danlos syndrome. *The Journal of Pediatrics*. 2011;**158**(5):826-830. e1
- [18] Borger MA et al. The American association for thoracic surgery consensus guidelines on bicuspid aortic valve-related aortopathy: Full online-only version. *The Journal of Thoracic and Cardiovascular Surgery*. 2018;**156**(2):e41-e74
- [19] Siu SC, Silversides CK. Bicuspid aortic valve disease. *Journal of the American College of Cardiology*. 2010;**55**(25):2789-2800
- [20] Bonderman D et al. Mechanisms underlying aortic dilatation in congenital aortic valve malformation. *Circulation*. 1999;**99**(16):2138-2143
- [21] Nistri S et al. Aortic elasticity and size in bicuspid aortic valve syndrome. *European Heart Journal*. 2008;**29**(4):472-479
- [22] Ostberg G. An arteritis with special reference to polymyalgia arteritica. *Acta Pathologica et Microbiologica Scandinavica. Supplement*. 1973;**237**(Suppl 237):1-59
- [23] Kerr GS et al. Takayasu arteritis. *Annals of Internal Medicine*. 1994;**120**(11):919-929
- [24] Robinson WP 3rd et al. Fulminant development of mega-aorta due to Takayasu's arteritis: Case report and review of the literature. *Vascular*. 2005;**13**(3):178-183
- [25] Song MH et al. Aortic root aneurysm in Takayasu arteritis syndrome: Exploration in active phase and repair in inactive phase. *The Journal of Thoracic and Cardiovascular Surgery*. 2008;**136**(4):1084-1085
- [26] Yuan SM, Jing H. Cystic medial necrosis: Pathological findings and clinical implications. *Revista Brasileira de Cirurgia Cardiovascular*. 2011;**26**(1):107-115
- [27] Borger MA et al. The American Association for Thoracic Surgery consensus guidelines on bicuspid aortic valve-related aortopathy: Executive summary. *The Journal of Thoracic and Cardiovascular Surgery*. 2018;**156**(2):473-480
- [28] Gott VL et al. Replacement of the aortic root in patients with Marfan's syndrome. *The New England Journal of Medicine*. 1999;**340**(17):1307-1313
- [29] Joint Task Force on the Management of Valvular Heart Disease of the European Society of Cardiology (ESC) et al. Guidelines on the management of valvular heart disease (version 2012). *European Heart Journal*. 2012;**33**(19):2451-2496
- [30] Altarabsheh SE et al. Unruptured sinus of valsalva aneurysm involving all three sinuses. *The Annals of Thoracic Surgery*. 2011;**91**(2):e26-e27
- [31] Yan F et al. Surgery for sinus of valsalva aneurysm: 27-year experience with 100 patients. *Asian Cardiovascular & Thoracic Annals*. 2008;**16**(5):361-365
- [32] Bhat PS et al. Aneurysm of all 3 sinuses of valsalva causing coronary insufficiency. *Asian Cardiovascular & Thoracic Annals*. 2009;**17**(6):637-639
- [33] Lijoi A et al. Unruptured aneurysm of the left sinus of valsalva causing coronary insufficiency: Case report and review of the literature. *Texas Heart Institute Journal*. 2002;**29**(1):40-44
- [34] Atkins MD Jr, Black JH 3rd, Cambria RP. Aortic dissection:

- Perspectives in the era of stent-graft repair. *Journal of Vascular Surgery*. 2006;**43**(Suppl A):30A-43A
- [35] Debaeky ME et al. Surgical management of dissecting aneurysms of the aorta. *The Journal of Thoracic and Cardiovascular Surgery*. 1965;**49**:130-149
- [36] Erbel R et al. Diagnosis and management of aortic dissection. *European Heart Journal*. 2001;**22**(18):1642-1681
- [37] Daily PO et al. Management of acute aortic dissections. *The Annals of Thoracic Surgery*. 1970;**10**(3):237-247
- [38] Gawinecka J, Schonrath F, von Eckardstein A. Acute aortic dissection: Pathogenesis, risk factors and diagnosis. *Swiss Medical Weekly*. 2017;**147**:w14489
- [39] Bentall H, De Bono A. A technique for complete replacement of the ascending aorta. *Thorax*. 1968;**23**(4):338-339
- [40] Kirsch EW et al. Aortic root replacement after previous surgical intervention on the aortic valve, aortic root, or ascending aorta. *The Journal of Thoracic and Cardiovascular Surgery*. 2006;**131**(3):601-608
- [41] Loisanche D. Simplification of the Bentall procedure with surgical and biological innovations. *European Journal of Cardio-Thoracic Surgery*. 1994;**8**(11):613-615
- [42] Mookhoek A et al. Bentall procedure: A systematic review and meta-analysis. *The Annals of Thoracic Surgery*. 2016;**101**(5):1684-1689
- [43] Gaudino M et al. Contemporary outcomes of surgery for aortic root aneurysms: A propensity-matched comparison of valve-sparing and composite valve graft replacement. *The Journal of Thoracic and Cardiovascular Surgery*. 2015;**150**(5):1120-1129.e1
- [44] Sultan I et al. Aortic root replacement with cryopreserved homograft for infective endocarditis in the modern north American opioid epidemic. *The Journal of Thoracic and Cardiovascular Surgery*. 2019;**157**(1):45-50
- [45] Solari S et al. Over 20 years experience with aortic homograft in aortic valve replacement during acute infective endocarditis. *European Journal of Cardio-Thoracic Surgery*. 2016;**50**(6):1158-1164
- [46] Kunadian B et al. Meta-analysis of valve hemodynamics and left ventricular mass regression for stentless versus stented aortic valves. *The Annals of Thoracic Surgery*. 2007;**84**(1):73-78
- [47] Jassar AS et al. Graft selection for aortic root replacement in complex active endocarditis: Does it matter? *The Annals of Thoracic Surgery*. 2012;**93**(2):480-487
- [48] Northrup WF 3rd, Kshetry VR. Implantation technique of aortic homograft root: Emphasis on matching the host root to the graft. *The Annals of Thoracic Surgery*. 1998;**66**(1):280-284
- [49] Tavakoli R et al. Full-root aortic valve replacement with stentless xenograft achieves superior regression of left ventricular hypertrophy compared to pericardial stented aortic valves. *Journal of Cardiothoracic Surgery*. 2015;**10**:15
- [50] Kunihara T et al. Root replacement using stentless valves in the small aortic root: A propensity score analysis. *The Annals of Thoracic Surgery*. 2006;**82**(4):1379-1384
- [51] Grande KJ et al. Porcine aortic leaflet arrangement may contribute

to clinical xenograft failure. *ASAIO Journal*. 1993;**39**(4):918-922

[52] LeMaire SA et al. Aortic root replacement with stentless porcine xenografts: Early and late outcomes in 132 patients. *The Annals of Thoracic Surgery*. 2009;**87**(2):503-512; discussion 512-3

[53] Kon ND et al. Aortic root replacement with the freestyle stentless porcine aortic root bioprosthesis. *The Annals of Thoracic Surgery*. 1999;**67**(6):1609-1615; discussion 1615-6

[54] Ouzounian M et al. Valve-sparing root replacement compared with composite valve graft procedures in patients with aortic root dilation. *Journal of the American College of Cardiology*. 2016;**68**(17):1838-1847

[55] David TE et al. Outcomes of aortic valve-sparing operations in Marfan syndrome. *Journal of the American College of Cardiology*. 2015;**66**(13):1445-1453

[56] Sarsam MA, Yacoub M. Remodeling of the aortic valve anulus. *The Journal of Thoracic and Cardiovascular Surgery*. 1993;**105**(3):435-438