

Chapter

Colorectal Liver Metastases

*Julio Wiederkehr, Barbara Wiederkehr
and Henrique Wiederkehr*

Abstract

The adenocarcinoma of the colon and rectum (CRC) affects more than 1.3 million patients each year, being the third most common malignancy in the world. Approximately, 30–50% of these patients will present with liver metastasis at the time of diagnosis or will develop metastasis later. The incidence of metastatic CRC (mCRC) is approximately 4.3% at 1 year, 8.7% at 2 years, 12% at 3 years, and 16.5% at 5 years after resection. Recently, the clinical outcome for patients with mCRC has improved, with a median overall survival (OS) for patients with mCRC is approximately 30 months, more than twice of that observed 20 years ago. The treatment approach for patients with colorectal liver metastases should be focused toward complete resection whenever possible, with both oncological and technical criteria being considered. Considering the fact that nearly 80% of patients with mCRC are not candidates for resection at diagnosis, initial treatment options include chemotherapy and locoregional therapies. Associating liver partition and portal vein ligation for staged hepatectomy (ALPPS) has emerged as modification on classic two-staged hepatectomy (TSH) with portal vein embolization. In experienced hepatobiliary centers and in well-selected patients, ALPPS can be performed with low morbidity and minimal mortality, resulting in good intermediate-term survival and excellent quality of life. Multidisciplinary tumor boards should critically scrutinize the best treatment options.

Keywords: colorectal cancer, liver, liver cancer, liver metastasis

1. Introduction

The adenocarcinoma of the colon and rectum (CRC) affect more than 1.3 million patients each year, being the third most common malignancy in the world [1]. Approximately, 30–50% of these patients will present with liver metastasis at the time of diagnosis or will develop metastasis later [2, 3].

Due to the fact that venous drainage of the intestinal tract is via the portal system, the first site of hematogenous spreading is usually the liver. The most common site of metastatic CRC is the liver, occurring in 80% of cases, representing nearly half of all patients with CRC. It is also the single site of metastasis in 20–50% of the cases [2]. The majority of metastatic CRC liver disease will be potentially resectable at the time of diagnosis, approximately 75–80% of cases [3]. Recurrence after resection of the primary lesion depends on the stage. The overall recurrence rate ranges from 9% in stage 1–56% in stage 3 CRC tumors [3].

A majority of CRC metastases (mCRC) occurs within the first 3 years. The incidence of mCRC is approximately 4.3% at 1 year, 8.7% at 2 years, 12% at

3 years, and 16.5% at 5 years after resection [2]. The frequency of metachronous CRC metastases is highly variable in the literature, arising from database differences and diversity of definitions. Metachronous CRC metastases are restricted to the liver in 44% of patients with distant recurrence following potentially curative resection of the primary lesion. In prospective and retrospective studies of referral centers, this rate reaches 35% [4]. In prospective observational studies and population studies, this frequency is lower, ranging from 5.7 to 16.3% [5]. In population studies, the frequency of synchronous liver metastases from CRC varies from 14.5 to 24% [2]. Patients presenting with stage 4 disease at the time of the diagnosis will have liver-confined metastases (synchronous metastases) in 77% of the cases [6].

Recently, the clinical outcome for patients with mCRC has improved. Nowadays, the median overall survival (OS) for patients with mCRC is approximately 30 months, more than twice of that observed 20 years ago [7]. It is not clear which improvements and/or strategic changes in the treatment and management of patients with mCRC in recent years have been responsible for the improved treatment outcomes for these patients. Some changes that might have contributed for this gain in OS are (i) changes in the clinical presentation of patients, before the commencement of treatment, due to closer follow-up after resection of the primary tumor and earlier detection of metastatic disease; (ii) improvements in the efficacy of systemic therapies in terms of regimens used, sequence of administration, number of lines of therapy administered, and biomarker-based patient selection; (iii) an increase in the number of patients being treated with a view to facilitating resection of their metastases, offering an increased number of patients the chance of cure and/or durable relapse-free survival and, more recently, the utilization of other ablative therapy techniques with the aim of achieving the same outcome; and (iv) implementation of “continuum of care” treatment strategies coupled with the early integration of optimal supportive care measures [7].

The best treatment strategies for patients with mCRC are evolving rapidly. Superior clinical outcomes are reached when the treatment approaches for individual patients are discussed within a multidisciplinary team (MDT) of experts, meeting regularly as a tumor board to review mCRC cases [8]. The responsibility of the MDT is to define the initial diagnostic workup and then the treatment focus, based on the best diagnostic and therapeutic decision-making available. Initially, the MDT member should critically define whether or not a patient has clearly resectable or initially unresectable metastatic disease. Contrariwise, for patients whose disease is believed “never to be resectable,” the discussion may be left to the treating medical oncologist (after discussion with the MDT) and patient as to the pros and cons of various approaches and sequences based on the perceived aims (e.g., duration of disease control versus quality of life and toxicity profiles, etc.) [7].

2. Imaging

The preferred method for the diagnosis of extrahepatic disease is computed tomography (CT) [9–11]. It is the method of choice for staging and follow-up of patients with colorectal cancer, as imaging methods are widespread in our environment, familiar to oncologists, radiologists, and surgeons, with good cost/benefit. Therefore, the use of CT is recommended as the initial method in the diagnosis of extrahepatic metastases.

Magnetic resonance imaging (MRI) is the most accurate imaging technique for the detection and characterization of focal liver lesions. However, costs are

higher and it has restricted availability. Other limitations include magnetic field exposure and gadolinium use restrictions in patients with renal insufficiency. Retrospective and meta-analyses have shown that MRI has a superior sensitivity to TC both in analysis per patient (81.1–88.2% vs. 74.8–83.6%) and in analysis per lesion (80.3–86.3% vs. 74.4–82.6%); such superiority is related to higher detection of lesions smaller than 1 cm [12, 13]. MRI with hepatobiliary contrast has demonstrated to have greater accuracy than FDG-PET/CT in detection of small liver metastases (92 vs. 60%) [14]. In a multicenter randomized prospective study, the performance of MRI with hepatobiliary contrast was superior to CT with iodinated contrast and MRI with extracellular gadolinium as first-line method in the initial evaluation of liver mCRC [14].

PET/CT have shown to be of great value in the evaluation of extrahepatic sites of metastases undetected by other methods in patients eligible for surgical resection of liver mCRC, altering the therapeutic plan [15, 16].

Since cross-sectional imaging modalities have improved sensitivity of the diagnosis of mCRC, diagnostic laparoscopy is no longer standard for evaluating patients with mCRC. Instead, it is only used in patients with a suspicion of small-volume carcinomatosis on radiographic imaging studies or who are at particularly high risk for harboring unresectable diseases [17].

3. Prognostic determinants

The pathologic stage at presentation is the most important indicator of outcome after treatment in general, followed by the presence of extramural tumor deposits, lymphovascular and perineural invasion, histologic grade of differentiation, the preoperative level of serum carcinoembryonic antigen (CEA), microsatellite instability (MSI), and RAS and BRAF mutations [18, 19].

Microsatellite instability (MSI) status or mismatch repair deficiency (MMR-D) has been the biomarker for adjuvant 5-FU monotherapy and immune checkpoint inhibitor. Hematogenous and lymphogenous metastasis-dominant CRC with high-frequency MSI (MSI-H) are reported to have poor prognosis. However, the validity as the prognostic factor of MMR is still to be confirmed, and it should thus be used cautiously [20, 21].

On the other hand, it is also known that RAS and BRAF mutations are of prognostic and predictive value in mCRC [21]. The pathogenesis of CRC involves the accumulation of genetic and epigenetic modifications within pathways that regulate proliferation, apoptosis, and angiogenesis.

KRAS mutations involving either codon 12 or 13 can be identified in 12–75% of tumors, and they have been individually correlated with a worse prognosis in most studies [22]. BRAF V600E mutations are present in 8–10% of patients, are consistently associated with poor prognosis, and result in possible patient ineligibility for resection of mCRC [23]. Recently, a small single-center cohort study showed that 21 of 52 patients with BRAF V600E mutant who underwent metastasectomy had longer OS (29.1 vs. 22.7 months) and progression-free survival (13.6 vs. 6.2 months) than the non-metastasectomy cohort. The authors concluded that multimodality therapy incorporating metastasectomy for BRAF V600E metastatic CRC should be considered and might be associated with improved OS in selected patients [24]. Meanwhile, BRAF V600E can be a biomarker for selecting the appropriate chemotherapy regimen [21].

Another feature that also appears to affect the prognosis of patients who develop liver metastases is the embryonic origin of the primary colon cancer. In an analysis

of 727 patients who were submitted to chemotherapy followed by resection, mCRC from midgut origin (right colon tumors) was associated with worse pathologic response to chemotherapy and worse survival after resection than mCRC from hindgut origin (left/sigmoid colon tumors) [25]. This effect was independent of the RAS mutation status. Primary tumor from right-sided colon might be more prone to recur. Therefore, palliative resection might not be done since these patients showed no benefit from resection [26].

4. Patient selection

The treatment approach for patients with colorectal liver metastases should be focused toward complete resection whenever possible, with both “oncological” (prognostic) and “technical” (surgical) criteria being considered when evaluating patients for surgery [27, 28].

The “technical” definitions of resectable mCRC have evolved over time, with the current consensus proposing that disease should be considered technically resectable as long as complete macroscopic resection is feasible while maintaining at least a 30% future liver remnant (FLR) or a remnant liver to body weight ratio >0.5 (e.g., >350 g of the liver per 70 kg patient) [29]. Nevertheless, not all patients with technically resectable liver-limited metastases benefit from surgery; approximately half of the patients submitted to resection of mCRC will present widespread systemic disease within 3 years of the resection [30].

Prognostic information that predicts a longer disease-free survival (DFS) or a higher probability of cure is provided by the “oncological” criteria. Strong parameters for the oncological criteria are the number of lesions; the presence, or suspicion, of extrahepatic disease; and numerous other criteria used in retrospective studies. Fong et al. proposed a score based on the following parameters: nodal status of primary tumor, disease-free interval from the primary to discovery of the liver metastases of <12 months, number of tumors >1 , preoperative CEA level >200 ng/ml, and size of the largest tumor >5 cm (**Table 1**) [31]. Thus, for some patients, neoadjuvant chemotherapy may be a better option than upfront surgery.

In practice, the patients can be categorized, based upon the criteria above, whether or not they are eligible for resection, as proposed by Adam et al. (**Table 2**) [28]. The disease can be categorized as resectable, not optimally resectable, or unresectable. The not optimally resectable disease is defined as difficult to resect for technical reasons (proximity to hepatic vein and portal vein branches) or technically

Survival (%)						
Score	1 year	2 year	3 year	4 year	5 year	Median (mo)
0	93	79	72	60	60	74
1	91	76	66	54	44	51
2	89	73	60	51	40	47
3	86	67	42	25	20	33
4	70	45	38	29	25	20
5	71	45	27	14	14	22

Each risk factor is one point: node-positive primary, disease-free interval <12 months, >1 tumor, size >5 cm, CEA >200 ng/ml.

Table 1. Clinical risk score for tumor recurrence proposed by Fong et al. [31].

Category	Contraindication
Technical	
1. Absolute	Impossibility of R0 resection and functional residual liver volume preserved ($\geq 25\text{--}30\%$ liver remnant) Presence of unresectable extrahepatic disease
2. Relative	R0 resection possible only with complex procedure (portal vein embolization, two-stage hepatectomy, hepatectomy combined with ablation ^a) R1 resection
Oncological	
1.	Concomitant extrahepatic disease (unresectable)
2.	Number of lesion ≥ 5
3.	Tumor progression
<i>Any patient should be categorized as A1 or A2/B1, B2, or B3. This classification may help to clearly define the type of unresectable patients included in all clinical trials.</i>	
<i>^aIncludes all methods, including radiofrequency ablation.</i>	

Table 2.
 Contraindications to hepatic resection in patients with CRC liver metastases (adapted from Adam et al. [28]).

possible to resect, but oncologically problematic (number of liver metastases greater than 4, maximum diameter 5 cm or more, synchronous liver metastases, primary lymph node metastasis positive, and high levels of tumor markers) [32].

5. Treatment options

Considering the fact that nearly 80% of patients with mCRC are not candidates for resection at diagnosis [33], initial treatment options include chemotherapy and several locoregional therapies. In these cases, chemotherapy in combination with molecular targeted drugs is recommended, followed by curative resection if a response is achieved.

5.1 Chemotherapy

In patients with “favorable oncological” criteria (i.e., $>50\%$ likelihood of cure based on various factors including long-term metachronous disease) and “favorable surgical” criteria (no massive disease infiltration), both upfront surgery and perioperative chemotherapy are options. The EPOC study with perioperative chemotherapy has shown no clear predilection for one option over the other, since the 5-year OS rate reported for the perioperative chemotherapy group was 51% (95% CI 45–58) versus 48% (95% CI 40–55) in the surgery-only group [34].

However, in cases with disease that is not technically challenging to resect but where the prognostic situation is unclear, perioperative chemotherapy should be the preferable treatment strategy. These patients should undergo perioperative chemotherapy, 3 months before surgery and 3 months after surgery. The preferred treatment in this situation should be FOLFOX (or alternatively capecitabine with oxaliplatin—CAPOX) as reported for the EPOC trial [34]. EGFR-targeting monoclonal antibodies (cetuximab and panitumumab) are not to be used in this setting, based on the data from the New EPOC trial [35]. No data with bevacizumab are available for this specific patient group; thus, bevacizumab is not indicated [7]. Hence, especially in the case of synchronous metastatic disease, neoadjuvant chemotherapy preceding liver resection is often undertaken as a way of assessing the natural history of metastatic disease prior to resection.

The use of conversion chemotherapy in clinical practice is based on the fact that initially unresectable tumors that are judged resectable after responding to chemotherapy and that undergo surgery display better long-term result than those treated with chemotherapy only [7, 36]. It is reported that up to 33% of patients with “initially unresectable” hepatic metastases have a sufficient objective response to conversion therapy to permit a subsequent complete (R0) resection [17, 37]. However, it has also been reported that the probability of downstaging a truly unresectable disease to the point of resectability is only up to 15 [38].

Another important aspect that has to be studied when considering conversion therapy is that longer durations of chemotherapy increase the possibility of liver toxicity and postoperative complications. Evaluation of the response through imaging tests should be made each 6–8-week gap, and the resection should be made as soon as the metastases are considered undoubtedly resectable [38].

In this scenario the response of the disease to the systemic treatment is also very important. If a growth of the disease is perceived while on chemotherapy or even the development of extrahepatic disease appears in this period, it may indicate that the tumor is biologically aggressive and it would not benefit from resection [17].

After complete resection of mCRC, the best postoperative strategy is debatable as well. Due to the lack of published randomized trials to conduct clinical practice, some suggest completion of a 6-month course of systemic chemotherapy (including courses administered as neoadjuvant therapy), as also suggested by updated guidelines from the National Comprehensive Cancer Network (NCCN) [38].

The strong tumor responses for mCRC with the new agents in chemotherapy can even reach a complete response status. The tumors with less than 2 cm in diameter and more than 1 cm deep in the hepatic parenchyma are the ones with greater risk of vanishing [39]. Nevertheless, the resection is still needed considering that true pathologic complete response or clinical long-term response is, after chemotherapy alone, present in only 17% of the patients [40]. Therefore, those at risk of disappearing with the neoadjuvant treatment should be marked with a fiducial marker such as a coil before chemotherapy [41].

5.2 Radiofrequency ablation therapy

Though resection is considered the gold standard care of mCRC, sometimes there are contraindications due to anatomical reasons. Additionally, there may be comorbidities or liver dysfunction associated which grades the patient as ineligible for major surgery. In these cases, radiofrequency ablation (RFA) represents a great alternative [21].

Considered as a parenchymal-sparing approach, the ablation therapy has been used for managing tumors that can vary from small to unresectable. It can be used as part of a combined ablation/resection tactic in cases of borderline resectable tumors or cases with risk of insufficient future liver remnant [17]. In a multicenter study of 288 patients who underwent combined intraoperative ablation and resection of mCRC, the 5-year overall survival was 37%, and local recurrence-free survival from ablated lesions was 78%. Postoperative mortality was 1%, and the overall complication rate was 35% [42].

5.3 ALPPS

Associating liver partition and portal vein ligation for staged hepatectomy (ALPPS) has emerged as modification on classic two-staged hepatectomy (TSH) with portal vein embolization. This new concept of liver resection, ALPPS, was first described in 2011 [43]. The main advantage of ALPPS is its ability to generate

extensive and accelerated hypertrophy of the future liver remnant (FLR), achieving adequate volume for completion of the second stage of the ALPPS in as short as 1 week. This method for hepatic resection has also been described to treat various hepatic tumors in children [44]. ALPPS brings solution to a major flaw of classic TSH, where a considerable percentage ($\approx 30\%$) of patients are unable to complete the second stage due to insufficient future liver remnant (FLR) growth and short-interval progression of the disease [45].

In the initial study, 68% of the patients experienced complications, and the surgical mortality rate was 12% [43]. Since the first description of ALPPS, there has been a great deal of interest in this treatment. However, criticism of the approach has been raised mainly regarding surgical morbidity and mortality [46].

Recently, Wanis et al. [47] reported a cohort of 58 patients who underwent ALPPS for colorectal liver metastases. They observed no perioperative mortalities and a rate of severe complications of 21%. The 3-year post-ALPPS overall survival was 50%, while the disease-free survival was 13%. The most common site of first recurrence was the liver alone (38%). Patient-reported quality of life after ALPPS was similar to reference values for general population

Additionally, the Scandinavian Multicenter Randomized Controlled Trial (LIGRO Trial) comparing ALPPS with TSH [48], showed a much higher resection rate for ALPPS, 92% (44/48), than TSH, 57% (28/49) ($P < 0.0001$). Considering other parameters, such as complications [43% (19/44) vs. 43% (12/28)] and 90-day mortality [8.3% (4/48) vs. 6.1% (3/49)] or RO RRs [77% (34/44) vs. 57% (16/28)], no differences were observed.

In experienced hepatobiliary centers and in well-selected patients, ALPPS can be performed with low perioperative morbidity and minimal to no mortality, resulting in good intermediate-term survival and excellent quality of life [47].

Although many centers have been using ALPPS associated with right hepatectomy with good results to treat liver mCRC, indications for ALPPS should continue to be scrutinized critically by multidisciplinary tumor boards based on accepted criteria of remnant liver volume, number of prior cycles of chemotherapy, and histologic criteria of the presence or absence of underlying parenchymal hepatic damage based on at the least a fresh frozen section during stage 1, when considering ALPPS [49].

The technique consists of a bilateral subcostal laparotomy using an adult subcostal retractor. A thorough inspection of the abdominal cavity is carried out in order to detect any previously missed metastases. A cholecystectomy and hepatic hilum dissection are then performed. The right and left hepatic arteries, as well as the arteries for segment 4, were dissected and identified. The common bile duct was dissected. The left or right portal vein is ligated. When the tumor is located on the right hemi-liver with involvement of segment 4, the portal branch for segment 4 is ligated and divided. Full mobilization of the liver is obtained by sectioning the falciform, coronary, and right and left triangular ligaments of the liver. The right or left hepatic vein of the liver to be resected is dissected and encircled with a vessel loop, as seen in **Figure 1**. An intraoperative ultrasound is performed to verify a tumor-free parenchymal transection line.

The liver parenchyma is transected using combined ultrasonic energy (Ultracision®), monopolar and bipolar electrocautery, and ligation of the blood vessels and bile ducts. Biologic fibrin sealant can be used in both surfaces of the spitted liver. Closed drainage is placed in the liver hilum. We do not use any plastic film, mesh, or plastic bag to separate both surfaces of the liver. Metastases located in the future remnant liver (FRL) can be treated either by local resection or radiofrequency tumor ablation (RFA).

During the second operation, the hepatic artery and the bile duct of the diseased liver are ligated and transected. A clamp is applied at the right or left hepatic vein,

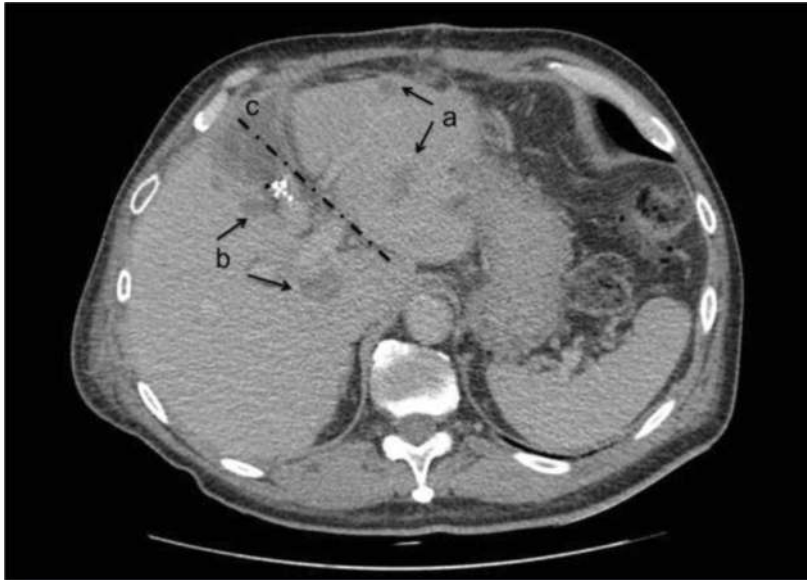

Figure 1. Postoperative CT image of a patient who underwent portal vein ligation and staged hepatectomy: (a) treated liver metastases of the FRL, (b) metastases on liver to be resected, and (c) line of liver bipartition.

and the vein is then transected. A 4–0 Prolene[®] running suture is applied to the stump of the hepatic vein. Liver segment 1 is usually preserved [46].

6. Timing for surgical approach

When facing a situation of synchronous disease, with both primary tumor and hepatic metastases, the timing for surgical approach of the hepatic lesions is still a topic of discussion.

The lesions can be accessed simultaneously in one procedure, or they can be treated with a staged resection. In the staged manner, there is the classic approach, which means accessing the primary tumor first; and there is the reverse approach, also known as liver-first approach. No difference has been shown by various studies, regardless of which method is used [50].

Therefore, the decision should be established on a case-by-case basis, considering the symptoms presented by the patient, location, size, and possible complications of each one such as bowel perforation, risk of liver failure, whether the patient underwent chemotherapy or not, performance status, and the surgeon expertise [17, 51].

7. Surgical resection

The surgical approach of the mCRC in the liver can be performed through an anatomic resection or a nonanatomic/parenchymal-sparing resection (PSR). Since the type of resection has not been associated with significant differences in rates of positive margin, recurrence, or survival [50], and considering that the PSR preserves greater hepatic reserve, recent studies are leaning toward the nonanatomic method, particularly when chemotherapy-induced liver injury is a concern [17].

Keeping in mind that recurrences after initial resection of mCRC can occur in up to 57% of cases and the most common site of recurrences is the liver [52] and considering that repeat liver resection in a second recurrence, with satisfactory

morbidity and perioperative mortality, has been associated with a 5-year survival up to 43% [38], the PSR becomes an even more attractive option.

Considering the width of the resection margin, a 2017 meta-analysis reported that margins greater than 10 mm were related with superior 5-year OS [53]. Still, numerous retrospective studies revealed that less than 10 mm but negative margin is not related with poorer survival [54]. In a multicenter study of 551 patients, surgical margins were classified as positive or negative with 1–4, 5–9, and >10 mm of tumor-free parenchyma. The positive margins were associated with a greater risk of recurrence, and the width of negative margins did not affect survival, recurrence, or site of recurrences [54].

There is one situation where anatomic resection and/or a wider surgical margin (>10 mm) may be indicated which is before a RAS-mutated mCRC as it constitutes a more aggressive tumor biology group and has been associated with more positive margins and worse survival after surgery [55]. Others reported that even a wider resection margin might not be sufficient to overcome the aggressive tumor biology associated with a RAS mutation. In a study of 411 patients who underwent resection for mCRC at Johns Hopkins University, a 1–4-mm margin was associated with improved survival compared with a positive margin (<1 mm or R1) for wild-type KRAS tumors, with which a wider resection margin did not further improve survival. In KRAS-mutated tumors, however, negative margin status, which included a 1-cm margin, did not improve survival [56].

8. Follow-up after resection

According to the consensus-based guidelines from the National Comprehensive Cancer Network (NCCN), the recommendation is carcinoembryonic antigen (CEA) testing every 3–6 months for 2 years followed by every 6 months for 3 years; computed tomography (CT) of the chest/abdomen and pelvis every 3–6 months for 2 years and then every 6–12 months up to a total of 5 years; colonoscopy in 1 year; if negative, repeat in 3 years and then every 5 years; and if advanced adenoma is found, repeat in 1 year [38].

An important point is that posttreatment follow-up should only be performed for those patients considered candidate for a second potentially curative surgical procedure [38].

9. Repeat resection for colorectal liver metastases

Re-resection for recurrence of mCRC is a safe and viable option in properly selected patients. In order to prevent post-hepatectomy liver failure, sufficient future liver reserve is paramount, as well as no evidence of extrahepatic disease and good performance status [57–59].

Although randomized trials have not been conducted to prove benefit, several reported series have demonstrated perioperative mortality rates lower than 5%, and overall survival rates ranged from 20 to 43% at 2–5 years [57–59].

Patients with a relapse-free interval of longer than 1 year appear to have a more favorable outcome from re-resection. Factors associated with a poor outcome include synchronous resection for the first liver metastases and the presence of multiple lesions at second hepatectomy [60, 61].

Interestingly, recurrences at the margin are uncommon [62, 63]. Some studies have reported 5-year overall survival rates after re-resection of 33–73% with no perioperative mortality [64, 65].

10. Conclusion

It is known that the majority of metastatic CRC liver disease will be potentially resectable at the time of diagnosis. Considering that hepatic resection is the only curative option for these patients, the parameters of resectability have expanded through the years due to a wider knowledge of the disease, improving diagnostic techniques, new drugs, and technical surgical advances. It is safe to say that the treatment strategies have advanced rapidly enough to change dramatically the natural history of the mCRC.

ALPPS has been recently introduced as an option to the treatment of mCRC. It has been shown to increase drastically the resection rates, with complications rates not different from standard two-staged hepatectomy.


Several treatment options are available to treat patients with mCRC. It is important to have in mind that the treatment approach must be established for each case. Not only the patient and anatomic factors are important, but also the tumor factors must be considered. Best results are obtained when the treatment approaches for individual patients are discussed within a multidisciplinary team (MDT) of experts, meeting regularly as a tumor board to review mCRC cases.

Author details

Julio Wiederkehr*, Barbara Wiederkehr and Henrique Wiederkehr
Federal University of Parana, Curitiba, Brazil

*Address all correspondence to: julio.wieder@gmail.com

IntechOpen

© 2019 The Author(s). Licensee IntechOpen. This chapter is distributed under the terms of the Creative Commons Attribution License (<http://creativecommons.org/licenses/by/3.0>), which permits unrestricted use, distribution, and reproduction in any medium, provided the original work is properly cited. 

References

- [1] Ferlay J, Soerjomataram I, Dikshit R, Eser S, Mathers C, Rebelo M, et al. Cancer incidence and mortality worldwide: Sources, methods and major patterns in GLOBOCAN 2012. *International Journal of Cancer*. 2015;**136**(5):E359-E386
- [2] Coimbra FJF, Ribeiro HS, Marques MC, Herman P, Chojniak R, Kalil AN, et al. First brazilian consensus on multimodal treatment of colorectal liver metastases. Module 1: Pre-treatment evaluation. *ABCD Arquivos Brasileiros de Cirurgia Digestiva (São Paulo)*. 2015;**28**(4):222-230 Available from: http://www.scielo.br/scielo.php?script=sci_arttext&pid=S0102-67202015000400222&lng=en&nrm=iso&tlng=en
- [3] Siegel R, Ward E, Brawley O, Jemal A. Cancer statistics, 2011: The impact of eliminating socioeconomic and racial disparities on premature cancer deaths. *CA: S Cancer Journal for Clinicians*. 2011;**61**:212-236
- [4] Thomasset SC, Dennison AR, Metcalfe MS, Steward WP, Garcea G. Changing trends in the presentation of colorectal liver metastases in a single hepatobiliary tertiary referral centre over fourteen years. *European Journal of Surgical Oncology, Elsevier Ltd*. 2013;**39**(11):1243-1247 Available from: <http://dx.doi.org/10.1016/j.ejso.2013.08.021>
- [5] Manfredi S, Lepage C, Hatem C, Coatmeur O, Faivre J, Bouvier AM. Epidemiology and management of liver metastases from colorectal cancer. *Annals of Surgery*. 2006;**244**(2):254-259
- [6] Alberts SR. Update on the optimal management of patients with colorectal liver metastases. *Critical Reviews in Oncology/Hematology, Elsevier Ireland Ltd*. 2012;**84**(1):59-70. Available from: <http://dx.doi.org/10.1016/j.critrevonc.2012.02.007>
- [7] Van Cutsem E, Cervantes A, Adam R, Sobrero A, Van Krieken JH, Aderka D, et al. ESMO consensus guidelines for the management of patients with metastatic colorectal cancer. *Annals of Oncology*. 2016;**27**(8):1386-1422
- [8] Shah S, Arora S, Atkin G, Glynne-Jones R, Mathur P, Darzi A, et al. Decision-making in Colorectal Cancer Tumor Board meetings: Results of a prospective observational assessment. *Surgical Endoscopy*. 2014;**28**(10):2783-2788
- [9] Fowler KJ, Linehan DC, Menias CO. Colorectal liver metastases: State of the art imaging. *Annals of Surgical Oncology*. 2013;**20**(4):1185-1193
- [10] Kekelidze M, D'Errico L, Pansini M, Tyndall A, Hohmann J. Colorectal cancer: Current imaging methods and future perspectives for the diagnosis, staging and therapeutic response evaluation. *World Journal of Gastroenterology*. 2013;**19**(46):8502-8514
- [11] Tudyka V, Blomqvist L, Beets-Tan RGH, Boelens PG, Valentini V, Van De Velde CJ, et al. EURECCA consensus conference highlights about colon & rectal cancer multidisciplinary management: The radiology experts review. *European Journal of Surgical Oncology, Elsevier Ltd*. 2014;**40**(4):469-475. Available from: <http://dx.doi.org/10.1016/j.ejso.2013.10.029>
- [12] Shimada K, Isoda H, Hirokawa Y, Arizono S, Shibata T, Togashi K. Comparison of gadolinium-EOB-DTPA-enhanced and diffusion-weighted liver MRI for detection of small hepatic metastases. *European Radiology*. 2010;**20**(11):2690-2698

- [13] Koh D-M, Collins DJ, Wallace T, Chau I, Riddell AM. Combining diffusion-weighted MRI with Gd-EOB-DTPA-enhanced MRI improves the detection of colorectal liver metastases. *British Journal of Radiology*. 2012;**85**(1015):980-989. Available from: <http://www.birpublications.org/doi/10.1259/bjr/91771639>
- [14] Moulton CA, Gu CS, Law CH, Tandan VR, Hart R, Quan D, et al. Effect of PET before liver resection on surgical management for colorectal adenocarcinoma metastases. *Journal of the American Medical Association*. 2014;**311**(18):1863. Available from: <http://jama.jamanetwork.com/article.aspx?doi=10.1001/jama.2014.3740>
- [15] Chun YS, Vauthey J-N, Boonsirikamchai P, Maru DM, Kopetz S, Palavecino M, et al. Association of computed tomography morphologic criteria with pathologic response and survival in patients treated with bevacizumab for colorectal liver metastases. *Journal of the American Medical Association*. 2009;**302**(21):2338-2344. Available from: <http://www.pubmedcentral.nih.gov/articlerender.fcgi?artid=4139149&tool=pmcentrez&rendertype=abstract>
- [16] Figueiras RG, Goh V, Padhani AR, Naveira AB, Caamaño AG, Martin CV. The role of functional imaging in colorectal cancer. *American Journal of Roentgenology*. 2010;**195**(1):54-66
- [17] Hepatic Resection for Colorectal Cancer Liver Metastasis–UpToDate [Cited July 9]. 2018. Available from: [https://www.uptodate.com/contents/hepatic-resection-for-colorectal-cancer-liver-metastasis?search=cancer colorrectal LIVER&source=search_result&selectedTitle=3~150&usage_type=default&display_rank=3](https://www.uptodate.com/contents/hepatic-resection-for-colorectal-cancer-liver-metastasis?search=cancer%20colorrectal%20LIVER&source=search_result&selectedTitle=3~150&usage_type=default&display_rank=3)
- [18] Edge SB, Byrd DR, Compton CC, et al., editors. *AJCC (American Joint Committee on Cancer) Cancer Staging Manual*. 7th ed. New York: Springer; 2010. p. 133. no abstract available. [cited 2018 Jul 10]. Available from: <https://www.uptodate.com/contents/pathology-and-prognostic-determinants-of-colorectal-cancer/abstract/29>
- [19] Pathology and Prognostic Determinants of Colorectal Cancer–UpToDate [cited Jul 10]. 2018. Available from: [https://www.uptodate.com/contents/pathology-and-prognostic-determinants-of-colorectal-cancer?sectionName=RAS and BRAF&opicRef=115954&anchor=H1022797966&source=see_link#H1022797966](https://www.uptodate.com/contents/pathology-and-prognostic-determinants-of-colorectal-cancer?sectionName=RAS%20and%20BRAF&topicRef=115954&anchor=H1022797966&source=see_link#H1022797966)
- [20] Fujiyoshi K, Yamamoto G, Takenoya T, et al. Metastatic pattern of stage IV colorectal cancer with high-frequency microsatellite instability as a prognostic factor. *Anticancer Research*. 2017;**37**:239-247
- [21] Oki E, Ando K, Nakanishi R, Sugiyama M, Nakashima Y, Kubo N, et al. Recent advances in treatment for colorectal liver metastasis. *Annals of Gastroenterological Surgery*. 2018;**2**:167-175
- [22] Modest DP, Ricard I, Heinemann V, Hegewisch-Becker S, Schmiegeler W, Porschen R, et al. Outcome according to KRAS-, NRAS- and BRAF-mutation as well as KRAS mutation variants: Pooled analysis of five randomized trials in metastatic colorectal cancer by the AIO colorectal cancer study group. *Annals of Oncology: An Official Journal of the European Society for Medical Oncology*. 2016;**27**(9):1746-1753. Available from: <https://academic.oup.com/annonc/article-lookup/doi/10.1093/annonc/mdw261>
- [23] Passiglia F, Bronte G, Bazan V, Galvano A, Vincenzi BRA. Can KRAS and BRAF mutations limit the benefit of liver resection in metastatic colorectal cancer patients? A systematic review and meta-analysis. *Critical Reviews in Oncology/Hematology*. 2016;**99**:150-157

- [24] Johnson B, Jin Z, Truty MJ, et al. Impact of metastasectomy in the multimodality approach for BRAF V600E metastatic colorectal cancer: The Mayo Clinic experience. *The Oncologist*. 2018;**23**(1):128-134
- [25] Yamashita S, Brudvik KW, Kopetz SE, Maru D, Clarke CN, Passot G, et al. Embryonic origin of primary colon cancer predicts pathologic response and survival in patients undergoing resection for colon cancer liver metastases. *Annals of Surgery*, NIH Public Access. 2018;**267**(3):514-520. Available from: <http://www.ncbi.nlm.nih.gov/pubmed/28002060>
- [26] Zhang RX, Ma WJ, Gu YT, et al. Primary tumor location as a predictor of the benefit of palliative resection for colorectal cancer with unresectable metastasis. *World Journal of Surgical Oncology*. 2017;**15**(1):138
- [27] Aloia TA, Adam R, Azoulay D, et al. Outcome following hepatic resection of metastatic renal tumors: The Paul Brousse Hospital experience. Oxford: HPB; 2006;**8**(2):100-105
- [28] Adam R, De Gramont A, Figueras J, Guthrie A, Kokudo N, Kunstlinger F, et al. The oncosurgery approach to managing liver metastases from colorectal cancer: A multidisciplinary international consensus. *The Oncologist*. 2012;**17**(10):1225-1239
- [29] Clavien PA, Petrowsky H, DeOliveira ML, Graf R. Strategies for safer liver surgery and partial liver transplantation. *The New England Journal of Medicine*. 2007;**356**(15):1545-1559. Available from: <http://www.nejm.org/doi/abs/10.1056/NEJMra065156>
- [30] Kanas GP, Taylor A, Primrose JN, Langeberg WJ, Kelsh MA, Mowat FS, et al. Survival after liver resection in metastatic colorectal cancer: Review and meta-analysis of prognostic factors. *Clinical Epidemiology*. 2012;**4**(1):283-301
- [31] Fong Y, Fortner J, Sun RL, et al. Clinical score for predicting recurrence after hepatic resection for metastatic colorectal cancer: Analysis of 1001 consecutive cases. *Annals of Surgery*. 1999;**230**(3):309-321
- [32] Nordlinger B, Van Cutsem E, Gruenberger T, Glimelius B, Poston G, Rougie P, et al. Combination of surgery and chemotherapy and the role of targeted agents in the treatment of patients with colorectal liver metastases: Recommendations from an expert panel. *Annals of Oncology*. 2009;**20**(6):985-992
- [33] Garden OJ, Rees M, Poston GJ, Mirza D, Saunders M, Ledermann J, et al. Guidelines for resection of colorectal cancer liver metastases. *Gut*. 2006;**55**(Suppl 3):iii1-iii8. Available from: <http://gut.bmj.com/cgi/doi/10.1136/gut.2006.098053>
- [34] Nordlinger B, Sorbye H, Glimelius B, Poston GJ, Schlag PM, Rougier P, et al. Perioperative FOLFOX4 chemotherapy and surgery versus surgery alone for resectable liver metastases from colorectal cancer (EORTC 40983): Long-term results of a randomised, controlled, phase 3 trial. *The Lancet Oncology*. 2013;**14**(12):1208-1215
- [35] Primrose J, Falk S, Finch-Jones M, Valle J, O'Reilly D, Siriwardena A, et al. Systemic chemotherapy with or without cetuximab in patients with resectable colorectal liver metastasis: The New EPOC randomised controlled trial. *The Lancet Oncology*. 2014;**15**(6):601-611
- [36] Adam R, Bhangui P, Poston G, Mirza D, Nuzzo G, Barroso E, et al. Is perioperative chemotherapy useful for solitary, metachronous, colorectal liver metastases? *Annals of Surgery*. 2010;**252**(5):774-785
- [37] Barone C, Nuzzo G, Cassano A, Basso M, Schinzari G, Giuliante F, et al.

Final analysis of colorectal cancer patients treated with irinotecan and 5-fluorouracil plus folinic acid neoadjuvant chemotherapy for unresectable liver metastases. *British Journal of Cancer*. 2007;**97**(8):1035-1039. Available from: <http://www.nature.com/articles/6603988>

[38] Management of Potentially Resectable Colorectal Cancer Liver Metastases—UpToDate [cited Jul 11]. 2018. Available from: [https://www.uptodate.com/contents/management-of-potentially-resectable-colorectal-cancer-liver-metastases?search=cancer colorrectal LIVER&source=search_result&selectedTitle=1~150&usage_type=default&display_rank=1](https://www.uptodate.com/contents/management-of-potentially-resectable-colorectal-cancer-liver-metastases?search=cancer%20colorrectal%20LIVER&source=search_result&selectedTitle=1~150&usage_type=default&display_rank=1)

[39] Passot G, Odisio BC, Zorzi D, Mahvash A, Gupta S, Wallace MJ, et al. Eradication of missing liver metastases after fiducial placement. *Journal of Gastrointestinal Surgery*. 2016;**20**(6):1173-1178. Available from: <http://link.springer.com/10.1007/s11605-016-3079-1>

[40] Benoist S, Brouquet A, Penna C, Julié C, El Hajjam M, Chagnon S, et al. Complete response of colorectal liver metastases after chemotherapy: Does it mean cure? *Journal of Clinical Oncology*. 2006;**24**(24):3939-3945. Available from: <http://ascopubs.org/doi/10.1200/JCO.2006.05.8727>

[41] Zalinski S, Abdalla EK, Mahvash A, Vauthey JN. A marking technique for intraoperative localization of small liver metastases before systemic chemotherapy. *Annals of Surgical Oncology*. 2009;**16**(5):1208-1211. Available from: <http://www.springerlink.com/index/10.1245/s10434-009-0328-5>

[42] Evrard S, Poston G, Kissmeyer-Nielsen P, Diallo A, Desolneux G, Brouste V, et al. Combined ablation and resection (CARE) as an effective parenchymal sparing treatment for extensive colorectal liver metastases. In: Taketomi A, editor.

PLoS One. 2014;**9**(12):e114404. Available from: <http://dx.plos.org/10.1371/journal.pone.0114404>

[43] Schnitzbauer AA, Lang SA, Goessmann H, Nadalin S, Baumgart J, Farkas SA, et al. Right portal vein ligation combined with in situ splitting induces rapid left lateral liver lobe hypertrophy enabling 2-staged extended right hepatic resection in small-for-size settings. *Annals of Surgery*. 2012;**255**(3):405-414

[44] Wiederkehr JC, Avilla SG, Mattos E, Coelho IM, Ledesma JA, Conceição AF, et al. Associating liver partition with portal vein ligation and staged hepatectomy (ALPPS) for the treatment of liver tumors in children. *Journal of Pediatric Surgery*. 2015;**50**(7):1227-1231

[45] Lam VWT, Laurence JM, Johnston E, Hollands MJ, Pleass HCC, Richardson AJ. A systematic review of two-stage hepatectomy in patients with initially unresectable colorectal liver metastases. *HPB*. 2013;**15**(7):483-491

[46] Shindoh J, Vauthey J-N, Zimmitti G, Curley SA, Huang SY, et al. Analysis of the efficacy of portal vein embolization for patients with extensive liver malignancy and very low future liver remnant volume, including a comparison with the associating liver partition with portal vein ligation for staged hepatectomy approach. *Journal of American College of Surgeons*. Jul 2013;**217**(1):126-134. DOI: 10.1016/j.jamcollsurg.2013.03.004. Epub 2013 Apr 28

[47] Wanis KN, Ardiles V, Alvarez FA, Tun-Abraham ME, Linehan D, de Santibañes E, et al. Intermediate-term survival and quality of life outcomes in patients with advanced colorectal liver metastases undergoing associating liver partition and portal vein ligation for staged hepatectomy. *Surgery (United States)*, Elsevier Inc., Available from. 2018;**163**(4):691-697

<https://doi.org/10.1016/j.surg.2017.09.044>

[48] Sandström P, Røsok BI, Sparrelid E, Larsen PN, Larsson AL, Lindell G, et al. ALPPS improves resectability compared with conventional two-stage hepatectomy in patients with advanced colorectal liver metastasis: Results from a scandinavian multicenter randomized controlled trial (LIGRO trial). *Annals of Surgery*. 2018;**267**(5):833-840

[49] Schnitzbauer AA, Schadde E, Linecker M, Machado MA, Adam R, Malago M, et al. Indicating ALPPS for colorectal liver metastases: A critical analysis of patients in the international ALPPS registry. *Surgery (United States)*, Elsevier Inc.; 2018;**164**(3):387-394. Available from: <https://doi.org/10.1016/j.surg.2018.02.026>

[50] Sarpel U, Bonavia AS, Grucela A, Roayaie S, Schwartz ME, Labow DM. Does anatomic versus nonanatomic resection affect recurrence and survival in patients undergoing surgery for colorectal liver metastasis? *Annals of Surgical Oncology*. 2009;**16**(2):379-384. Available from: <http://www.springerlink.com/index/10.1245/s10434-008-0218-2>

[51] Veereman G, Robays J, Verleye L, Leroy R, Rolfo C, Van Cutsem E, et al. Pooled analysis of the surgical treatment for colorectal cancer liver metastases. *Critical Reviews in Oncology/Hematology*. 2015;**94**(1):122-135. Available from: <http://linkinghub.elsevier.com/retrieve/pii/S1040842814002121>

[52] De Jong MC, Pulitano C, Ribero D, Strub J, Mentha G, Schulick RD, et al. Rates and patterns of recurrence following curative intent surgery for colorectal liver metastasis: An international multi-institutional analysis of 1669 patients. *Annals of Surgery*. 2009;**250**(3):440-447

[53] Margonis GA, Sergentanis TN, Ntanasis-Stathopoulos I, Andreatos N, Tzanninis I-G, Sasaki K, et al. Impact of surgical margin width on recurrence and overall survival following R0 hepatic resection of colorectal metastases: A systematic review and meta-analysis. *Annals of Surgery*. 2018;**267**(6):1047-1055. Available from: <http://insights.ovid.com/crossref?an=00000658-201806000-00012>

[54] Pawlik TM, Scoggins CR, Zorzi D, Abdalla EK, Andres A, Eng C, et al. Effect of surgical margin status on survival and site of recurrence after hepatic resection for colorectal metastases. *Annals of Surgery*. 2005;**241**(5):715-722, discussion 722-4. Available from <http://www.ncbi.nlm.nih.gov/pubmed/15849507>

[55] Brudvik KW, Mise Y, Chung MH, Chun YS, Kopetz SE, Passot G, et al. RAS mutation predicts positive resection margins and narrower resection margins in patients undergoing resection of colorectal liver metastases. *Annals of Surgical Oncology*. 2016;**23**(8):2635-2643. Available from: <http://link.springer.com/10.1245/s10434-016-5187-2>

[56] Margonis GA, Sasaki K, Andreatos N, Kim Y, Merath K, Wagner D, et al. KRAS mutation status dictates optimal surgical margin width in patients undergoing resection of colorectal liver metastases. *Annals of Surgical Oncology*. 2017;**24**(1):264-271. Available from: <http://link.springer.com/10.1245/s10434-016-5609-1>

[57] Butte JM, Gönen M, Allen PJ, Peter Kingham T, Sofocleous CT, DeMatteo RP, et al. Recurrence after partial hepatectomy for metastatic colorectal cancer: Potentially curative role of salvage repeat resection. *Annals of Surgical Oncology*. 2015;**22**(8):2761-2771. Available from: <http://link.springer.com/10.1245/s10434-015-4370-1>

[58] Wicherts DA, de Haas RJ, Salloum C, Andreani P, Pascal G, Sotirov D,

et al. Repeat hepatectomy for recurrent colorectal metastases. *British Journal of Surgery*. 2013;**100**(6):808-818. Available from: <http://doi.wiley.com/10.1002/bjs.9088>

[59] Adair RA, Young AL, Cockbain AJ, Malde D, Prasad KR, Lodge JPA, et al. Repeat hepatic resection for colorectal liver metastases. *British Journal of Surgery*. 2012;**99**(9):1278-1283. Available from: <http://doi.wiley.com/10.1002/bjs.8845>

[60] Ishiguro S, Akasu T, Fujimoto Y, Yamamoto J, Sakamoto Y, Sano T, et al. Second hepatectomy for recurrent colorectal liver metastasis: Analysis of preoperative prognostic factors. *Annals of Surgical Oncology*. 2006;**13**(12):1579-1587. Available from: <http://www.springerlink.com/index/10.1245/s10434-006-9067-z>

[61] Gomez D, Sangha VK, Morris-Stiff G, Malik HZ, Guthrie AJ, Toogood GJ, et al. Outcomes of intensive surveillance after resection of hepatic colorectal metastases. *British Journal of Surgery*. 2010;**97**(10):1552-1560. Available from: <http://doi.wiley.com/10.1002/bjs.7136>

[62] Bodingbauer M, Tamandl D, Schmid K, Plank C, Schima W, Gruenberger T. Size of surgical margin does not influence recurrence rates after curative liver resection for colorectal cancer liver metastases. *British Journal of Surgery*. 2007;**94**(9):1133-1138. Available from: <http://doi.wiley.com/10.1002/bjs.5762>

[63] de Haas RJ, Wicherts DA, Flores E, Azoulay D, Castaing D, Adam R. R1 resection by necessity for colorectal liver metastases: Is it still a contraindication to surgery? *Annals of Surgery*. 2008;**248**(4):626-637. Available from: <https://insights.ovid.com/crossref?an=00153307-200801260-00031>

[64] Andreou A, Brouquet A, Abdalla EK, Aloia TA, Curley SA, Vauthey JN.

Repeat hepatectomy for recurrent colorectal liver metastases is associated with a high survival rate. *HPB (Oxford)*. 2011;**13**(11):774-782. Available from: <http://linkinghub.elsevier.com/retrieve/pii/S1365182X15303749>

[65] Neal CP, Nana GR, Jones M, Cairns V, Ngu W, Isherwood J, et al. Repeat hepatectomy is independently associated with favorable long-term outcome in patients with colorectal liver metastases. *Cancer Medicine*. 2017;**6**(2):331-338. Available from: <http://doi.wiley.com/10.1002/cam4.872>