

## Chapter

# Craniofacial Corrective Surgery in Syndromic Craniosynostosis

*Khairul Bariah Chi Adam, Firdaus Hariri, Wei Lee Chee, Kathiravan Purmal, Mohd Faizal Abdullah and Nazer Berahim*

## Abstract

This surgical field has now progressed and becoming an established subspecialty involving various surgical disciplines worldwide. Various complex CMF syndromes reported in syndromic craniosynostosis include Crouzon, Apert and Pfeiffer syndromes. These syndromes carry specific functional discrepancies associated with the affected structural anomaly and may therefore have functional issues involving the brain, eye and airway among others. As corrective surgery is often indicated depending on the affected vital functions, other factors that need to be considered are patient's age, comorbidities, urgency, available expertise and patient's overall prognosis based on the degree of anomaly. As such, the corrective surgery can be categorized into; (1) intermediate which is performed at an early phase and aimed to improve or salvage important vital functions such as the brain, eye, airway or feeding which are important for the child's development and, (2) definitive treatment aimed at permanently correct the functional discrepancies. Intermediate corrective surgery may include invasive procedures such as ventriculo-peritoneal (VP) shunts, tarsorrhaphy, adenotonsillectomy and tracheostomy whereas definitive corrective surgery may include surgical procedures such as monobloc, Le Fort III osteotomy, posterior cranial vault expansion and mandibular advancement. This chapter will elaborate on the indications, types, challenges in the management and the proposed prevention measures in corrective surgery for specifically for syndromic craniosynostosis patients.

**Keywords:** corrective surgery, syndromic craniosynostosis, craniofacial surgery

## 1. Introduction

Syndromic craniosynostosis is a condition which involves premature fusion of multiple skull sutures and may be associated with extracranial deformities such as limb, cardiac and tracheal malformations [1, 2]. Therefore, this syndrome usually comes with related issues such as increased intracranial pressure which can cause visual impairment (increased intraocular pressure), sleep impairment and eating difficulties due to midface hypoplasia, and even risk of impairment of mental development [3]. There are about 150 syndromes associated with craniosynostosis namely Crouzon, Pfeiffer and Apert syndrome.

Therefore, corrective surgery in syndromic craniosynostosis were developed in relation to its deformities and functional issues. Conventional craniofacial surgical techniques, such as strip craniectomy, fronto-orbital advancement, and Le Fort III procedures proved to be reliable to treat symptomatic syndromic craniosynostosis. However, limitations were observed in severe conditions where large segmental advancement were required, difficulty to close the gap primarily as well as inadequate stability secondary to soft tissue restriction and unstable bone segment fixation. These limitations thus causing relapse and creating less than an ideal long-term outcome [4]. Hence distraction osteogenesis (DO) were introduced to provide a reliable surgical alternative in achieving superior segmental advancement compared with conventional techniques in treating functional issues in syndromic craniosynostosis.

Syndromic craniosynostosis patients usually presented with multiple major functional disturbances which requires multi-disciplinary management including maxillofacial surgery, neurosurgery, plastic surgery and ENT among others. As such, the indication for each major surgery in paediatric patients with this condition should be discussed by the craniofacial team members as the procedure carries substantial mortality and morbidity risks [5].

## **2. Syndromic craniosynostosis and the genetic perspectives**

Craniosynostosis was first known as craniostenosis that was introduced by German pathologist, Virchow in 1851. It was then changed to craniosynostosis and widely accepted ever since [6]. Craniosynostosis is a condition whereby the process of early or premature fusion of the skull sutures happens that leads to the unwanted growth pattern of the skull. The skull will not be able to grow perpendicular to the fused suture but instead will grow in parallel direction to the fused suture. The brain will use the space available to grow and cause an abnormal head shape and facial features [7]. In cases whereby the skull does not have any spaces due to fused sutures, the brain will continue to grow thus causing increased in intracranial pressure hence patient will develop visual disturbances, sleeping impairment due to airway disruption, eating difficulties because of unusual jaw growth and reduction in mental development.

Most known craniosynostosis cases are nonsyndromic and can occur as an isolated event or associated with other skeletal and developmental anomalies in specific clinical features for recognized syndromes. Patients who have been diagnosed with syndromic craniosynostosis are much more complex and require a multidisciplinary approach to effectively manage all the problems faced. Most of the syndromic craniosynostosis cases are due to genetic defect that may present as autosomal dominant, autosomal recessive and X-linked patterns of inheritance. The molecular genetic protocol for the diagnosis of syndromic craniosynostosis such Crouzon syndrome includes first-line tests of FGFR2 exons IgIIIa and IgIIIc followed by second-line tests of FGFR2 exons 3, 5, 11, and 14 to 17 and FGFR3 Pro250Arg and Ala391Glu as proposed by Wilkie et al. [7]. There are multiple types of syndromic craniosynostosis cases but almost all of the them shared the same craniomaxillofacial features such as exophthalmos, midface hypoplasia, cranial base anomalies as well as abnormal face with the additional limb anomalies [8–9]. Syndromic craniosynostosis occurs in 1:8750 newborns [10–13]. The most common syndromic craniosynostosis cases identified and managed are Crouzon, Apert, and Pfeiffer syndromes. These syndromes may be presented with identical craniomaxillofacial features. Therefore, it is prudent to differentiate to achieve an accurate diagnosis by relating to other features such digital or limb anomalies.

## **2.1 Crouzon syndromes**

Clinically, patients may present with brachycephaly, small or shallow orbits with exophthalmos, midface hypoplasia and occlusal anterior open bite. However, there are no recorded cases that anomalies involving limbs are present. It is an autosomal dominant inheritance pattern that showed mutations in the fibroblast growth factor receptor 2 (FGFR-2) and occurred in 1 in 25,000 live births thus the most common syndromic craniosynostosis identified. Patients who have been diagnosed often have normal intelligence. Several cases identified as higher risk of increased intracranial pressure compared to other syndromic craniosynostosis cases [8, 14, 15]. The most common synostosis pattern observed is bicoronal synostosis which leads to brachycephalic shape, others such as scaphocephaly, trigonocephaly and cloverleaf skull have been diagnosed. Early fusion of cranial sutures resulted in shallow orbits and eye proptosis, small & high arched palate and anterior open bite. Eye proptosis or exorbitism can cause exposure conjunctivitis, keratitis, visual acuity problems and herniation of the globe. The synostosis will lead to midface hypoplasia as well and with normal development of mandible, class III skeletal profile & malocclusion formed. There are also other conditions reported such conductive hearing deficit, strabismus and hydrocephalus.

## **2.2 Apert syndromes**

Often patients will present with turribrachycephaly, midface hypoplasia, symmetrical syndactyly of both hands and feet. It is also an autosomal dominant inheritance pattern with mutations in FGFR-2 occurring in 1 in 100,000 births with cases seen are sporadic new mutations. Bicoronal synostosis with large anterior fontanelle, bitemporal widening and occipital flattening is common presentation in most patients. In this syndrome, the midface hypoplasia is more severe than others with concavity of the face, very shallow orbits, mild hypertelorism and downslanting palpebral fissure, eye proptosis, cleft palate, anterior open bite. It will have the characteristic depressed nasal bridge and downward tip resulting in parrot beak deformity. The severe hypoplastic midface in Class III skeletal features will result in a small airway that causes airway compromise needing a tracheostomy to secure the airway.

Pathognomonic syndrome will be the hand syndactyly which often involve fusion of the second, third and fourth fingers that lead to middigital hand mass with the first and fifth fingers may also join. In certain cases, if the thumb is free, it is broad and deviates radially. In the feet, syndactyly will involve the second, third and fourth toes. Patients will suffer loss of function and referral to a hand surgeon is essential. Many patients have normal intelligence despite of some cases delayed mental development identified. Marruci et al. published the Great Ormond Street Hospital data on the expectant management of their patients in raised ICP in Apert syndrome. Their protocol is to offer cranial vault expansion only in the setting of confirmed elevation of ICP. Raised ICP developed in 83% of patients, 50% in the first year of life with the average age at onset was at 18 months. 35% of those treated successfully for their first episode however, went on to develop a second episode on average 3 years 4 months later [16].

## **2.3 Pfeiffer syndrome**

Characterized by features of craniofacial anomalies from mild to severe condition. It includes turribrachycephaly, midface hypoplasia, exorbitism and

the pathognomonic features of broad thumbs and great toes with variable soft tissue syndactyly. Other associated features include hypertelorism, strabismus, downslanting palpebral fissures, class III malocclusion and beaked nasal deformity. Again, the majority of cases involve FGFR-2 mutations, 5% of patients express an FGFR-1 mutation and demonstrate less severe phenotype [17, 18]. It is an autosomal dominant inheritance pattern with the incidence of 1 in 100,000 births. A classification system proposed that patients are categorized into three types based upon clinical findings and severity. Type 1 is the classic Pfeiffer syndrome clinical pattern. Type 2 is more severe and associated with the cloverleaf skull and type 3 Pfeiffer syndrome is the most severely affected. In one institution, a review of 28 patients has been conducted and the Cohen subtypes dissemination is 61% type 1, 25% type 2 and 14% type 3 [19]. All patients have undergone numerous corrective surgery. This study recommends aggressive treatment and monitoring on patients' functional conditions to prevent further damage to the vital organ that leads to permanent loss of function.

Therefore, syndromic craniosynostosis is a condition of multiple associated clinical problems with the same pattern of treatment strategies, expected difficulties and pathologic identifications. Profound knowledge of the disease process, pathognomonic findings and clinical situations of each syndrome is essential. Therefore, multidisciplinary approach in total management of the clinical problems is important and must be detected and treated earlier to improve patient's functional conditions and quality of life.

### **3. Corrective surgery**

#### **3.1 Pre-surgical assessment & preparation**

In syndromic craniosynostosis, surgical intervention is often functionally indicated with the primary aim is to treat the pressing functional discrepancy or to salvage vital structures such as the brain and eyes [4, 20]. The three main functional issues secondary to the severe skull deformity are increased intracranial pressure, severe exophthalmos and obliterated nasopharyngeal airway. As such, comprehensive assessment to the brain, eyes and upper airway is paramount to determine the specific problem prior to any surgical decision.

##### *3.1.1 Multi-disciplinary approach*

Taking the multiple functional issues into consideration, multi-disciplinary approach has become the trend in syndromic craniosynostosis management. A craniofacial centre or unit may consist of various specialties such as neurosurgery, oral and maxillofacial surgery, plastic surgery, otorhinolaryngology, ophthalmology, and oculoplastic, among others.

##### *3.1.2 General assessment*

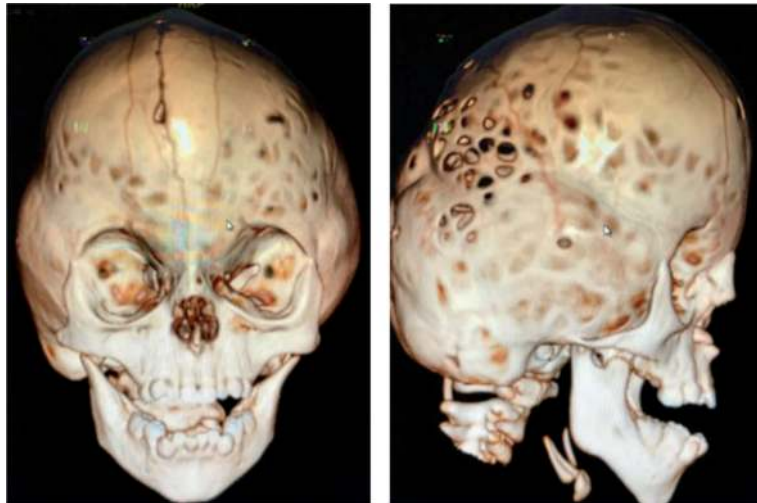
Patient growth progress and development should be assessed and properly documented as it provides valuable baseline and comparative data before and after surgery. This includes objective data such as head circumference, height, weight, gross and fine motor, as well as speech development, among others. These parameters are important as it may determine whether any corrective surgery should be indicated as early as possible or performed at a later stage [21].

### 3.1.3 Clinical assessment

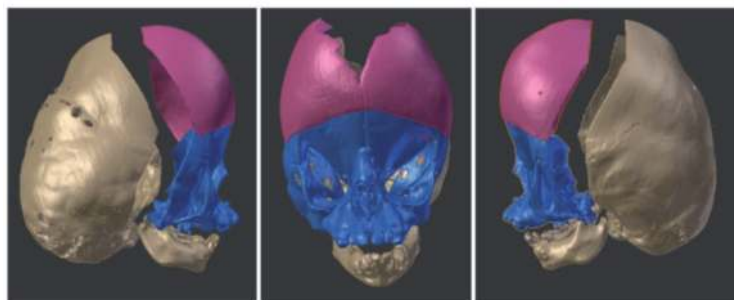
Specifically on the craniofacial region, assessment can be focused on patient's initial head shape, the degree of exophthalmos, ability for eyelid closure, nasal air-flow, midfacial projection, jaw relationship and intraoral condition. Clinical picture documentation is very useful as it can be used for serial comparison.

### 3.1.4 Imaging assessment

Imaging modalities provide valuable input in identifying a specific functional issue. Magnetic resonance imaging (MRI) or CT scan may indicate any anomaly in the brain region and the condition of skull bone, respectively. Thinning of bone or copper beaten appearance is an indication to raised intracranial pressure necessitating corrective surgery to improve the intracranial volume via procedures such as posterior vault expansion or fronto-orbital advancement as shown in **Figures 1** and **2**.



**Figure 1.**  
*Thinning of the skull bone noted from the reconstructed 3D CT scan.*



**Figure 2.**  
*Surgical simulation on the monobloc advancement of the frontofacial segment.*

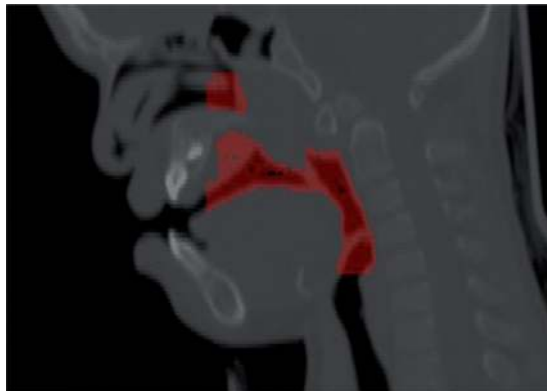### 3.1.5 Ophthalmological assessment

Specific ophthalmological assessment such as retinal camera or funduscopy provides information of the interior surface of the eye, including the retina, vasculature, optic disc and macula. Pale disc may be an indication of increased intracranial

pressure. Tonometry can be performed to measure the intraocular pressure. Assessment of the volume of eye sockets is also important and can be conducted via the analysis of CT scan.

### *3.1.6 Airway assessment*

For the airway, endoscopic examination is often performed to determine the cause of airway obliteration. The cause can either be due to soft tissue or hard tissue or both. Specific recognition of the anatomical restriction allows the surgical team to decide on the most ideal corrective surgical intervention such as shown in **Figure 3**. As most syndromic craniosynostosis patients are classically presented with midface hypoplasia, polysomnography (PSG) is the gold standard to diagnose obstructive sleep apnea (OSA).



**Figure 3.**  
*Airway assessment using software and CT scan.*

### *3.1.7 Pre-operative preparation*

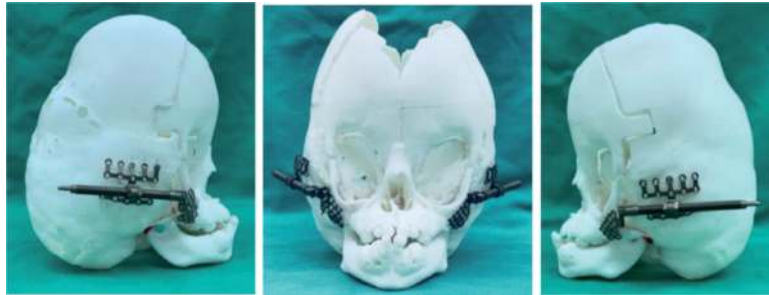
Other pre-surgical preparation includes patient optimization prior to surgery via comprehensive in ward assessment by paediatric respiratory physician and anaesthetist.

Patient's CT image can be used for surgical simulation using surgical software and utilized for 3D model fabrication to optimize the corrective surgery outcomes as shown in **Figure 4**. The technology provides precision and significantly reduces the operating hours thus minimizing the potential complication such as intra-operative bleeding [21–24]. All patients in the authors' center had their 3D skull bio-model fabricated to allow surgical simulation and vector determination to optimize the outcome of surgery. The pre-bending of the distractor footplates for the internal device and presurgical simulation proved critical because it contributed to the precision of device fixation and correct segmental movement to ensure a favorable final outcome and decrease operating time.

The selection of devices is based on device suitability and functional indications. Increased ICP was assessed by history, presence of signs or symptoms, imaging analysis, and ophthalmologic assessment. For the eye, the patients' ability to achieve eyelid closure was assessed and documented and supplemented with eye examinations that included optic disc condition and cup-to-disc ratio through funduscopy. Airway function was assessed by polysomnography and digital airway assessment.

Intra-operative complications should be anticipated thus preparation should include paediatric intensive care unit booking, blood cross-matched and reserve for transfusion as well as appropriate drug prescription.

When certain corrective surgery has been agreed by the multi-disciplinary team, consent should be clear and comprehensive with consideration of various complications ranging from mild to severe degree, at intra-operative and post-operative phase.



**Figure 4.**  
*Simulation of the surgical procedures using reconstructed 3D STL model from the CT scan.*

### **3.2 Surgical techniques and its application**

Following comprehensive assessment from the craniofacial team, the choice of surgery basically depends on the aim, condition of the patient, skill of the surgeons and the facility. Hariri et al. [25] proposed for a protocol to indicate the type of intervention based on the aim of the functional rehabilitation. The protocol explained on the extend of surgical treatment depending on the patient's severity, age as well as whether it can be done in stages or in combination to address the issues.

In multiple aims for rehabilitation in very young patient for example, increased ICP with hydrocephalus would necessitate less extensive surgical intervention such as ventriculoperitoneal (VP) shunting, while severe orbital proptosis might indicate temporary tarsorrhaphy, and respiratory difficulty would necessitate a continuous airway pressure device, a nasal stent, or a tracheostomy depending on the severity and the specific anatomic obstruction. More extensive surgical procedures are usually deferred up to certain age to reduce possibility of complications.

#### *3.2.1 Posterior vault distraction/expansion*

Posterior cranial vault expansion is usually indicated in increased in ICP cases without other functional issues when the patient's age is more suitable [26, 27]. The aim is to increase the cranial volume to accommodate for the brain growth whilst reducing the intra cranial pressure.

#### *3.2.2 Fronto orbital advancement and Monobloc Le Fort III advancement*

Increased ICP with orbital proptosis might require fronto-orbital advancement with or without cranioplasty, and increased ICP in the presence of orbital proptosis and hypoplastic maxilla might require a monobloc as practiced in the authors' center. Surgery can be performed conventionally or combined with distraction osteogenesis (DO) technique, which is indicated for superior structural expansion and achieving simultaneous new histogenesis compared with conventional surgical procedures [28]. The application of DO in treating craniofacial deformity was first reported in 1992 [29]. Since then, the benefits of this technique in treating syndromic craniosynostosis as reported in the literature are similar to those in the present study, which

include marked improvements in functional parameters involving eye protection, preventing the increase of ICP, and treating airway deficiency [30–34].

### *3.2.3 Le Fort III osteotomy*

Le Fort III advancement is aimed on improving the proptotic condition as well as opening the space for the upper airway. Syndromic craniosynostosis patients may be presented with restricted upper airway thus causing obstructive sleep apnoea and shallow orbital floor. This allows the floor of the orbit to be advanced while opening the upper airway region on the nasal and maxillary region. This technique can be performed via conventional advancement or via DO depending on the amount of advancement and the experience of the team.

### *3.2.4 Le Fort I osteotomy*

This is usually indicated in a later stage when the patient is more stable in growth to correct skeletal discrepancies such as retruded maxilla thus causing OSA. Therefore, the maxilla is advanced to gain space for airway. This procedure may be combined with other soft tissues surgery to gain optimum results in opening the airway such as tonsillectomy and adenoidectomy.

## **4. Complications**

Craniofacial surgery is one of the established multidisciplinary specialty to produce safe surgery and good surgical outcome whilst minimizing the complications following surgical intervention for syndromic craniofacial patients. Although the results can be satisfying and there is general agreement on surgical indications, the potential remains for unwanted complications. The craniofacial surgery is unique because it involves exploration of the areas that allow very little margin of error. An inadequate knowledge of the anatomy, lack of training and surgical expertise can lead to not only disastrous results but even to the death of the patient. Any team that cares for craniofacial patients must take steps to avoid potential complications and be ready to deal with postoperative complications. Development of craniofacial surgery pioneered by Paul Tessier was a crucial step towards the paradigm shift in treating major craniofacial syndromic deformities [35].

### **4.1 Mortality and morbidity rate following craniofacial surgical intervention**

The complications are the events that occurs during the management of craniofacial syndromes patients and may associated with any permanent deleterious effect on the patient. However, unfavourable outcomes generally are unexpected by the patients or surgeons [36].

The platinum rule to avoid any unwanted complications in any performed surgical procedures is to follow the dictum “Primum Non Nocere”.

Many authors attempted to classify the complications of craniofacial surgery that arise during intraoperative and postoperative, but these complications might differ with different craniofacial syndromes. Intraoperative and post-operative complications pertaining to cranial vault surgery was described and classified into early, immediate post-operative and late postoperative complications [37–42]. Given the uniqueness presentation of patients with craniofacial syndromes, each patient presented with their



own problems and complications following surgical intervention might be different from each other thus the need for comprehensive classification systems.

One of the easiest way to classify the complications following surgical intervention are by Sharma et al. 2013 [41] which was divided into four types:

*Type 1:* Minor events without any damaging effects on the patient. They include minor wound infections, poorly placed scars, minor cerebrospinal fluid leaks, and seromas/hematomas. Most of the time, this classification refers to less serious and minor complications following craniofacial surgery that consists of:

#### Epiphora

This is most of the time seen after hypertelorism correction but the reported incidence is quite low which is about 0.6% [42]. This is due to any procedure that involves dissection around the medial and inferomedial orbital floor may potentially damage the lacrimal drainage system.

#### Lateral canthal ligament dystopia

Extensive stripping of periorbita may lead to reattachment of periorbita at low level eventually resulting in enhanced antimongoloid slant. This is most frequently seen on syndromic rather than nonsyndromic craniofacial syndrome [22].

#### Hardware issues

Hardware can be considered as a foreign body thus occasionally can be infected, exposed or even palpable postoperatively. Infection and exposure of fixation material are rare in paediatric cranial vault surgery [42]. Metal fixation carry a possibility of intracranial fixation due to appositional cranial growth. Some reported translocation of hardware into calvarial bone in 14% and 6.6% with intracranial translocation and commonly occur in younger and syndromic patients [28]. Therefore, usage of resorbable hardware has now become more popular due to concerns about constriction of growth by metal fixation and the possibility of implant translocation [29–32].

#### Bone graft donor morbidity

Pneumothorax incidence of 3% after rib harvesting in their experience but emphasized that the rates vary from 5–30% in other series [33].

*Type 2:* Moderate-to-severe events that compromise the results and might need another surgical intervention for a successful outcome. They include exposure keratitis, diplopia, contour deformities, warping, non/malunion, and exposed hardware.

Strabismus and temporary ptosis are frequently seen after cranial vault procedures that involve periorbita stripping [37]. McCarthy et al. noted preoperative strabismus in hypertelorism cases, which often worsened after surgery then stabilized approximately 6 months after surgery [38].

Cerebrospinal fluid (CSF) leak following craniofacial surgery and sequelae of neurosurgical infection is common. Obvious risk for infection with CSF was noted but also associated with impairment of wound healing. Predisposing factor that might lead to easy tear of dura are due to scar from previous surgery or abnormal bony contour with dural adhesion [36–39]. Some tears may go unnoticed, and CSF may manifest postoperatively either as rhinorrhoea or leakage through the scalp wounds or within the drain itself.

Transient hyponatremia is one of the reported complications caused by secretion of inappropriate antidiuretic hormone (diabetes insipidus) has been reported [27, 40–44]. Researchers believe that it results from traction on the frontal lobes.

Unexpected airway issues are other complications following craniofacial surgery, in which emergency reintubation or even prolonged ventilation is needed due to severe upper airway oedema. Decision for steroid covers for upper airway oedema is most of the time anecdotal but some reported beneficial in preventing facial oedema postoperatively [45–50].

*Type 3:* Serious events with unfavourable result which can or cannot be successfully managed. They include nerve palsies and infection leading to bone loss and partial loss of vision.

Infection is the most common complication in the form of osteitis/osteomyelitis, meningitis, or an intracranial abscess, occurring in 6.2% of transcranial cases [25]. Overall reported infection rates ranging from 1–14% in large centre series [27, 32, 39–42, 47–51].

Permanent neurological deficit is another complication in craniofacial surgery that fall into type III classification. Majority of craniofacial surgery confined to extradural showed lower incidence of neurologic impairment. Several reports from major craniofacial centers has shown very low or no permanent neurologic deficits directly attributable to surgery [27, 30, 37, 50–52]. Blindness for example, is an unwanted complication in craniofacial surgery that post a real risk of blindness following surgery. Munro and Sabatier noted four cases of permanent blindness in 1092 procedures [54].

*Type 4:* Serious events that may even lead to death. They include postoperative infection, perioperative bleeding, respiratory compromise, or other serious anesthesia-related events.

Since 1970's to 1988, rate of mortality in craniofacial surgery were reported ranging from 1 to 2% all over the world [47–51]. However, with development of the technology, deeper understanding of the craniofacial surgery and its risks with emphasis on multidisciplinary approach, the numbers of mortality have dropped to 0.1–0.8% in some centers [24–29].

## **5. Research and development in corrective surgery**

With the recent medical and technology advancement, patient management was more promising and in a well-controlled manner. The surgical management of craniosynostosis patient resurfaces again in the mid-20th century as a completely stand-alone surgical specialty. A more well defined surgical procedure, better anaesthetic protocols, together with the help of advanced technology, this group of patients now enjoy a safer surgical outcome [52–57].

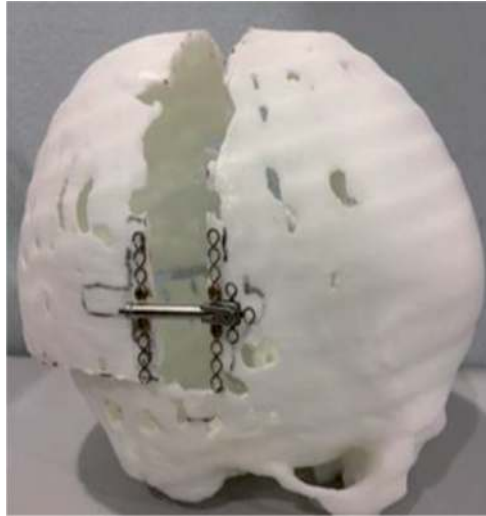
### **5.1 Optimal age of surgery**

Surgical procedures advocated in this group of patients are aim to make sure normal growth of the brain and skull, and near to normal development to their adulthood. Controversy still on-going with the best timing of surgical intervention in this group of patients between early versus late surgical intervention. Early surgical intervention is always aiming for better corneal protection and to create spaces for constricted brain. Late surgical intervention conversely aiming for more stable bony correction and less likely for subsequent surgical intervention [50]. However, our center practice on more indication and need-based approach, surgical intervention at the best possible timing for patients in term of growing stage, the indication need for the surgery and patient's general health condition [4].

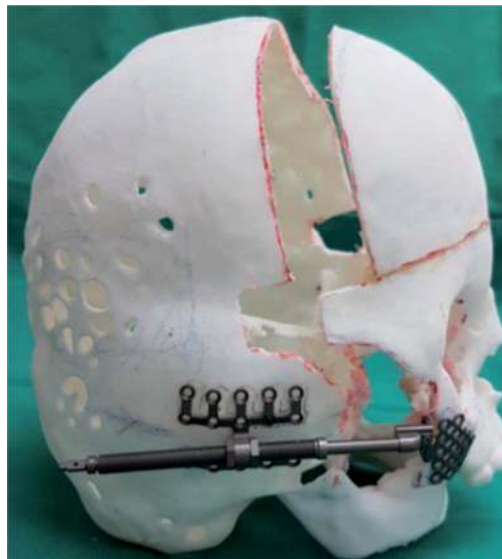
### **5.2 Choices of osteotomy**

Surgical procedures evolved from strip craniectomy, monobloc osteotomy, fronto orbital advancement and recently, posterior vault expansion. All these procedures are indicated to release the fused cranial suture, re-create

more spaces for brain development and to make sure the bilateral eye globe is well protected as shown in **Figures 5** and **6**. The current treatment can be summarized in **Table 1**.



**Figure 5.**  
*Posterior vault distraction osteogenesis indicated for only increased ICP with no other symptoms.*



**Figure 6.**  
*Le Fort III advancement indicated for management of ICP, airway and orbital globe.*

Issues to manage	Treatment proposed
Only increase in ICP	Posterior cranial vault distraction
Increase in ICP and shallow orbit	Fronto orbital advancement
Reduced airway and shallow orbit	Le Fort III advancement
Reduced airway, shallow orbit and increased ICP	Monobloc advancement

**Table 1.**  
*Treatment proposed for management of syndromic craniosynostosis issues.*

Different surgeon will advocate different surgical technique at different timing, either with direct osteotomy and surgical plating or through distraction osteogenesis procedure [2, 4, 9, 49, 50, 58, 59]. There is no uniform surgical algorithm internationally, but more on surgeon or surgical center preferences. Obviously, these surgeries need collaboration of neurosurgeon, oral maxillofacial surgeon and otorhinolaryngologists.

### **5.3 Research**

The ultimate goals for craniosynostosis treatment is mainly to restore function, improve facial aesthetic and ensure a healthy psychological development. More research is needed in this syndromic craniosynostosis in term of treatment algorithm, utilisation of latest and advancement of computer planning, computer navigation, 3-dimensional printing and usage of the cheaper, user friendly and effective surgical device in making the surgery more safer and more predictable outcome. The treatment focus not only on the fused suture of the skull, but also make an effort to address issue like intracranial pressure, strabismus, abnormally positioned orbit and dentofacial deformities [60–62]. Another area of future development will be in the molecular genetic testing in the field of genetic counselling.

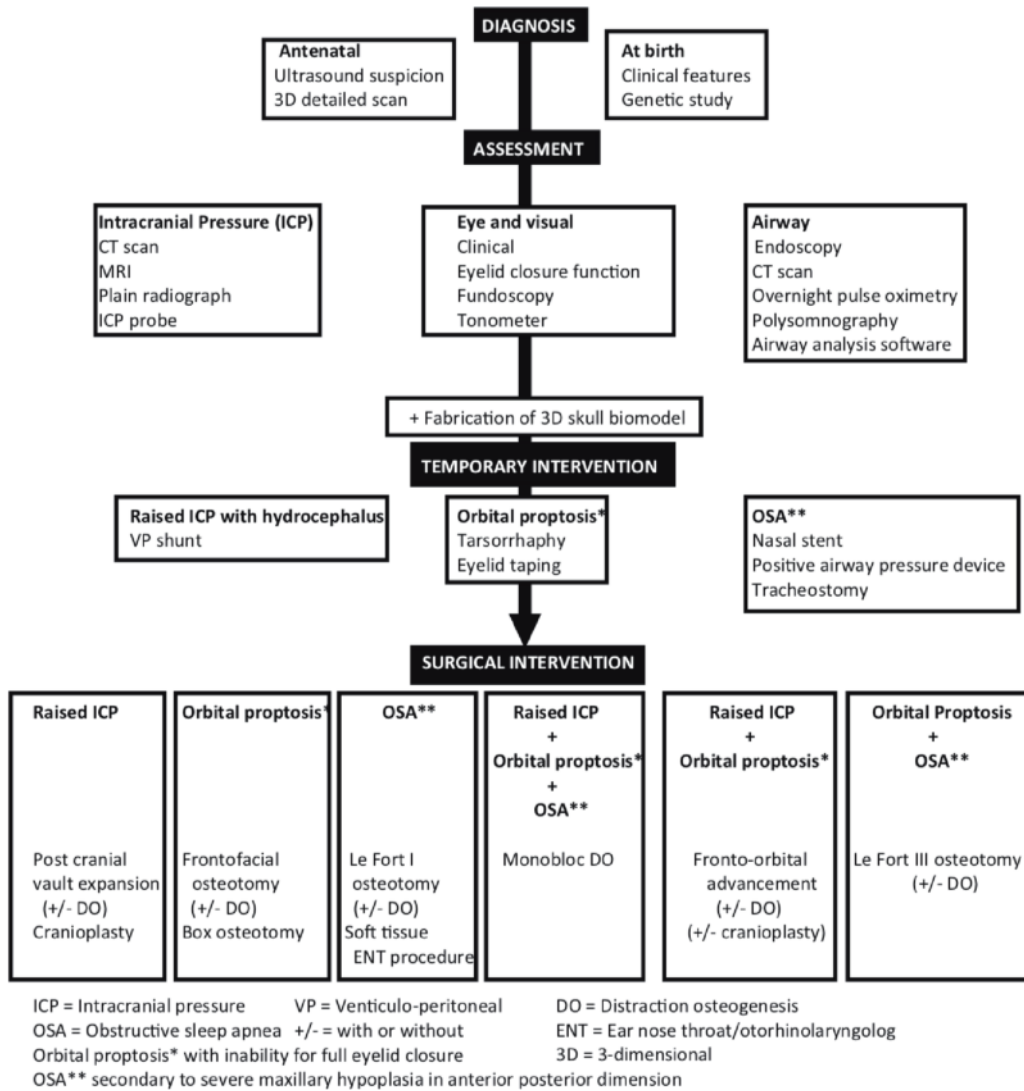
## **6. Conclusions**

Corrective surgery in syndromic craniosynostosis was formerly regarded as formidable however currently performed as a routine by major craniofacial center in the world due to advancement of technology and multidisciplinary approaches. Certain types of deformity, particularly those patients with Crouzon's or Apert's syndrome, require more than one functional intervention to achieve maximum correction.

In general, the surgical indication for paediatric CMF deformities can be classified into intermediate and definitive intervention. The intermediate intervention is performed at an early phase of patient's life and aimed to salvage vital tissue or organ function such as the brain, eye, airway or feeding which are essential for the child's development. The protocol of the management for syndromic craniosynostosis patients is summarized in **Figure 7**. These procedures include ventriculoperitoneal (VP) shunt, tarsorrhaphy, adenotonsillectomy and tracheostomy.

Therefore, these interventions in craniofacial syndromes is associated with multiple morbidities. It is important to understand the need and risks of these interventions prior making decision of treatment for each patient. Craniofacial teams should be cognizant to audit data on morbidity and mortality as well as surgical outcomes to monitor complication rates.

Surgical risk stratification involving the severity of patient's functional issues, age, co-morbidities, logistics, the timing and type of surgery and anticipated post-operative issues are in practiced to guide decision making consensus and serve as the index of precaution prior to any surgery [63]. This is in line with the recommendation of other centers which placed greater focus on protocols for airway management, blood salvage and replacement, age-appropriate deep venous thrombosis prophylaxis and timing of sub cranial midfacial advancements which might result in further reductions in craniofacial mortality rates.



**Figure 7.**  
 Summary of indications for intervention in craniofacial syndromes.

## Acknowledgements

We would like to thank everyone who were involved direct and indirectly in the making of this chapter, craniofacial team members, staff and patients in UMMC, HKL, and SASMEC@IIUM, Malaysia.

## Conflict of interest

The authors declare no conflict of interest.

## **Author details**

Khairul Bariah Chi Adam<sup>1\*</sup>, Firdaus Hariri<sup>2</sup>, Wei Lee Chee<sup>3</sup>, Kathiravan Purmal<sup>4</sup>, Mohd Faizal Abdullah<sup>5</sup> and Nazer Berahim<sup>6</sup>

1 Oral Maxillofacial Surgery and Oral Diagnosis Department, Kulliyyah of Dentistry, International Islamic University Malaysia, Kuantan, Malaysia

2 Department of Oral and Maxillofacial Clinical Sciences, Faculty of Dentistry, University Malaya, Kuala Lumpur, Malaysia

3 Oral Maxillofacial Surgery Department, Hospital Kuala Lumpur, Malaysia

4 Katte Dental Clinic, Kuala Lumpur, Malaysia


5 School of Dental Sciences, Health Campus, Universiti Sains Malaysia, Kota Bharu, Malaysia

6 Oral Maxillofacial Surgery Department, Faculty of Dentistry, Universiti Teknologi MARA, Selangor, Malaysia

\*Address all correspondence to: bariah@iium.edu.my

## **IntechOpen**

---

© 2020 The Author(s). Licensee IntechOpen. This chapter is distributed under the terms of the Creative Commons Attribution License (<http://creativecommons.org/licenses/by/3.0>), which permits unrestricted use, distribution, and reproduction in any medium, provided the original work is properly cited. 

## References

- [1] Slater BJ, Lenton KA, Kwan MD, Gupta DM, Wan DC, Longaker MT. Cranial sutures: a brief review. *Plastic and Reconstructive Surgery*. 2008;**121**(4):170e-178e
- [2] James CW, Laszlo N, Joshua CD. Syndromic craniosynostosis. *Facial Plastic Surgery Clinics*. 2016;**24**(4):531-543
- [3] Gault DT, Renier D, Marchac D, Jones BM. Intracranial pressure and intracranial volume in children with craniosynostosis. *Plastic and Reconstructive Surgery*. 1992;**90**(3):377-381
- [4] Hariri F, Azmi MN, Bahuri NF, Abdullah NA, Rahman ZA, Ganesan D. Crouzon syndrome: a case series of craniomaxillofacial distraction osteogenesis for functional rehabilitation. *J Oral Maxillofac Surg*. 2017;**76**(3):646.e1-646.e12.
- [5] Kimonis V, Gold JA, Hoffman TL, Panchal J, Boyadjiev SA. Genetics of craniosynostosis. *Seminars in Pediatric Neurology*. 2007;**14**(3):150-161
- [6] Wilkie AO, Bochukova EG, Hansen RM, et al. Clinical dividends from the molecular genetic diagnosis of craniosynostosis. *American Journal of Medical Genetics*. 1941;**143A**:200
- [7] Laitinen L, Sulamaa M. Craniosynostosis; symptoms, treatment and results of treatment. II. *Ann Paediatr Fenn*. 1956;**2**(1):1-8
- [8] Slater BJ, Lenton KA, Kwan MD, Gupta DM, Wan DC, Longaker MT. Cranial sutures: a brief review. *Plast Reconstr Surg*. 2008;**121**(4):170e – 8e.
- [9] Gault DT, Renier D, Marchac D, Jones BM. Intracranial pressure and intracranial volume in children with craniosynostosis. *Plastic and Reconstructive Surgery*. 1992;**90**(3):377-381
- [10] Derderian C, Seaward J. Syndromic craniosynostosis. *Seminars in Plastic Surgery* 2012;**26**(2):64-75.
- [11] Bannink N, Joosten KFM, van Veelen M-LC, Bartels MC, Tasker RC, van Adrichem LNA, et al. Papilledema in patients with Apert, Crouzon, and Pfeiffer syndrome: prevalence, efficacy of treatment, and risk factors. *The Journal of Craniofacial Surgery*. 2008;**19**(1):121-127
- [12] Johnson D, Wilkie AOM. Craniosynostosis. *European Journal of Human Genetics*. 2011;**19**(4):369-376
- [13] Sharma VP, Fenwick AL, Brockop MS, McGowan SJ, Goos JAC, Hoogeboom AJM, et al. Mutations in TCF12, encoding a basic helix-loop-helix partner of TWIST1, are a frequent cause of coronal craniosynostosis. *Nature Genetics*. 2013;**45**(3):304-307
- [14] Wilkie AOM, Byren JC, Hurst JA, Jayamohan J, Johnson D, Knight SJL, et al. Prevalence and complications of single-gene and chromosomal disorders in craniosynostosis. *Pediatrics*. 2010;**126**(2):e391-e400
- [15] Renier D, Sainte-Rose C, Marchac D, Hirsch JF. Intracranial pressure in craniostenosis. *Journal of Neurosurgery*. 1982;**57**(3):370-377
- [16] Thompson DN, Harkness W, Jones B, Gonzalez S, Andar U, Hayward R. Subdural intracranial pressure monitoring in craniosynostosis: its role in surgical management. *Child's Nervous System*. 1995;**11**(5):269-275
- [17] Marucci DD, Dunaway DJ, Jones BM, Hayward RD. Raised intracranial pressure in Apert syndrome. *Plastic and Reconstructive Surgery*.

Surgery. 2008;**122**(4):1162-1168  
discussion 1169-1170

[18] Cornejo-Roldan LR, Roessler E, Muenke M. Analysis of the mutational spectrum of the FGFR2 gene in Pfeiffer syndrome. *Human Genetics*. 1999;**104**(5):425-431

[19] Muenke M, Schell U, Hehr A, Robin NH, Losken HW, Schinzel A, et al. A common mutation in the fibroblast growth factor receptor 1 gene in Pfeiffer syndrome. *Nature Genetics*. 1994;**8**(3):269-274

[20] Fearon JA, Rhodes J. Pfeiffer Syndrome: A Treatment Evaluation [Internet]. Vol. 123, *Plast Reconstr Surg*. 2009. p. 1560-1569. Available from: 10.1097/prs.0b013e3181a2057e.

[21] Adam KBC, Mahdah S, Azmi MN, Kadir K, Nabil S, Hariri F. Distraction osteogenesis in the craniomaxillofacial region. Part 1: History, principles, indications, types and protocol. *Mal Journal of Oral and Maxillofacial Surgery*. 2014;**1**:1-7

[22] Al-Namnam NMN, Hariri F, Rahman ZAA. Distraction osteogenesis in the surgical management of syndromic craniosynostosis: a comprehensive review of published papers. *The British Journal of Oral & Maxillofacial Surgery*. 2018;**56**(5):353-366

[23] Hariri F, Kadir K, Nabil S, Abd Jabar MN, Samsudin AR, Rahman ZAA, et al. The use of 3-dimensional biomodel in planning paediatric craniofacial surgery. *Mal J Oral Maxillofac Surg*. 2014;**12**:8-13

[24] Cheung LK, Chua HDP, Hariri F, Lo J, Ow A, Zheng L. Chapter 30: Correction of Dentofacial Deformities. In M.A. Pogrel, K-E. Kahnberg & L. Andersson (Eds.), *Essentials of Oral and Maxillofacial*

*Surgery* (pp. 315-330). Oxford, UK: Wiley Blackwell

[25] Greensmith AL, Meara JG, Holmes AD, Lo P. Complications related to cranial vault surgery. *Oral and Maxillofacial Surgery Clinics of North America*. 2004;**16**:465-473. DOI: 10.1016/j.coms.2004.07.001

[26] Hariri F, Ariff ZAR, Bahuri NF, Azmi MN. Distraction osteogenesis in Crouzon syndrome. *J Oral Maxillofac Surg*. 2018;**76**:646.e1-646.e12.

[27] McMillan K, Lloyd M, Evans M, et al. Experiences in performing posterior calvarial distraction. *The Journal of Craniofacial Surgery*. 2017;**28**:664

[28] Salokorpi N, Vuollo V, Sinikumpu JJ, et al: Increases in cranial volume with posterior cranial vault distraction in 31 consecutive cases. 2017;*J Neurosurgery* 81:803.

[29] Witherow H, Dunaway D, Evans R, et al. Functional outcomes in monobloc advancement by distraction using the rigid external distractor device. *Plastic and Reconstructive Surgery*. 2008;**121**:1311

[30] McCarthy JG, Schreiber J, Karp N, et al. Lengthening the human mandible by gradual distraction. *Plastic and Reconstructive Surgery*. 1992;**89**(1)

[31] Polley JW, Figueroa AA, Charbel FT, et al. Monobloc craniomaxillofacial distraction osteogenesis in a newborn with severe craniofacial synostosis: A preliminary report. *The Journal of Craniofacial Surgery*. 1995;**6**:421

[32] Shin JH, Duncan CC, Persing J. Monobloc distraction: Technical modification and considerations. *The Journal of Craniofacial Surgery*. 2003;**14**:763

[33] Yu W, Wang M, Yao K, et al. Individualized therapy for treating



- obstructive sleep apnea in pediatric Crouzon syndrome patients. *Sleep Breath J.* 2016;**20**:1119
- [34] Witherow H, Dunaway D, Evans R, et al. Functional outcomes in monobloc advancement by distraction using the rigid external distractor device. *Plastic and Reconstructive Surgery.* 2008;**121**:1311
- [35] Tessier P. The definitive plastic surgical treatment of the severe facial deformities of craniofacial dysostosis, Crouzon's and Apert's disease. *Plastic and Reconstructive Surgery.* 1971;**48**:419-442
- [36] Adam KB, Hariri F, Cheung LK, Nabil S, Aung LO, Rahman ZA. Technical Issues in Craniomaxillofacial Distraction Osteogenesis: A Case Series. *Int Med J Malaysia.* 2018;**17**:109-114
- [37] Matthews D. Craniofacial surgery: indications, assessment and complications. *British Journal of Plastic Surgery.* 1979;**32**(2):96-105. DOI: 10.1016/0007-1226(79)90006-7
- [38] McCarthy JG, Thorne CHM, Wood-Smith D. Principles of craniofacial surgery: orbital hypertelorism. In: McCarthy JG, editor. *Plastic surgery Cleft lip and palate and craniofacial anomalies.* Vol. 4. WB Saunders; 1990. p. 2974-3012.
- [39] Marchac D, Renier D. Complications. In: Marchac D, Reiner D, editors. *Craniofacial surgery for craniosynostosis.* Boston. Little: Brown and Company; 1982. p. 176
- [40] Kirkpatrick WN, Koshy CE, Waterhouse N, Fauvel NJ, Carr RJ, Peterson DC. Paediatric transcranial surgery: a review of 114 consecutive procedures. *British Journal of Plastic Surgery.* 2002;**55**:561-564
- [41] Sharma RK. Unfavourable results in craniofacial surgery. *Indian J Plast Surg.* 2013;**46**:204-214
- [42] Whitaker LA, Munro IR, Salyer KE, Jackson IT, Ortiz-Monasterio F, Marchac D. Combined report of problems and complications in 793 craniofacial operations. *Plastic and Reconstructive Surgery.* 1979;**64**:198
- [43] Levine JP, Stelnicki E, Weiner H, Bradley JP, McCarthy JG. Hyponatraemia in the postoperative craniofacial pediatric patient population: a connection to cerebral salt wasting syndrome and management of the disorder. *Plastic and Reconstructive Surgery.* 2001;**108**:1501-1508
- [44] Steig PE, Mulliken JB. Neurosurgical complications in craniofacial surgery. *Neurosurgery Clinics of North America.* 1991;**2**:703-708
- [45] Habal MB. Prevention of postoperative facial oedema with steroids after facial surgery. *Aesthetic Plastic Surgery.* 1985;**9**:69-71
- [46] Neil-Dwyer JG, Evans RD, Jones BM, Hayward RD. Tumescence steroid infiltration to reduce postoperative swelling after craniofacial surgery. *British Journal of Plastic Surgery.* 2001;**54**:565-569
- [47] Israele V, Siegel JD. Infectious complications of craniofacial surgery in children. *Reviews of Infectious Diseases.* 1989;**11**:9-15
- [48] David DJ, Poswillo DE, Simpson DA. *The craniosynostoses: causes, natural history and management.* Berlin. Springer-Verlag; 1982
- [49] Taylor JA, Bartlett SP. What's new in syndromic craniosynostosis surgery? *Plastic and Reconstructive Surgery.* 2017;**140**:82e-93e
- [50] Proctor MR, Meara JG. A review of the management of single -suture craniosynostosis, past, present, and future. *Journal of Neurosurgery. Pediatrics.* 2019;**24**:622-631

- [51] Cerisola J, Rohwedder R. Bacterial contamination of the operating field in craniofacial surgery: a new schedule of antibiotic prophylaxis. In: Transactions of the Eighth International Congress of Plastic and Reconstructive Surgery. Montreal. 1983. p. 283-285.
- [52] Sebatier R, Munro IR, Lauritzen C. A review of two thousand craniomaxillofacial operations. In: Transactions of the Eighth International Congress of Plastic and Reconstructive Surgery. Montreal. 1983. p. 329-30
- [53] Whitaker LA, Munro IR, Jackson IT, Salyer KE. Problems in cranio-facial surgery. *Journal of Maxillofacial Surgery*. 1976;4:131
- [54] Converse JM, Wood-Smith D, McCarthy JG. Report on a series of 50 craniofacial operations. *Plastic and Reconstructive Surgery*. 1975;55:283
- [55] Poole MD. Complications in craniofacial surgery. *British Journal of Plastic Surgery*. 1988;41:608
- [56] Kececi Y, Ozek C, Gurler T, et al. Complications in craniofacial surgery: the Turkish experience. *The Journal of Craniofacial Surgery*. 2000;11(2):168-171. DOI: 10.1097/00001665-200011020-00012
- [57] Jones BM, Jani P, Bingham RM, Mackersie AM, Hayward R. Complications in paediatric craniofacial surgery: an initial four year experience. *British Journal of Plastic Surgery*. 1992;45:225-231
- [58] David DJ, Cooter RD. Craniofacial infection in 10 years of transcranial surgery. *Plastic and Reconstructive Surgery*. 1987;80:213-223
- [59] Munro IR, Sabatier RE. An analysis of 12 years of craniomaxillofacial surgery in Toronto. *Plastic and Reconstructive Surgery*. 1985;76:29
- [60] Yilmaz E, Mihci E, Nur B, Alper ÖM, Taçoş Ş. Recent Advances in Craniosynostosis. *Pediatric Neurology*. 2019;99:7-15
- [61] Guimarães-Ferreira J, Miguéns J, Lauritzen C. Advances in Craniosynostosis Research and Management. *Advances and Technical Standards in Neurosurgery*. 2004; 23-83.
- [62] Mahdah S, Bariah K, Azmi MN, Saleh I, Nabil S, Hariri F. Distraction osteogenesis in the craniomaxillofacial region. Part II: Peri-operative issues, surgical procedure, complications and reliability. *Mal. Journal of Oral and Maxillofacial Surgery*. 2015;13(1):1-10
- [63] Hariri F, Abdullah MF, Adam KB, Bahuri NF et. al. Analysis of complications following multidisciplinary functional intervention in paediatric craniomaxillofacial deformities. 2019. *Int J Oral Maxillofac*. DOI: 10.1016/j.ijom.2020.08.02