

# Surgical Approach of Cleft Lip/Palate Patients: The Brazilian Experience

*Henrique Cabrini Moreira and Wilber Bernaola-Paredes*

## Abstract

Cleft lip/palate (CL/P) are among the most common birth defects around the world with a prevalence of 1.43:1000 live births. Other studies have shown that the frequency is approximately 1 in 600/700 live births and correction involves prolonged treatment over many years. A variety of surgical techniques and modifications have been described regarding cleft lip and palate (CLP) treatment [2]. However, patients still seem to have concerns about their facial appearance, especially related to the cleft deformity. The self-perceived improvement in facial appearance following treatment had a strong positive influence on quality of life and patient satisfaction compared to other functional or treatment-related factors. Depending on the cleft type and severity, as well as treatment outcome, important functions like eating, speech, appearance, and maxillary growth may be impaired. This can affect patients social-emotional functioning and self-esteem resulting in a lower health-related quality of life.

**Keywords:** cleft lip, cleft palate, spina, surgical approach, palatoplasty, cheiloplasty, seasonal factor, Brazilian experience

## 1. Cleft lip/palate: general considerations

Cleft lip/palate (CL/P) are among the most common birth defects around the world with a prevalence of 1.43:1000 live births. Other studies have shown that the frequency is approximately 1 in 600/700 live births and correction involves prolonged treatment over many years [1, 2].

A variety of surgical techniques and modifications have been described regarding cleft lip and palate (CLP) treatment [2]. However, patients still seem to have concerns about their facial appearance, especially related to the cleft deformity. The self-perceived improvement in facial appearance following treatment had a strong positive influence on quality of life and patient satisfaction compared to other functional or treatment-related factors [1–3].

The multifactorial threshold model is one of the well-established models for describing the etiology of CL/P, in which statements, the malformations result from factors such as genetic predisposition and exogenous factors like maternal malnutrition, low intake of folic acid, teratogens including drugs and alcohol, viruses, and maternal age [1].

Other studies considered seasonal influence [1] and they considered that it was reasonable to expect the orofacial clefts may show seasonal variations due to indirect factors such as: maternal malnutrition and low intake of folic acid, and

other direct factors such as temperature, intensity of ultraviolet light exposure, use of fertilizers and pesticides in agriculture, and infectious disease cycles.

Depending on the cleft type and severity, as well as treatment outcome, important functions like eating, speech, appearance, and maxillary growth may be impaired. This can affect patients social-emotional functioning and self-esteem resulting in a lower health-related quality of life [3].

The professional's opinion is influenced by training and experience and they may influence patients and parents' perception of the need for treatment. Professionals could also be considered as part of the community with distinct characteristics deriving from their medical background [3–7].

## **2. Epidemiological profile in Brazilian and Latin-American community in cleft/lip palate**

In Brazil [1] and part of Latin-American community, epidemiological studies demonstrated that incidence of CL/P episodes varies from 0.19 to 1.4/1000 births. Approximately 65–70% of cleft lip with or without cleft palate (CLP) and 40–70% of cleft palate only (CP) were isolated defects and the remaining related to syndromic clefts.

A systematic review discussing the issue have also demonstrated that its incidence varies according to gender, 2:1 being the ratio of males to females for cleft lip and palate and 1:2 the approximate ratio of male to female for isolated CP, as well as unilateral clefts are more common than bilateral clefts, and of the unilateral cases of non-syndromic cleft lip and palate, left-sided cleft lips occur more frequently than right-sided cleft lips [8].

## **3. Cleft lip/palate classification**

The anatomical, physiological, and pathological understanding of cleft lip/palate is basis for team surgery such as oral and maxillofacial surgeon, plastic surgeon, dentists, and clinicians for enhancing a better clinical approach. Accurate and correct diagnosis is translated through these fundamentals. Thus, patients with cleft lip-palate require a thorough knowledge of all the complexity that affects them.

Whether from the classification system based on anatomical-clinical or embryological issues to the therapeutic models.

Therefore, in this part of the chapter we will discuss the most commonly used classifications in these patients.

### **3.1 Clefts lip/palate**

Regarding treatment of patients with cleft lip/palate (CL/P), Spina [9] modified one of the worldwide used classification in 1973 in order to make a classification easier to understand, simpler to teach, more manageable to memorize, and more applicable to interdisciplinary and international communication.

He had modified previous classification, referred to an anatomical structure placed in the hard palate, the incisive foramen. Accordingly, Spina renamed group 1 as pre-foraminal clefts, group 2 as trans-foraminal, and group 3 as post-foraminal clefts.

These units are further subdivided into unilateral, bilateral, complete, and incomplete, as visualized in **Table 1**.

Silva-Filho [11] adding a sub-classification in the clefts trans-foraminal, named as median type, which is not present in the Spina classification, describes another classification.

Group I	Pre-foraminal	Unilateral Bilateral	Total Partial
Group II	Trans-foraminal	Unilateral Bilateral	
Group III	Post-foraminal	Total Partial	
Group IV	Facial clefts		

*Adapted from: Ref. [10].*

**Table 1.**  
*Cleft and lip/palate classification by Spina [10].*

## 4. Cheiloplasty or plastic lip surgery

The basic statement of lip cleft correction surgery is to approach the edges of the non-tensioned wound. To achieve this result, different techniques are then used from local flaps for the closure of the labial cleft.

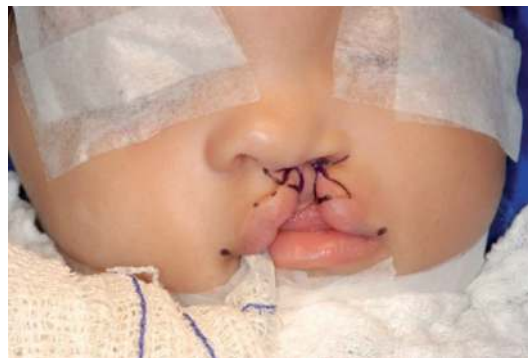The cheiloplasty is ideally recommended to be performed at 3 months of age. There is no need to perform interventions prior to this age, because it has already proven in the literature that will not bring superior esthetic gains and; therefore, due to cicatricial fibrosis, in future in other secondary surgeries, the tissue will be a more difficult for manipulation with less tissue remaining for posterior any necessary esthetic procedure.

Thus, primary cheiloplasty is restricted to only one definitive procedure at 3 months of age, without any previous intervention to “facilitate” the closure of the fissure, shown in **Figure 1**.

### 4.1 Unilateral cheiloplasty

The clefts can be presented in different ways. For this reason, the surgical planning must be individualized for each patient. As above described, surgery for the lip cleft, whether unilateral or bilateral, should be performed as of the 10th week of life and referred to rule of 10 (hemoglobin 10 mg/dl, 10 weeks of life, and 10 pounds—corresponds to around 4.5–5 kg) [12–14].

The purpose of this surgery is to relocate the surrounded labial tissues: skin, orbicularis muscle of the lip and mucosa. Indeed, for removing the hypoplastic tissue from the margin of the cleft (specifically, could be or not performed, and it will



**Figure 1.**  
*Patient with unilateral left lip cleft who will submitted to Millard technique. Author: Case report from Oral and Maxillofacial Department of “Defeitos da Face” Medical Center, Sao Paulo, Brazil.*

depend how huge the cleft is shown and the addressed tissue will be found). Several techniques are described in the literature for the closure of unilateral lip cleft.

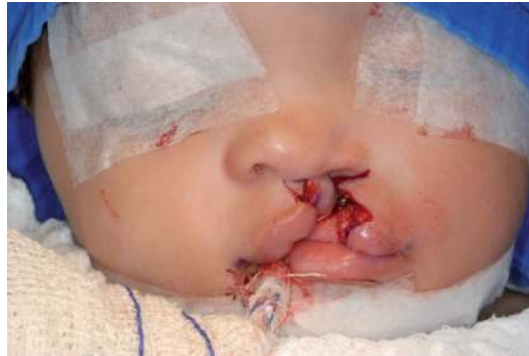One of the most common used techniques currently is Millard's (seen in **Figure 1**). This technique has the great advantage of allowing that when the tissue advances are performed, they are positioned in the natural contours of the lip and nose (**Figures 1–3**).

#### 4.2 Palatoplasty of plastic palate surgery

The primary surgical correction of the hard and/or soft palate cleft known, as palatoplasty is the surgical procedure for the anatomical, functional and esthetic reconstruction of this structure. Usually, the cleft palate is submitted to surgical treatment between 9 and 12 months of born. Nowadays, the main challenge is to achieve an intervention that minimizes speech changes, without compromising maxillofacial growth [15, 16].

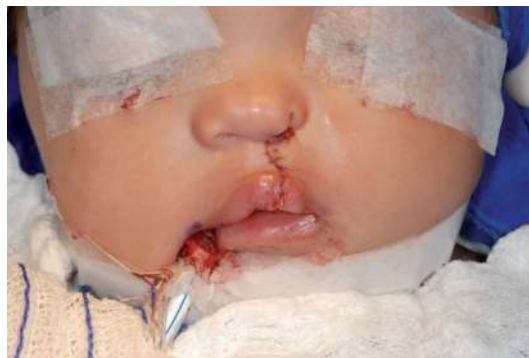In the current literature, there is still no consensus as which would be the best and accurate technique for correction of the cleft palate. There are a number of techniques of palatoplasty, in which surgeons choose their approach according to their established precepts and experiences.

The choice of the most appropriate technique is an important factor for the clinical success in order to correct this born malformation. Therefore, the surgeon should know which one presents more benefits with lower complications as much as possible [17].



**Figure 2.**

*Free-tension flaps for lip cleft correction. Author: Case report from Oral and Maxillofacial Department of “Defeitos da Face” Medical Center, Sao Paulo, Brazil.*



**Figure 3.**

*Primary closure of the labial cleft, in which the reorientation of the Cupid's bow is prioritized to create a harmonic lip. Author: Case report from Oral and Maxillofacial Department of “Defeitos da Face” Medical Center, Sao Paulo, Brazil.*

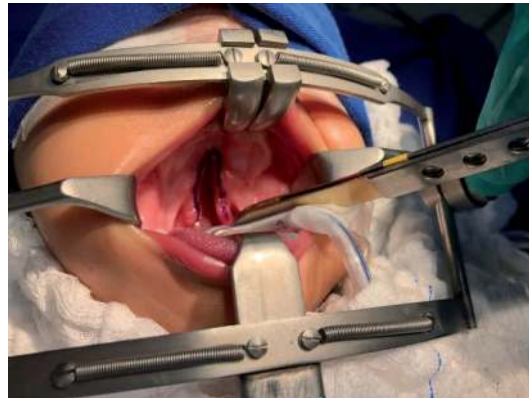#### 4.2.1 Von Langenbeck technical surgery approach

The Von Lagenbeck technique (in **Figures 4** and **5**), described in 1861, is the oldest and used currently. It is usually indicated in the correction of incomplete clefts in order to modify and correct the hard palate. This technique consists of the closure of the palate, from mucoperiosteal flaps, approximated from wide lateral relaxing incisions.

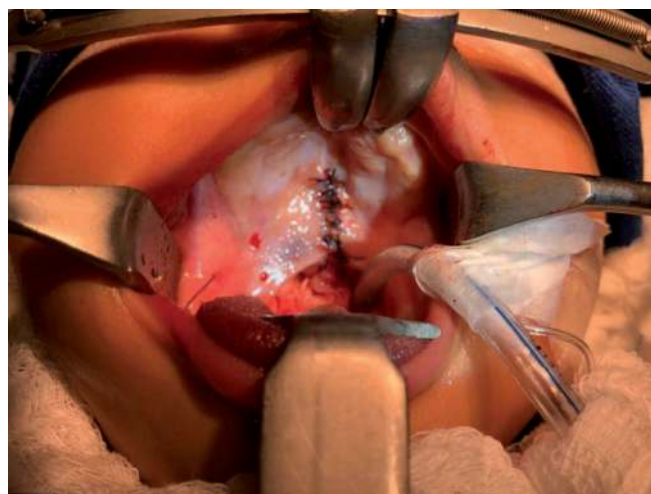
One of the limitations of this technique is the possible occurrence of velopharyngeal insufficiency, consequent to the absence of palatal elongation. Relaxation incisions provide less tension in the tissues and thus lower incidence of oronasal fistulas [18] (**Figures 4** and **5**).

#### 4.3 Reconstruction of the alveolar cleft

The alveolar clefts are not treated along with the primary surgeries for correction of the labial and palatal clefts. This is due to the numerous studies published that in the patients who underwent grafts called “primary” grafts in the first years of life, there was a restriction of the transverse growth of the upper maxilla than in



**Figure 4.**  
*Post-foraminal complete cleft palate. Author: Case report from Oral and Maxillofacial Department of “Defeitos da Face” Medical Center, Sao Paulo, Brazil.*



**Figure 5.**  
*Primary closure of palate cleft by Von Langenbeck technique surgical approach. Author: Case report from Oral and Maxillofacial Department of “Defeitos da Face” Medical Center, Sao Paulo, Brazil.*

the group that was performed in 1 s surgical time, resulting in another long-term surgery to correct this new bone deformity [19–21]. Thus, alveolar reconstruction surgeries remain for another surgical time, where they will be discussed individually.

The advantages of bone grafts in the alveolar clefts are numerous:

1. The existing fistula can be closed between the nasal and oral medium;
2. Possibility of canine eruption in a normal positioning;
3. To help in order to prevent relapse and atresia of the maxillary arch;
4. A bone base is created for the nasal and labial structure, helping to restore not only functionality, but the esthetics of these structures (thus, restorative nasal surgeries should be performed only after alveolar graft surgery).

#### 4.3.1 Phases for the alveolar graft

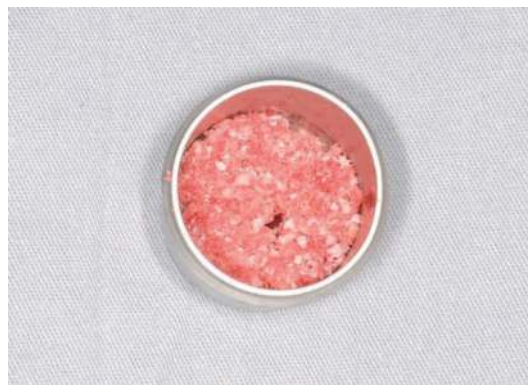The alveolar graft is usually performed according to the position of the permanent canine, central incisor, i.e., the permanent incisor tooth must be erupted, and the canine remained in the maxilla or mandibular arch.

The ideal age patient is between 8 and 12 years, as reported in the study by Boyne and Sands [21] (but this age might just be altered due to the eruption position of the canine, referred to chronological age versus dental age).

If a maxillary atresia with a necessity for bone grafting evidenced in alveolar cleft, the maxillary expansion should be performed previously. Moreover, it will facilitate the approach to the alveolar fissure in the graft procedure (**Figure 6**). Not least, once the bone graft has been placed, the expansion will have been become more difficult. Therefore, it would be recommended to perform grafting earlier, even in adult patients.

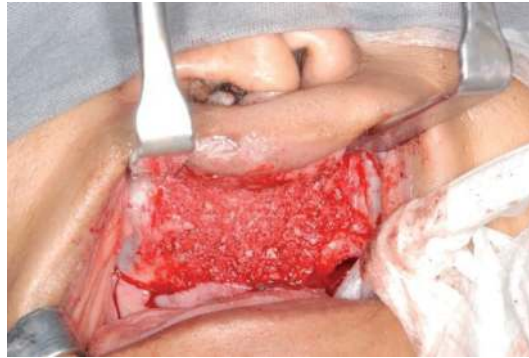#### 4.3.2 Surgical technique approach

A mucoperiosteal incision should be performed extending from the ipsilateral side of the alveolar cleft addressed from the height position of three posterior teeth referred to the cleft and up to two teeth later to the midline face.



**Figure 6.**

Particulate autology graft associated with particulate allogeneic (bovine) graft, which is considered the best option for reconstruction of large alveolar fissures. Author: Case report from Oral and Maxillofacial Department of “Defeitos da Face” Medical Center, Sao Paulo, Brazil.



**Figure 7.**  
*Adapted particulate graft throughout the cleft region. Author: Case report from Oral and Maxillofacial Department of “Defeitos da Face” Medical Center, Sao Paulo, Brazil.*

The aim of this surgical approach, besides the bone graft, is to obtain throughout primary close of all the tissues layers (buccal, nasal, and palatal mucosa) (Figure 7).

If this could not occur, the graft might be exposed to the oral cavity and infected. If there will have not been performed an adequate closure of nasal mucosa, it will be possible to create a nasal communication and discharge may occur with as consequence of infection in bone graft.

The management of soft tissue is of great importance in this type of surgical procedure, as well as in the other surgical approaches such as cheiloplasty and palatoplasty.

## **5. Complications of surgical procedures**

The procedures involving the surgical corrections of the lip-palate clefts are extremely delicate surgeries to perform as previously described; however, many corrections are often necessary to achieve desirable results for our patients mainly.

Since primary surgeries, multiple complications may occur from surgical techniques, thus increasing the number of procedures that these patients undergone throughout their lives.

The purpose of next paragraphs will be to discuss the complications of each procedure in the patient with cleft lip and palate.

### **5.1 Cheiloplasty or plastic surgery lip**

Cheiloplasty aims at the correction of the cleft lip. And several techniques are described in the literature for correction (Fisher, Millard, Tennyson-Cronin, among others). However, according to the degree of difficulty of the cleft lip, hypertrophic scars may result as complication of surgery approach, as well as tissue dehiscence and asymmetry between the Cupid's bow treated (cleft) lip and the healthy side.

### **5.2 Palatoplasty or plastic palate surgery**

Palatoplasty has a residual complication such as fistulae on hard and/or soft palate, otitis media, velopharyngeal insufficiency and alteration in maxillofacial growth.

### **5.3 Secondary/late graft**

The grafts are highly exposed to tissue dehiscence in the vestibular region of the alveolar mucosa as well as in the palatal region.

If the primary closure of the three tissue layers would have not been happened during the surgical procedure, it could augmented risk of oronasal communication. A major one resorption than expected might be observed.  
Not least, a secretion in the FO region may occur, and may compromise surgery.

## **Author details**

Henrique Cabrini Moreira<sup>1</sup> and Wilber Bernaola-Paredes<sup>2\*</sup>


1 Department of Oral and Maxillofacial Surgery, at Hospital dos Defeitos da Face, São Paulo, Brazil

2 Department of Oral Diagnosis, Oral Medicine and Stomatology at A.C. Camargo Cancer Center, São Paulo, Brazil

\*Address all correspondence to: ebernaola@usp.br

## **IntechOpen**

---

© 2020 The Author(s). Licensee IntechOpen. This chapter is distributed under the terms of the Creative Commons Attribution License (<http://creativecommons.org/licenses/by/3.0>), which permits unrestricted use, distribution, and reproduction in any medium, provided the original work is properly cited. 



## References

- [1] Aquino SN et al. A review of seasonality of cleft births—The Brazil experience. *Journal of Oral Biology and Craniofacial Research*. 2017;7(1):2-6
- [2] Gkatindis N, Papamanou DA, Christou P, Topouzellis N. Aesthetic outcome of cleft lip and palate treatment. Perceptions of patients, families, and health professionals compared to the general public. *Journal of Cranio-Maxillo-Facial Surgery*. 2013:e105-e110
- [3] Naros A, Brocks A, Kluba S, Reinert S, Krimmel M. Health-related quality of life in cleft lip and/or palate patients—A cross-sectional study from preschool age until adolescence. *Journal of Cranio-Maxillo-Facial Surgery*. 2018;46(10):1758-1763
- [4] Klassen AFR, Tsangaris E, Forrest CR, Wong KWY, Pusic AL, Cano SJ, et al. Quality of life of children treated for cleft lip and/or palate: A systemic review. *Journal of Plastic, Reconstructive & Aesthetic Surgery*. 2012;65:547-557
- [5] Sharama VP, Bella H, Cadier MM, Pigott RW, Goodacre TEE, Richard BM. Outcomes in facial aesthetics in cleft lip and palate surgery: A systemic review. *Journal of Plastic, Reconstructive & Aesthetic Surgery*. 2012;65:1233-1245
- [6] Munz SM, Edwards SP, Inglehart MR. Oral health-related quality of life, and satisfaction with treatment and treatment outcomes of adolescents/young adults with cleft lip/palate: An exploration. *International Journal of Oral and Maxillofacial Surgery*. 2011;40:790-796
- [7] Hunt O, Burden D, Hepper P, Johnston C. The psychosocial effects of cleft lip and palate: A systematic review. *European Journal of Orthodontics*. 2005;27:274-285
- [8] Popoff DAV, Coelho MP, Martelli DRB, Saini R, Coletta RD. Non-syndromic oral clefts and risk of cancer: A systematic review. *Dentistry*. 2013;3000(1):1-7
- [9] Spina V, Psillakis JM, Lapa FS, Ferreira MC. Classificação das fissuras lábio-palatinas: sugestão de modificação. *Revista do Hospital das Clínicas da Faculdade de Medicina da Universidade de São Paulo*. 1972;27(1):5-6
- [10] Spina V. A proposed modification for the classification of cleft lip and palate. *The Cleft Palate Journal*. 1973;5(2):251-252
- [11] Silva-Filho OG, Ferrari-Júior FM, Rocha DL, Souza-Freitas JA. Classificação das fissuras lábio-palatais: breve histórico, considerações clínicas e sugestão de modificação. *Revista Brasileira de Cirurgia*. 1992;82(2):59-65
- [12] Millard DR. *Cleft Craft*. Vol. 1. Boston (MA): Little Brown; 1976. pp. 165-173
- [13] Millard DR. A primary camouflage of the unilateral harelip. In: *Transactions of the International Congress of Plastic Surgeons*. Baltimore (MD): Williams & Wilkins; 1957. pp. 160-166
- [14] La Rossa D. The state of the art in cleft palate surgery. *The Cleft Palate-Craniofacial Journal*. 2000;37(3):225-228
- [15] Habel A, Sell D, Mars M. Management of cleft lip and palate. *Archives of Disease in Childhood*. 1996;74:360-366
- [16] Agrawal K. Cleft palate repair and variations. *Indian Journal of Plastic Surgery*. 2009;42(Suppl):102-109

[17] Furlow LT Jr. Cleft palate repair by double opposing z-plasty. *Plastic and Reconstructive Surgery*. 1986;**78**(6):724-738

[18] Eppley B. Alveolar cleft bone grafting (part I): Primary bone grafting. *Journal of Oral and Maxillofacial Surgery*. 1996;**54**:74-82

[19] Rosenstein SW. Early bone grafting of alveolar cleft deformities. *Journal of Oral and Maxillofacial Surgery*. 2003;**61**:1078-1081

[20] Brattstrom V, McWilliam J. The influence of bone grafting age on dental abnormalities and alveolar bone height in patients with unilateral cleft lip and palate. *European Journal of Orthodontics*. 1989;**11**:351-358

[21] Boyne PJ, Sands NR. Combined orthodontics-surgical management of residual palate-alveolar cleft defects. *American Journal of Orthodontics*. 1976;**70**:20-377