

# Pre-Operative Ultrasound-Guided Supra-Inguinal Fascia Iliaca Catheters Associated With Reduced Delirium After Neck Of Femur Fractures

D. Buckley<sup>1</sup>, B. Goodman<sup>1</sup>, J. Womack<sup>1</sup>, A. Qureshi<sup>1</sup>, N. Stephens<sup>1</sup>

<sup>1</sup>Department of Anaesthesia, Royal Victoria Infirmary, Newcastle upon Tyne, UK

## Background

Patients with a fractured neck of femur are often elderly, frail and with multiple co-morbidities, and the fracture itself may be a pre-terminal event.

Regional anaesthesia is an attractive option in these patients. A previous systematic review suggested that regional anaesthesia may reduce both peri-operative delirium and length of stay when compared to opiate-based analgesia<sup>1</sup>.

At our institution, an ultrasound-guided supra-inguinal fascia iliaca catheter (FIC) is inserted in patients who present with a fractured neck of femur (NOF), as soon as possible after diagnosis. The supra-inguinal approach is used to encourage the cephalad spread which is required to reliably block both the femoral and lateral femoral cutaneous nerves, and facilitates easy catheter placement<sup>2</sup>. If expertise is unavailable, a single shot fascia iliaca block (SSB) is performed instead.

Previous studies have demonstrated reduced rates of delirium with SSB<sup>3</sup>. This evaluation compares delirium incidence in these groups with patients who had no block (NB) pre-operatively.

## Methods

After institutional approval, retrospective data for continuous cases in the National Hip Fracture Database were cross-referenced with our local pain database. Delirium screening used the 4AT tool and categorised patients as having no cognitive impairment, suspected cognitive impairment or suspected delirium. Data were analysed using SPSS.

## Results

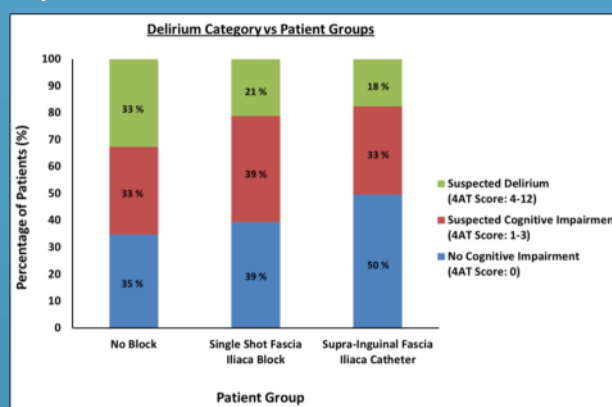
From January 2017 to March 2018, 428 patients presented with a fractured NOF, of whom 408 had complete data regarding pre-operative blocks. Of these, 166 had a FIC inserted, 137 had a SSB and 106 had NB.

The FIC group had the highest rate of no cognitive impairment (50%) and the lowest rate of suspected delirium (18%).

The NB group had the lowest rate of no cognitive impairment (33%) and the highest rate of suspected delirium (33%).

The SSB group had a rate of no cognitive impairment and suspected delirium in between these two groups (39% and 21%, respectively). See graph 1 for collated results.

Graph 1: Rates of Delirium



However, patients in the FIC group were younger (80.5; 82.6; 83.9 years) and had lower ASA scores (ASA 1 and 2 proportion 35%; 25%; 19%) compared to the SSB and NB groups.

Accounting for age, ASA and pre-operative cognitive function, logistic regression demonstrated that FIC was independently associated with reduced delirium (Odds ratio 0.39, 95% CI 0.16-0.93,  $p=0.034$ ).

## Conclusions

Treatment with a pre-operative fascia iliaca catheter is independently associated with reduced delirium in this retrospective sample. Catheters appear to be more protective than single shot blocks. Further prospective research is warranted to confirm these findings.

## Acknowledgements

Many thanks to the acute pain team at the Royal Victoria Infirmary who assessed the patients, entered the data onto the acute pain and hip fracture databases and who managed the fascia iliaca catheters.

## References

1. Rashed S, Vandermeer B, Abou-Setta AM, Beupre LA, Jones CA, Dryden DM. Efficacy of supplemental peripheral nerve blockade for hip fracture surgery: multiple treatment comparison. *Canadian Journal of Anesthesia/Journal canadien d'anesthésie* 2013; 60(3):230-43.
2. Hebbard P, Ivanusic J, Sha S. Ultrasound-guided supra-inguinal fascia iliaca block: a cadaveric evaluation of a novel approach. *Anaesthesia* 2011; 66(4):300-5.
3. Odor PM, Ster IC, Wilkinson I, Sage F. Effect of admission fascia iliaca compartment blocks on post-operative abbreviated mental test scores in elderly fractured neck of femur patients: a retrospective cohort study. *BMC Anesthesiology* 2017; 17(2).